

Aberrant Cystic Artery Causing Pseudo-Bilobed Gall Bladder: An Unknown Entity

S Mittal, P Garg, S Verma, A Narang, S Aggarwal, J Singh, K Kaushik, V Singh Rathee, H Ranga

Citation

S Mittal, P Garg, S Verma, A Narang, S Aggarwal, J Singh, K Kaushik, V Singh Rathee, H Ranga. *Aberrant Cystic Artery Causing Pseudo-Bilobed Gall Bladder: An Unknown Entity*. The Internet Journal of Gastroenterology. 2013 Volume 13 Number 1.

Abstract

The cystic artery can have variable origin, the right cystic artery being the most common. In addition, its course can also follow diverse paths often in close proximity to the common bile duct. This report presents a course of the cystic artery encountered during open cholecystectomy that has not been reported previously in the literature. The cystic artery was unusually long and crossing across the middle of the gall bladder giving it a pseudobilobed appearance. This rare variant is reported to enhance knowledge on spectrum of cystic artery anomalies

INTRODUCTION

The topographic anatomy of the hepatobiliary arterial system and their anomalous origins and courses should be kept in mind during hepatobiliary surgeries such as laparoscopic or open cholecystectomy. Prior knowledge of any rare anomaly is essential for reducing the incidence of intraoperative complications. The cystic artery is known to exhibit variations in its origin, course and branching pattern. The normal cystic artery arises from the right hepatic artery in the Calot's triangle in the cystohepatic angle immediately to the right of common hepatic duct. After it has passed behind common hepatic duct and anterior to the cystic duct it reaches the superior aspect of the neck of gallbladder to divide into superficial and deep branches.^{1,2} Some times there can be more than one cystic artery supplying the gallbladder. And rarely it may also arise from other arteries like left hepatic artery, accessory right hepatic artery, superior mesenteric artery, hepatic artery proper, gastroduodenal artery, retroduodenal and superior pancreaticoduodenal arteries.^{3,4} A long cystic artery coursing across middle of gall bladder is not described in literature.

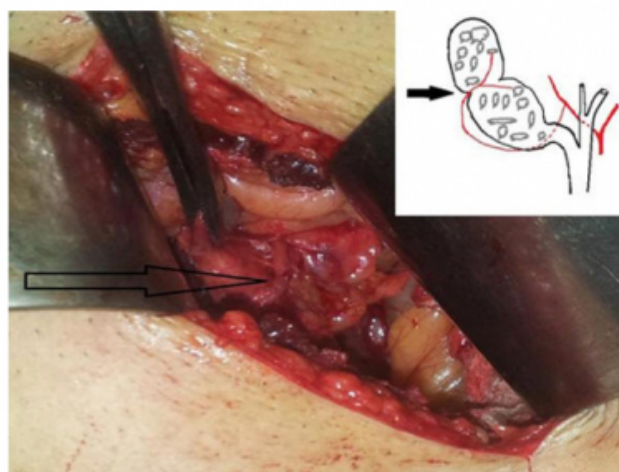
CASE REPORT

A 50 year old male was admitted with diagnosis of cholelithiasis. During open surgery a bilobed gall bladder was found. Further meticulous dissection revealed that appearance of two lobes was actually due to a long cystic

artery, running across the middle of the gall bladder and causing narrowing of body of the gall bladder (Figure 1). Both the lobes were packed with mixed stones. Cystic artery and duct were ligated and cut, while removing the gall bladder from the liver bed, a small accessory duct was encountered which was ligated. The patient had an eventless postoperative recovery

Figure 1

Intraoperative picture showing cystic artery (arrow). Inset shows artistic view of anatomical course of the cystic artery



DISCUSSION

Anatomic variations in and around Calot's triangle are frequent involving biliary tree and cystic artery and we found them in 20%-50% of patients.^{5,6} Therefore, careful blunt dissection of Calot's triangle is necessary for both open and laparoscopic cholecystectomy. The cystic artery presents an unusually high degree of variability not only in its origin or number but also in its course to gallbladder. It is of utmost surgical importance as it is always ligated during cholecystectomy irrespective of its origin & course. In the present case the cystic artery was originating from right hepatic artery but having a long curved course, running across middle of gall bladder causing a sort of narrowing of body of gall bladder giving rise to false appearance of bilobed gall bladder and constricting it. The course across body of gall bladder causing narrowing was possibly responsible for prolonged stasis of bile leading to formation of gall stones. The active pathology may be considered akin to aberrant vessel causing hydronephrosis in kidney.

CONCLUSION

Aberrant course of cystic artery across the body of the gall bladder can be considered akin to what is seen in hydronephrosis due to aberrant vessel. This very well explains prolonged stasis of bile as a pathogenetic factor for stone formation.

References

1. Sinnatamby CS, ed. Last's anatomy. Regional and applied, 10th ed. London, Churchill Livingstone, 1999:258–60.
2. Bannister LH et al., eds. Gray's anatomy, 38th ed. London, Churchill Livingstone, 1995:1551–2. .
3. Chen TH, Shyu JF, Chen CH, et al. Variations of the cystic artery in Chinese adults. Surg Laparosc Endosc Percutan Tech 2000; 10:154-7.
4. Hollinshead WH. Anatomy for Surgeon. 2nd ed. New York: Harper and Row, 1971
5. Cimmino PT, Bocchetti T, Izzo L. Anatomico-surgical considerations in laparoscopic cholecystectomy. G Chir 1992; 13: 149-151
6. Larobina M, Nottle PD. Extrahepatic biliary anatomy at laparoscopic cholecystectomy: is aberrant anatomy important? ANZ J Surg 2005; 75: 392-395

Author Information

Sachin Mittal, Dr, M.S

Department of Surgery, Pt. B. D. Sharma Post Graduate Institute of Medical Sciences
Rohtak, Haryana, India
sachinmvn@yahoo.co.in

Pradeep Garg, Dr, M.S, D.N.B

Department of Surgery, Pt. B. D. Sharma Post Graduate Institute of Medical Sciences
Rohtak, Haryana, India

Surender Verma, Dr, M.S

Department of Surgery, Pt. B. D. Sharma Post Graduate Institute of Medical Sciences
Rohtak, Haryana, India

Amit Narang, Dr, M.B.B.S

Department of Surgery, Pt. B. D. Sharma Post Graduate Institute of Medical Sciences
Rohtak, Haryana, India

Sourabh Aggarwal, Dr, M.B.B.S

Department of Surgery, Pt. B. D. Sharma Post Graduate Institute of Medical Sciences
Rohtak, Haryana, India

Jaspreet Singh, Dr, M.B.B.S

Department of Surgery, Pt. B. D. Sharma Post Graduate Institute of Medical Sciences
Rohtak, Haryana, India

Kaviraj Kaushik, Dr, M.B.B.S

Department of Surgery, Pt. B. D. Sharma Post Graduate Institute of Medical Sciences
Rohtak, Haryana, India

Vazir Singh Rathee, Dr, M.S

Department of Surgery, Pt. B. D. Sharma Post Graduate Institute of Medical Sciences
Rohtak, Haryana, India

Hansraj Ranga, Dr, M.S

Department of Surgery, Pt. B. D. Sharma Post Graduate Institute of Medical Sciences
Rohtak, Haryana, India