

An Unusual Case of Retinal Vasculitis and Neuroretinitis with Chronic Glomerulonephritis in Sytemic Lupus Erythematosus with Hughes Syndrome

R Juneja, P Sune, M Kamble, P Subramanian, S Dulani, M Sune, P Tidake, S Acharya, S Mahajan, G Mundada, G Sandhu, P Kalakoti, H Nasti, S Anjankar, S Bhansali, N Kanhere, Z Quazi

Citation

R Juneja, P Sune, M Kamble, P Subramanian, S Dulani, M Sune, P Tidake, S Acharya, S Mahajan, G Mundada, G Sandhu, P Kalakoti, H Nasti, S Anjankar, S Bhansali, N Kanhere, Z Quazi. *An Unusual Case of Retinal Vasculitis and Neuroretinitis with Chronic Glomerulonephritis in Sytemic Lupus Erythematosus with Hughes Syndrome*. The Internet Journal of Ophthalmology and Visual Science. 2012 Volume 9 Number 1.

Abstract

Retinal vasculitis is an intra-ocular inflammatory condition with diverse etiology and a rare manifestation of systemic lupus erythematosus, often associated with antiphospholipid antibodies.^[1] The detection and characterization of Retinal Vasculitis and Neuroretinitis may help in diagnosis and management of certain disorders associated with ocular inflammation. These include systemic autoimmune disorders, few infectious diseases and certain ocular disorders. We report a very unusual case of SLE associated with Hughes Syndrome in a 20 year old normotensive female who presented with retinal vasculitis, neuroretinitis and systemic involvement in the form chronic glomerulonephritis.

INTRODUCTION

Systemic Lupus Erythematosus is an autoimmune disease that affects multiple organ systems including the eye and is associated with polyclonal B-cell activation and production of autoantibodies.^[2]

Retinal vascular lesions are the most common ophthalmological manifestation of systemic lupus erythematosus (SLE), accounting for 3% to 29% of the cases, generally late in the disease. More rare is the severe vaso-occlusive disease, often termed retinal vasculitis.^[3,4] Retinal Vasculitis is characterized by inflammation of the vessels of the retina.^[5] SLE accounts only 4% as the cause of Retinal Vasculitis. Retinal Vasculitis as a primary manifestation of SLE is uncommon. Optic Neuropathy is also rare in SLE, with a prevalence of 1%.^[6] Patients with SLE and raised serum concentration of anticardiolipin antibodies have a higher risk of developing occlusive ocular vascular disease.^[1,4] Ocular involvement in SLE is an indicator of active systemic disease, most importantly nephropathy and cerebral lupus.^[7] The causes of ocular manifestations in SLE generally include active lupus,

antiphospholipid antibody syndrome (APS, Hughes Syndrome), and drugs used to treat SLE.^[8]

CASE REPORT

A 20 year old normotensive female presented with fever and headache since 20 days, blurring of vision in both eyes since 14 days, swelling over lower limbs and face since 10 days and oliguria since 7 days. There was no history of haematuria, pain in abdomen, distention of abdomen, chest pain, dyspnea, haemoptysis, arthralgia, and sore throat. There was no history of seizures. Her menstrual history and past history was insignificant.

On clinical examination her blood pressure was 130/90 mm of Hg, tachycardia was present 116 beats/min, pallor was present, there was no glossitis or koilonychia. JVP was normal. Bilateral edema of feet (pitting type), puffiness of face, malar rash sparing nasolabial folds, oral ulcers and arthritis was present.

On investigations, haemoglobin was 9.1gm%. TLC was 8400/mm³. Platelet count was low -1,28,000/microliter of blood. Urine analysis revealed. Urine examination revealed

An Unusual Case of Retinal Vasculitis and Neuroretinitis with Chronic Glomerulonephritis in Sytemic Lupus Erythematosus with Hughes Syndrome

proteinuria (+++), albuminuria(+), few RBCs (2-3) per high power field, 24 hour urinary protein was 2.7gm/dl, serum urea was 56mg% and serum creatinine was 1.9mg%. HIVI and HIVII by ELISA was negative. Serum ASO titre was negative. Serum ANA was 4.08(>1 is positive) and dsDNA 58.42(>20 is positive). USG abdomen and pelvis revealed shrunken kidney. IgG ACA was 45GPL u (>40 GPL u) done on 1st week and 9th week.

She was referred to Ophthalmolgy department for complaints of blurring of vision, headache and slight diminution of vision OU. On examination her visual acuity was 6/18 OU. Anterior segments were unremarkable. Fundus examination revealed hyperemic disc, multiple retinal haemorrhages OU and macular star OS representing retinal vasculitis and neuroretinitis OU. There were no signs of hypertensive retinopathy changes in fundus picture OU. Our case was fulfilling the criteria for diagnosis of SLE by the American Rheumatologic Association. She was started on intravenous methyl-prednisolone 1gm daily for 3 days followed by oral prednisolone 1mg/kg/day in tapering dose with diuretics and ACE inhibitor therapy. After 15 days, her edema subsided, proteinuria reduced(24 hour urinary protein was 1.7gms), urine output increased and vision improved to 6/9 OU. Serum creatinine after 2 weeks decreased to 0.67mg%. The patient was discharged with 40mg prednisolone and was advised for follow-up after 2 weeks.

Figure 1

Fig. 1: Fundus pic showing Retinal Vasculitis

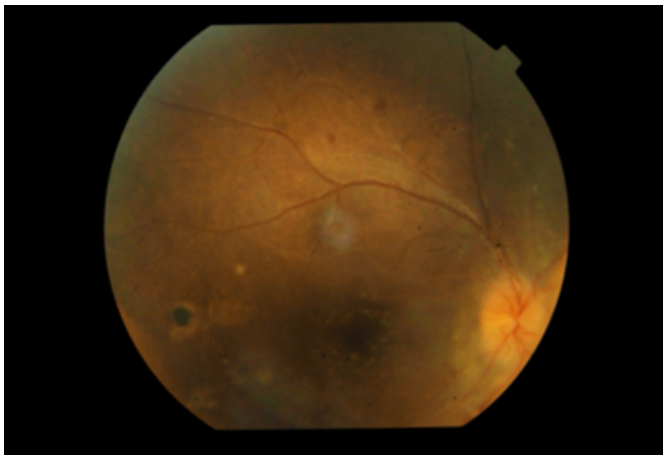

Figure 2

Fig 2: Fundus Pic Showing Neuroretinitis

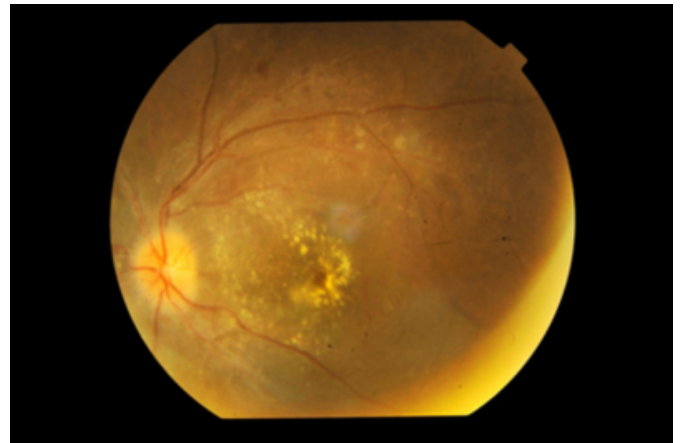


Figure 3

Fig 3: CT Brain showing Lacunar Infarct in Basal Ganglia suggestive of SVD.

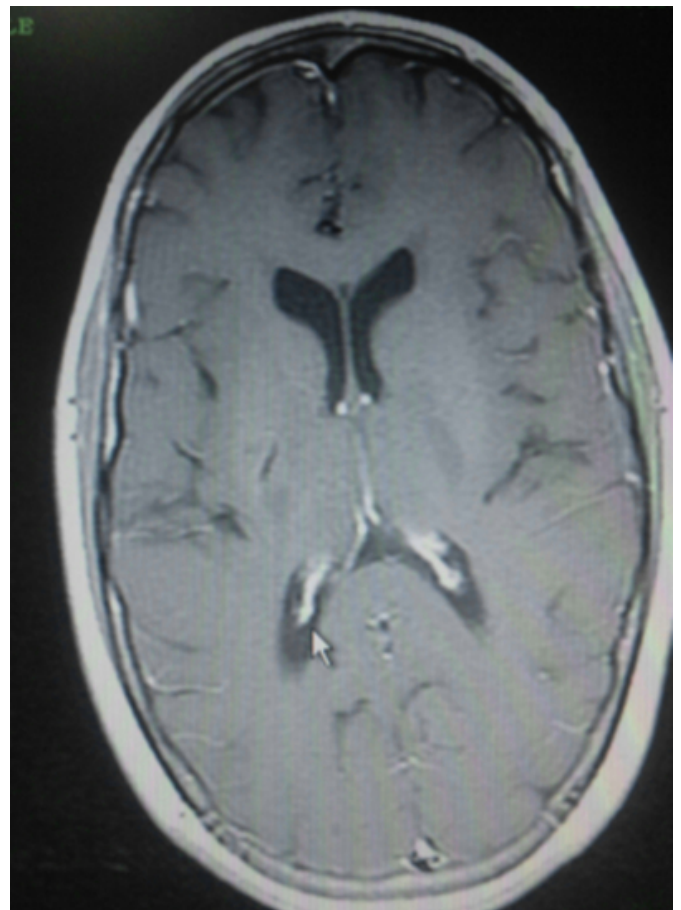
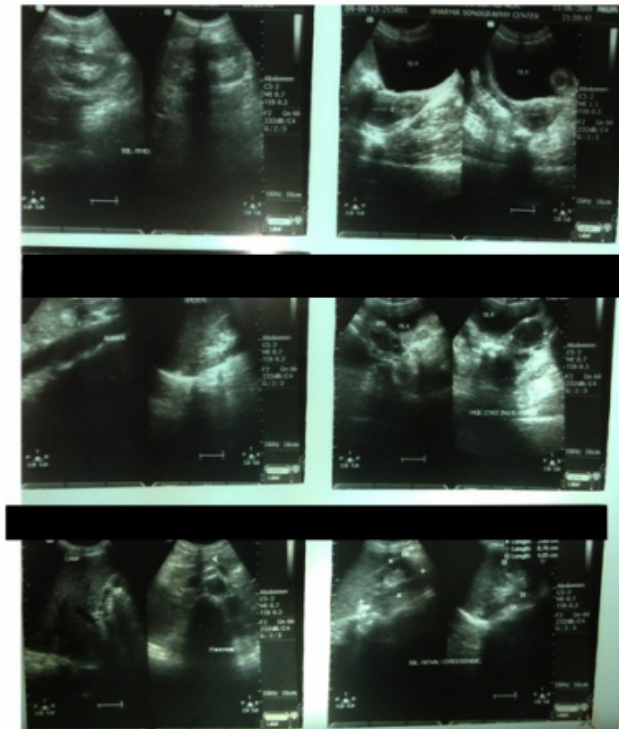


Figure 4

Fig 4: USG abdomen showing shrunken kidney secondary to Chronic Glomerulonephritis



DISCUSSION

Retinopathy is one of the important, if not major, manifestation of SLE, which develops with an incidence of 7-26%,^[16] reflecting a reduction in frequency associated with improved control of systemic disease. Mild retinopathy may be asymptomatic but more severe disease may cause loss of vision, field defects distortion and floaters. Such visual symptoms are therefore an indication for urgent ophthalmic review. The retinal signs often parallel the severity of systemic inflammation, and may indicate inadequate control of systemic disease.^[9,20] The presence of APA is associated with more severe retinopathy and vascular occlusions.^[21]

Mild lupus retinopathy consists of cotton-wool spots, perivascular hard exudates, retinal haemorrhages and vascular toxicity.^[22] Moderately severe cases may also have focal or generalized arteriolar constriction and venous tortuosity. At the severe end of spectrum there is occlusion of retinal arterioles and consequent retinal infarction, termed vaso-occlusive retinopathy or 'retinal vasculitis'^[23,24] Proliferative retinopathy may occur in upto 72% of such cases, often ensuing vitreous haemorrhage, retinal traction

and retinal detachment. Other retinal presentations include large vessel occlusions (central and branch retinal vein occlusions, central and branch retinal arteriole occlusions) that are common in the presence of antiphospholipid syndrome (APA), pigmentary changes(pseudo retinitis pigmentosa) and exudative retinal detachment secondary to choroidal disease. In the immunosuppressed state, rare retinal infections may occur: retinal necrosis due to herpes simplex, varicella zoster and cytomegalovirus are all reported. Optic neuritis, ischemic optic neuropathy are also commonly seen.

It is unfortunate that ophthalmological manifestations are not included in the diagnostic criteria of SLE. It is not uncommon to see patients who have not been diagnosed as SLE, who have developed an ocular manifestation in advance of diagnosis of SLE. Though severe visual loss is not seen in the group whose retinopathy improves with corticosteroid/immunosuppressive therapy.^[3] In this patient, nephropathy was also present. SLE represents the most frequent cause of renal involvement. The choriocapillaris-Bruch membrane retinal pigment epithelium complex is morphologically similar to glomerular basement membrane (GBM); they are structurally homologous, selectively permeable with positive charge. Both have high content of heparan sulphate, the only difference being the collagenous zone of Bruch membrane which is thicker than the GBM.^[10]

The renal presentation is highly variable. The serum dsDNA levels consistently correlate with disease severity, histopathology, clinical course and response to therapy.^[11]

The findings of retinopathy as vasculitis and thromboembolism reflect vascular damage. Ocular fundus is the only part of human body where we can directly observe small vessels without injuring the tissue. This suggests that lupus retinopathy reflects systemic vascular damage and that ocular fundus examination should be carried out more often. Although it is unclear whether lupus retinopathy is directly associated with renal disease, retinopathy may develop in severe SLE which involves the kidney or CNS, or both.^[17]

aPL are known to be associated with arterial and venous thrombosis.^[18,19] aPL represent a heterogeneous group of antibodies against phospholipid binding proteins or their complexes with anionic phospholipids.^[12] As the presence of aPL often provokes arterial and venous thrombosis, intrauterine fetal loss, and thrombocytopenia,^[13] many organs may be affected by these antibodies.^[14,15] An

association of aPL with lupus retinopathy has been found. This indicates that aPL should be added to the list of candidates causing retinopathy.^[17]

The mainstay of treatment for significant retinal disease is systemic immunosuppression, but laser therapy and anticoagulant also have a role. Initial treatment is usually with oral corticosteroids (e.g. prednisolone 1mg/kg/day), but may be preceded by methyl prednisolone (e.g. 500mg-1gm daily for 3 days). This is then supplemented with, or replaced by, other immunosuppressive agents as a part of steroid sparing strategy or for resistant disease. In unilateral or asymptomatic disease, regional corticosteroid injections are sometimes used in addition. In the presence of significant vaso-occlusive disease (particularly when APA are present), anti-coagulation and addition of low dose acetylsalicylic acid may be beneficial.

CONCLUSION

SLE is a multisystem immune disorder. Eye manifestations in SLE may be sight-threatening and can be an indicator of active systemic disease. Significant ocular pain or diminution of vision are serious symptoms requiring urgent assessment by an ophthalmologist. The serious ocular manifestations of SLE (such as scleritis and lupus retinopathy) generally require systemic immunosuppression. Renal involvement can occur at any time during the course of disease. It can be silent. Though renal biopsy is not necessary in SLE patients whose renal function is rapidly deteriorating when they have active urinary sediment, it becomes necessary in atypical presentations not defining a pure nephritic or nephrotic syndrome and/or rising serum creatinine levels, so that early diagnosis will lead to prompt initiation of management.

Future research will hopefully provide more evidence on which to base treatment choice. Early recognition by the rheumatologist, prompt assessment by the ophthalmologist and coordinated treatment strategies are key to reducing the ocular morbidity associated with the disease.

ACKNOWLEDGEMENT

We thank our Prochancellor Dr. Ved Prakash Mishra, Director Research Projects, Dr. Zahirudin Quazi, The Institutional Ethics Committee of Acharya Vinoba Bhave Rural Hospital, Sawangi (M), Wardha, India, for their kind permission to publish the case report.

References

1. Bandhopadhyay SK, Moulick A, Dutta A. Retinal Vasculitis- an initial presentation of systemic lupus erythematosus. *J Indian Med Assoc.* 2006 Sep; 104(9):526-7
2. Russell W. Read, MD; Lawrence P. Chong, MD; Narsing A. Rao, MD. Occlusive Retinal Vasculitis Associated With Systemic Lupus Erythematosus. *Arch Ophthalmol.* 2000; 118(4):588-589.
3. Koch JW, al Nawaiseh, Koch FH. Severe occlusive bilateral retinal vasculitis within the scope of seronegative systemic lupus erythematosus. *Klin Monatsbl Augenheilkd* 1992;201(5):330-6
4. Ermakova NA, Alekberova ZS, Reshetnlak TN. Characteristics of retinal vascular involvement in systemic lupus erythematosus. *Vestn Ophthalmol* 2001; 117(2): 21-4.
5. Stanford M, Graham E, Systemic associations of retinal vasculitis. *Int Ophthalmol Clin* 1991;31:23
6. Barkeh HJ, Muhaya M. Optic Neuritis and retinal vasculitis as primary manifestations of systemic lupus erythematosus. *Med J Malaysia.* 2002 Dec;57(4):490-2
7. Jabs DA, Fine SL, Hochberg MC, Newmans SA. Severe retinal vaso-occlusive disease in systemic lupus erythematosus. *Arch Ophthalmol* 1986; 104(4):558-63
8. Wallace DJ, Hahn BH Anaya J-M, Talal N (1997) Head and neck findings in SLE: Sjogren's syndrome and the eye, ear, and larynx in Dubois' lupus erythematosus. eds Wallace DJ, Hahn BH (Williams and Wikins, Baltimore(, 5th ed. Pp 783-791.
9. Gold DH, Morris DA, Henkind P. Ocular findings in systemic lupus erythematosus. *Br J Ophthalmol* 1972;56:800-4
10. Duvall-Young J, Short CD, Raines MF et al. Fundus changes in mesangio-capillary glomerulonephritis type II: Clinical and fluorescein angiographic findings. *Br J Ophthalmol* 1987;73:297-302
11. Foster MH. Relevance of Systemic lupus erythematosus nephritis animal model to human disease. *Semin Nephrol* 1999;19:12-24
12. Harris EN, Exner T, Hughes GRV Harris En(1991) The antiphospholipid syndrome-an introduction. in Phospholipid-binding antibodies. eds Harris EN, Exner T, Hughes GRV (CRC Press, Boca Raton, FL). Pp 373-386.
13. Atsumi T, Khamashta MA, Haworth RS, Brooks G, Amengual O, Ichikawa K et al. (1998) Arterial disease and thrombosis in the antiphospholipid syndrome. *Arthritis Rheum* 41:800-807
14. Amigo M-C, Gracia-Torres R, Robles M, Boichicchio T, Reyes PA (1992) Renal involvement in primary antiphospholipid antibody syndrome. *J Rheumatol* 19:1181-1185.
15. Alarcon- Segovia D, Deleze M, Oria CV, Sanchez-Guerrero J, Gomez-Pacheco L, Cabiedes J et al (1989) Antiphospholipid antibodies and the antiphospholipid syndrome in systemic lupus erythematosus. A prospective analysis of 500 consecutive patients. *Medicine (Baltimore)* 68:353-365.
16. Ropes MW(1976) Systemic lupus erythematosus (Harvard University Press, Cambridge, MA)
17. Osamu Ushiyama, Keiko Ushiyama, Suyichi Korada, Yoshifumi Tada, Noriaki Suzuki, Akihito Ohta, Shinji Oono, Kohei Nagasawa. Retinal disease in patients with systemic lupus erythematosus. *Ann Rheum Dis* 2000;59:705-708
18. Kelly WN, Harris ED, Ruddy S, Sledge CB Asherson RA, Cervera R (1997) Antiphospholipid syndrome in textbook of Rheumatology. eds Kelly WN, Harris ED,

Ruddy S, Sledge CB(Saunders, Philadelphia), 5th ed. Pp 1057-1064.

19. Harris EN, Gharavi AE, Boey M, Mackworth-Young CG, Loizou S, Hughes GRV(1983) Anticardiolipin antibodies : detection by radioimmunoassay and association with thrombosis in systemic lupus erythematosus. Lancet ii:1121-1214

20. Aravalo IE, Lowder CV, Muci-Mandoza B. Ocular manifestations in systemic lupus erythematosus. Curr Opin Ophthalmol 2002;13:404-10

21. Durrani OM, Gordon C, Murray PI Primary antiphospholipid antibody syndrome(APS): current concepts. Surv Ophthalmol 2002;47:215-38

22. Conneto I, Lessel S. Retinopathy in systemic lupus erythematosus. Arch Ophthalmol 1977;95:794-7

23. Iahs DA, Fine SL, Hochberg MC, Newman SA, Heiner CG, Stevens MB, Severe retinal vaso-occlusive disease in systemic lupus erythematosus. Arch Ophthalmol 1986; 104:558-63

24. Hall S, Buttner H, Luthra HS. Occlusive retinal vascular disease in systemic lupus erythematosus. J Rheumatol 1984;11:846-50

25. Giorai D, Pace E, Giorai A, Bonama I, Gabrieli CB. Retinopathy in systemic lupus erythematosus: pathogenesis and approach to therapy. Hum Immunol 1999;60:688-96.

Author Information

Rakesh Juneja

Department of Ophthalmolgy, Acharya Vinoba Bhave Rural Hospital

Pradeep Sune

Department of Ophthalmolgy, Acharya Vinoba Bhave Rural Hospital

Mala Kamble

Department of Ophthalmolgy, Acharya Vinoba Bhave Rural Hospital

Prem Subramanian

Neuro-ophthalmology Division, The Wilmer Eye Institute, Johns Hopkins University School of Medicine

Somya Dulani

Department of Ophthalmolgy, Acharya Vinoba Bhave Rural Hospital

Mona Sune

Department of Ophthalmolgy, Acharya Vinoba Bhave Rural Hospital

Praveen Tidake

Department of Ophthalmolgy, Acharya Vinoba Bhave Rural Hospital

Sourya Acharya

Department of Medicine, Acharya Vinoba Bhave Rural Hospital

Satish Mahajan

Department of Medicine, Acharya Vinoba Bhave Rural Hospital

Gaurav Mundada

Department of Orthopaedics, Acharya Vinoba Bhave Rural Hospital

Gurpreet Sandhu

Department of Radiology, Acharya Vinoba Bhave Rural Hospital

Piyush Kalakoti

Rural Medical College, Pravara Institute of Medical Sciences

Hammad Nasti

Department of Ophthalmolgy, Acharya Vinoba Bhave Rural Hospital

Sandeep Anjankar

Department of Ophthalmolgy, Acharya Vinoba Bhave Rural Hospital

Snehil Bhansali

Department of Ophthalmolgy, Acharya Vinoba Bhave Rural Hospital

Neha Deshpande Kanhere

Department of Ophthalmolgy, Acharya Vinoba Bhave Rural Hospital

Zahiruddin Sayeed Quazi

Department of Community Medicine, Acharya Vinoba Bhave Rural Hospital