

Rare Squamous Cell Carcinoma In A Psoriatic Patient – Management Challenge!

S Aggarwal, P Garg, . Bhorawal, A Narang, S Verma, S Mittal, V Singh Rathee, N Verma, S Yadav

Citation

S Aggarwal, P Garg, . Bhorawal, A Narang, S Verma, S Mittal, V Singh Rathee, N Verma, S Yadav. *Rare Squamous Cell Carcinoma In A Psoriatic Patient – Management Challenge!*. The Internet Journal of Dermatology. 2013 Volume 11 Number 1.

Abstract

Squamous cell carcinoma (SCC) of the scrotum, first described by Pott in chimney sweepers in 1775 as occupational cancer, is rare in presentation in our days. Herein, we report a case of squamous cell carcinoma of the penoscrotal region in a psoriasis patient which is rarest as such. However SCC of other sites are known in psoriatic patients following PUVA therapy. Wide excision is the treatment of choice and prognosis depends upon lymph nodes involvement.

INTRODUCTION

Squamous cell carcinoma (SCC) of the scrotum is the first cancer reported in association with occupational hazards. Pott pioneered in describing this cancer in chimney sweepers in 1775 and thus also labeled as Pott's cancer or chimney sweep cancer.^{1,5} The incidence of this carcinoma has decreased due to improved environmental conditions and occupational awareness.^{2,3} SCC is also described in patients with psoriasis who are undergoing PUVA therapy, however, it occurs in an area of the skin exposed to sun light⁴ but it has not been described in the scrotal region. SCC of the scrotum has also been reported with scars of Fournier's gangrene and scars of infertility procedure. Scrotal squamous cell carcinoma in psoriatic patients is rare.

CASE SUMMARY

A 61 year old male, nonsmoker and nonalcoholic, a known case of psoriasis and psoriatic arthritis for the last 30 year (under irregular treatment), shop-keeper by occupation came to us with a gradually progressive irregular and firm ulceroproliferative growth of size 3 x 4 cm near the penoscrotal junction for last 1 year. The swelling was associated with foul, watery discharge initially but no discharge at present. General physical examination was normal except psoriatic patches all over the body with psoriatic arthritis of the hands. Margins of the growth were rolled out and everted with indurated base (figure1). Bilateral inguinal

lymphadenopathy was also present with no focal infective focus in the perineal region or lower limbs. His routine investigations were within normal limit and wedge biopsy from margins showed the lesion to be a squamous cell carcinoma. Wide excision with 2 cm margins was done (figure 2,3) and histo-pathology revealed positive margins. As bilateral lymph nodes were involved along with positive margins, the patient is planned for radiotherapy. Presently the patient is undergoing radiotherapy.

Figure 1

Preoperative figure showing penoscrotal ulcer

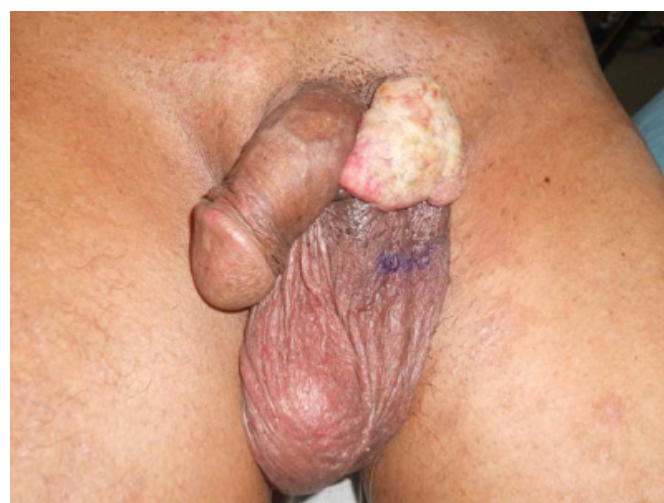

Figure 2

Intra operative figure after removal of growth with margin

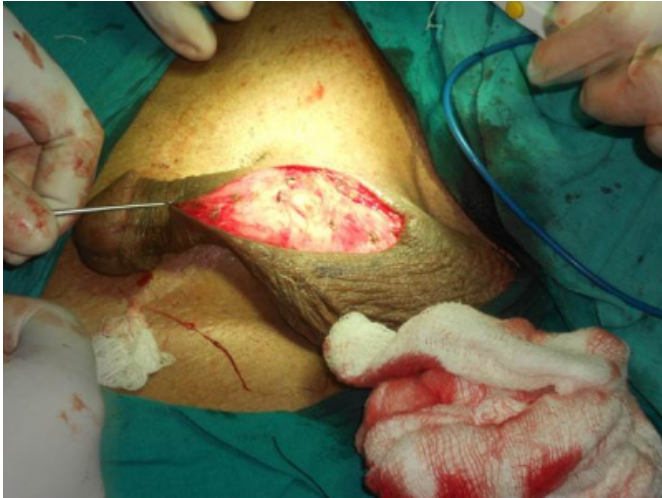
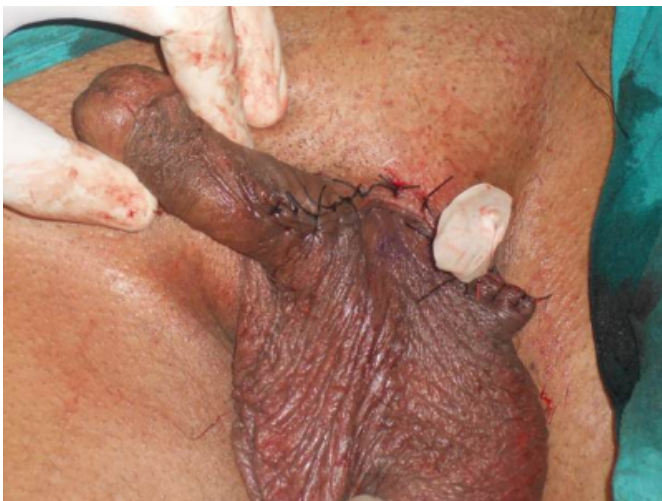

Figure 3

Final figure following repair of wound with glove drain in situ



DISCUSSION

Squamous cell carcinoma is the most common malignant tumor of the scrotum; however, rare cases of basal cell carcinoma, melanoma, Paget's disease and sarcoma have been reported.⁵

Squamous cell carcinoma of the scrotum is the first cancer associated with occupational hazards. First described by Pott in chimney sweepers in 1775 and thus also labeled as Pott's cancer or chimney sweep cancer.^{1,5} The etiology of the disease was unclear from the time of Pott until 1922, when Passey gave experimental evidence of the presence of weak

carcinogens in soot, as the theory of chronic irritation popular at the time did not fully answer all the questions raised.⁵ Till today exposure to certain carcinogens in specific occupations such as tar workers, petroleum wax pressmen, paraffin and shale oil workers, cotton mule operators and the screw making industry have been identified as various risk factor as occupation hazards in this cancer.² However, the incidence of this carcinoma is decreasing due to improved environmental condition, better hygiene, better clothing and occupational awareness.^{2,3} Squamous cell carcinoma is also described in patients with psoriasis who are under PUVA therapy, however it occur in area of the skin exposed to sun light⁴ but it has not been described in the scrotal region (usually not exposed to sun). This has also been explained with healed Fournier's scar^{6,7} and scars of infertility procedure⁸. In view of above discussion scrotal squamous cell carcinoma in a psoriatic patient is a rarest entity. We could hardly find any such case reported in literature.

Surgery with a negative resection margin offers the best hope of cure as adjunctive therapy has not proved useful. Prognosis correlates with the extent of nodal involvement. In our case nodal involvement was there and even after wide excision the margins were positive, all were suggestive of regional spread and of poor prognosis, surgery alone was not sufficient so patient was referred to radiotherapy department for further treatment.

References

1. Melicow MM. Percival Pott (1713–1788): 200th anniversary of first report of occupation- induced cancer of scrotum in chimney sweepers (1775). *Urology* 1975; 6: 745.
2. Andrews PE, Farrow GM, Oesterling JE. Squamous cell carcinoma of the scrotum: long-term follow up of 14 patients. *J Urol* 1991; 146:1299–304.
3. Lowe FC. Squamous cell carcinoma of the scrotum. *J Urol* 1983; 130: 423–7.
4. McKenna KE, Patterson CC, Handley J, McGinn S, Allen G. Cutaneous neoplasia following PUVA therapy for psoriasis. *Br J dermatol* 1996; 134: 639-42.
5. Waldron H.A. A brief history of Scrotal Cancer. *British Journal of Industrial Medicine* 1983;40:390-401.
6. Schneider PR, Russell RC, Zoo EG. Fournier gangrene of the penis: areport of two cases. *Ann Plast Surg* 1986; 17: 87–90.
7. Chintamani, Shankar M, Singhal V, Singh JP, Bansal A, Saxena S. Squamous cell carcinoma developing in the scar of Fournier gangrene– case report. *BMC Cancer* 2004; 4: 16
8. Kotwal S, Madaan S, Prescott S, Chilka S, Whelan P. Unusual squamous cell carcinoma of the scrotum arising from a well healed, innocuous scar of an infertility procedure: a case report. *Ann R Coll Surg Engl.* 2007 ;89:W17-9.

Author Information

Sourabh Aggarwal, Dr, M.B.B.S

Department of Surgery, Pt. B. D. Sharma Post Graduate Institute of Medical Sciences
Rohtak, Haryana, India

Pradeep Garg, Dr, M.S, D.N.B

Department of Surgery, Pt. B. D. Sharma Post Graduate Institute of Medical Sciences
Rohtak, Haryana, India
drpradeepgarg@rediffmail.com

. Sandeep Bhorwal, Dr, M.S

Department of Surgery, Pt. B. D. Sharma Post Graduate Institute of Medical Sciences
Rohtak, Haryana, India

Amit Narang, Dr, M.B.B.S

Department of Surgery, Pt. B. D. Sharma Post Graduate Institute of Medical Sciences
Rohtak, Haryana, India

Surender Verma, Dr, M.S

Department of Surgery, Pt. B. D. Sharma Post Graduate Institute of Medical Sciences
Rohtak, Haryana, India

Sachin Mittal, Dr, M.B.B.S, M.S

Department of Surgery, Pt. B. D. Sharma Post Graduate Institute of Medical Sciences
Rohtak, Haryana, India

Vazir Singh Rathee, Dr, M.S

Department of Surgery, Pt. B. D. Sharma Post Graduate Institute of Medical Sciences
Rohtak, Haryana, India

Naveen Verma, Dr, M.B.B.S

Department of Surgery, Pt. B. D. Sharma Post Graduate Institute of Medical Sciences
Rohtak, Haryana, India

Sunil Yadav, Dr, M.B.B.S

Department of Surgery, Pt. B. D. Sharma Post Graduate Institute of Medical Sciences
Rohtak, Haryana, India