

# A Rare Case Of Mucinous Carcinoma Of The Breast

C Nilay, I Shalaka, K H., A Agarwal

## Citation

C Nilay, I Shalaka, K H., A Agarwal. *A Rare Case Of Mucinous Carcinoma Of The Breast*. The Internet Journal of Surgery. 2012 Volume 28 Number 4.

## Abstract

Mucinous carcinoma of the breast is a relatively rare malignancy, the pure form accounting for 2% of all breast cancers. Pure mucinous carcinoma of the breast has a favorable prognosis and is usually seen in postmenopausal women. Here, we report a 60-year-old female patient with a hard breast lump, diagnosed on cytology as mucinous carcinoma of the breast, which was subsequently confirmed on histopathology following definitive surgery, but without lymph node metastasis.

## INTRODUCTION

Mucinous carcinoma (MC) of the breast is a distinctive, well differentiated type of adenocarcinoma, constituting 2%-5% of breast cancers.<sup>(1,2)</sup> Pure MC of breast has been reported to have a more favorable prognosis than other well differentiated adenocarcinomas of breast, with a lower frequency of axillary node metastasis and excellent short-term prognosis, especially when the tumor measures less than 5 cm in diameter. Fine-needle aspiration (FNA) has been described to yield copious amounts of mucinous material in mucinous carcinoma with a variable proportion of tumor cells. The tumor cells have been described as being generally small and fairly uniform with minimal atypia, and this may give a false impression of "benignancy", a term used to describe this uncommon condition.

The present report describes a 60-year-old female presenting with a right breast lump, diagnosed as mucinous carcinoma on FNAC, confirmed on histopathology.

## CASE REPORT

A 60-year-old female presented with a painless, gradually increasing, large hard lump in the upper inner quadrant of the right breast of 1 year duration. The mass measured 6 x 5 cm and was not fixed, either to the skin or underlying structures. The overlying skin was normal; however, the nipple was retracted. No axillary lymph node was palpable on that side. The opposite breast and axilla were normal. A clinical diagnosis of carcinoma of the right breast was made and a fine-needle aspiration of the mass was done apart from other routine hematological and biochemical investigations.

## PATHOLOGICAL FINDINGS

Fine-needle aspiration done from the right breast mass showed cellular smears against mucinous background revealing isolated and clusters of malignant duct cells having high N/C ratio, vesicular nuclei with prominent nucleoli and moderate amount of cytoplasm. The cytological findings were suggestive of mucus secreting carcinoma. Other routine investigations were within normal limits. Metastatic work-up revealed no evidence of metastasis. Ultrasonography of the abdomen and pelvis revealed incidental cholelithiasis with a common bile duct calculus of 1 cm (though there had been no evidence as yet of any biliary obstruction) for which the patient was subjected to ERCP with duct clearance and stenting.

Definitive surgical treatment was carried out in the form of a modified radical mastectomy on the right side which included an axillary lymph node clearance.

## HISTOPATHOLOGY

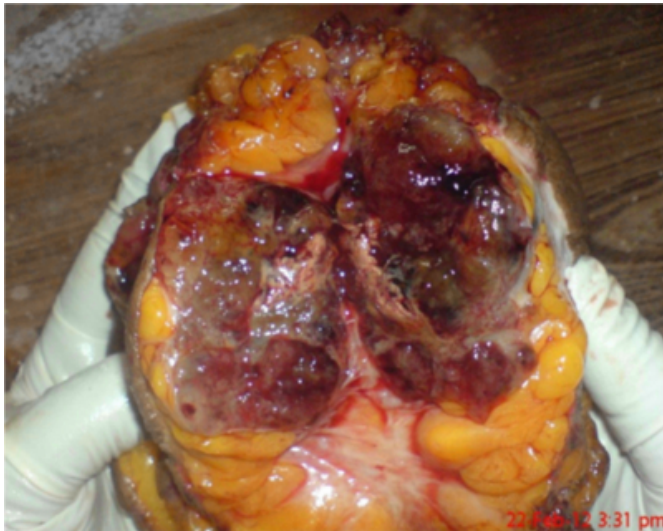
On gross examination, the specimen measured 21 x 14 x 3 cm with a skin flap measuring 13 x 6 cm. The nipple was retracted. The cut section showed a tumor mass measuring 6 x 6 cm, the closest margin being 5 mm from the skin. The base of the specimen did not show any tumor involvement. On cut section, the tumor was well circumscribed and showed mucoid material separated by delicate septae. [Fig.1] The specimen contained 10 lymph nodes, the largest being 1 x 0.5 cm.

Microscopy revealed an invasive mucinous breast cancer. The overlying skin, nipple and areola were uninvolved. The base was free of the tumor. There was no lymphatic,

vascular or perineural invasion. (Fig. 2) A few foci of low-grade in situ duct carcinoma were present in the vicinity of the tumor. However, the surgical margins were free of tumor. All the 10 axillary lymph nodes were negative for metastasis.

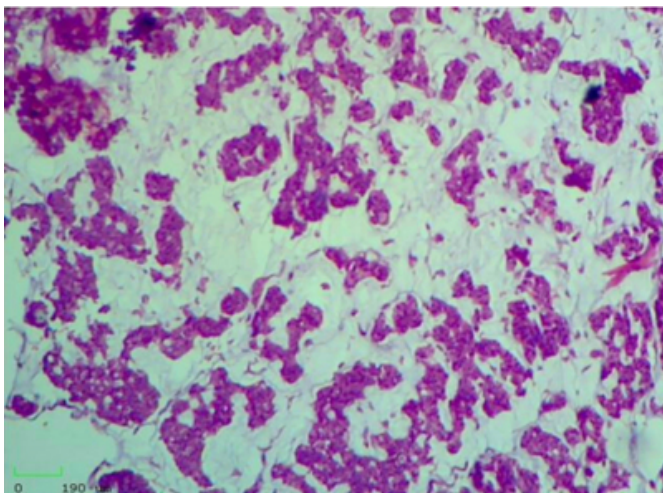
### Figure 1

Fig.1: Gross specimen



### Figure 2

Fig. 2: Microscopic view showing abundant mucin (H&E, x100)



## DISCUSSION

Mucinous carcinoma of the breast is a rare malignancy in postmenopausal females, accounting for only 2% of all breast carcinomas.<sup>(1,2)</sup> Mucinous carcinomas can be classified as pure and mixed forms. The pure form shows variable amount of extracellular mucin surrounding the tumor cells. Mucinous carcinoma with invasive areas not surrounded by mucin is considered as a mixed mucinous

carcinoma. The prognosis of pure mucinous carcinoma is much better than for mixed one. The pure mucinous carcinomas are further subdivided into cellular and hypocellular variants. The most common admixture is with regular invasive duct carcinoma. Two lesions most likely to be confused with mucinous carcinoma are mucoid fibroadenoma and a mucocele-like lesion.<sup>(4)</sup> Mucinous carcinoma is Estrogen Receptor (ER) positive, but in less than 70% cases, it is Progesterone Receptor (PR) positive.<sup>(5,6)</sup> However, in our case, it was both ER and PR POSITIVE. Only 3-15% of the pure variety show axillary node metastasis compared to 33-46% of the mixed type.<sup>(3,7)</sup> In the present case, however, NO axillary node was positive for tumor deposits.

Since these tumors have low incidence of axillary metastases, some authors advocate that axillary node staging maybe unnecessary in these patients.<sup>(11)</sup> Late distant metastases may occur in these patients.<sup>(2,8)</sup> Adjuvant chemotherapy consisting of cyclophosphamide, adriamycin and 5-fluorouracil (5-FU) is given at every 3 weeks interval for 6 cycles. Histochemically, the mucins secreted by this tumor are distinct O-acylated forms of sialomucin.<sup>(9)</sup> Immunohistochemically, there is strong MUC (mucin) 2 cytoplasmic immunoreactivity. One-fourth to nearly one-half shows features consistent with endocrine differentiation.<sup>(10)</sup> Our patient has been following up for the last three months, and so far her recovery has been uneventful.

Conclusion: Mucinous carcinoma of the breast is rare and has a favorable prognosis due to low incidence of axillary lymph node metastases. Axillary staging in this tumor seems a controversial issue.

## References

1. Scoopsi L, Andreola S, Pillotti S, Bufalino R, Baldini MT, Testori A, et al.: Mucinous carcinoma of the breast. A clinicopathologic, histochemical, and immunocytochemical study with special reference to neuroendocrine differentiation. *Am J Surg Pathol*; 1994; 18: 702-11.
2. Toikkanen S, Kujari H: Pure and mixed mucinous carcinomas of the breast: a clinicopathologic analysis of 61 cases with long-term follow-up. *Hum Pathol*; 1989; 20: 758-64.
3. Komaki K, Sakamoto G, Sugano H, Morimoto T, Monden Y: Mucinous carcinoma of the breast in Japan. A prognostic analysis based on morphologic features. *Cancer*; 1988; 61: 989-96.
4. Rosen PP: Mucocele-like tumors of the breast. *Am J Surg Pathol*; 1986; 10: 464-9.
5. Shousha S, Coady AT, Stamp T, James KR, Alaghband-Zadeh J: Oestrogen receptors in mucinous carcinoma of the breast: an immunohistological study using paraffin wax sections. *J Clin Pathol*; 1989; 42: 902-5.
6. Diab SG, Clark GM, Osborne CK, Libby A, Allred DC,

Elledge RM: Tumor characteristics and clinical outcome of tubular and mucinous breast carcinomas. *J Clin Oncol*; 1999; 17: 1442-8.

7. Anan K, Mitsuyama S, Tamae K, Nishihara K, Iwashita T, Abe Y, et al.: Pathological features of mucinous carcinoma of the breast are favorable for breast-conserving therapy. *Eur J Surg Oncol*; 2001; 27: 459-63.

8. Clayton F: Pure mucinous carcinomas of breast: morphologic features and prognostic correlates. *Hum Pathol*; 1986; 17: 34-8.

9. Saez C, Japon MA, Poveda MA, Segura DI: Mucinous

(colloid) adenocarcinomas secrete distinct O-acylated forms of sialomucins: a histochemical study of gastric, colorectal and breast adenocarcinomas. *Histopathology*; 2001; 39: 554-60.

10. Fisher ER, Palekar AS: Solid and mucinous varieties of so-called mammary carcinoid tumors. *Am J Clin Pathol*; 1979; 72: 909-16.

11. Paramo JC, Wilson C, Velarde D, Giraldo J, Poppiti RJ, Mesko TW: Pure mucinous carcinoma of the breast: is axillary staging necessary? *Ann Surg Oncol*; 2002; 9: 161-4.

**Author Information**

**Chakrabarti Nilay**

Dept. of Surgery, K.J. Somaiya Medical College and Hospital

**Indap Shalaka**

Dept. of Surgery, K.J. Somaiya Medical College and Hospital

**Kalpana H.**

Dept. of Pathology, K.J. Somaiya Medical College and Hospital

**Abhishek Agarwal**

Dept. of Surgery, K.J. Somaiya Medical College and Hospital