

Prophylactic Norepinephrine for Spinal Anesthesia in an Elderly Patient with Aortic Stenosis.

D Oh, H Kim

Citation

D Oh, H Kim. *Prophylactic Norepinephrine for Spinal Anesthesia in an Elderly Patient with Aortic Stenosis.* The Internet Journal of Anesthesiology. 2012 Volume 30 Number 4.

Abstract

A 76-year-old woman with a left femur neck fracture was admitted for urgent hip bipolar hemiarthroplasty. The patient was prescribed angiotensin-converting-enzyme inhibitor, beta blocker and clopidogrel daily for hypertension and angina. The preoperative echocardiogram showed left ventricular hypertrophy and a severely calcified and thickened aortic valve with stenosis. A single-shot spinal anesthesia was planned. After dural puncture, 9 mg of 0.5 % hyperbaric bupivacaine plus fentanyl 12.5 mcg were injected. At the same time, we started infusion of norepinephrine (50 ng/kg/min) to prevent expected perioperative hypotension. Invasive blood pressure declined during the initial 5 min after intrathecal injection, but recovered quickly. Vital signs were hemodynamically stable and the patient did not need any treatment for surgery. The norepinephrine infusion was safely tapered down over 15 min while skin incision was closed. We found that prophylactic short-term norepinephrine infusion can be safely used for expected hypotension induced by a single-shot spinal block in an elderly patient with aortic stenosis.

INTRODUCTION

Aortic stenosis (AS) is a independent risk factor for perioperative cardiac morbidity and mortality in patients undergoing non-cardiac surgery¹ and perioperative hypotension after neuraxial block is common clinical problem. In particularly, neuraxial block has been considered contraindicated in patients with severe AS because the sudden and potentially profound decrease in systemic vascular resistance may precipitate life-threatening compromise in coronary perfusion.²⁻⁴ But certain anesthetic techniques to minimize of the risk of systemic hypotension have been suggested, and successful use of carefully titrated epidural and continuous spinal blocks using catheters have been reported.⁵⁻⁷ Also vasoconstrictors to maintain the systemic vascular tone such as norepinephrine (NE), phenylephrine or metaraminol can be used to manage perioperative hypotension.⁸

NE is direct-acting sympathomimetic producing profound alpha-adrenergic receptor activity and is approved by the Food and Drug Administration to treat acute hypotensive states.⁹

We found that prophylactic intravenous NE infusion can be safely used to prevent expected hypotension induced by single-shot spinal block in an elderly patient with severe AS.

CASE REPORT

A 76-year-old woman with a left femur neck fracture was admitted for urgent hip bipolar hemiarthroplasty. The patient had a history of hypertension and stable angina. Her medications included angiotensin-converting-enzyme inhibitor, beta blocker and clopidogrel hydrogen sulfate daily.

On physical examination, the patient was 150 cm in height and weighted 36 kg. Heart rate (HR) and blood pressure were 62 bpm and 140/70 mmHg. Head and neck examination revealed a Mallampati class II airway.

In complete blood count, hemoglobin and hematocrit were 8.5 g/dl and 25.9 %. Mild elevated blood urea nitrogen and plasma creatinine level were 25 and 1.4 mg/dl. Other blood tests and chest radiograph were unremarkable. The electrocardiogram revealed left ventricular hypertrophy. Further preoperative evaluation by a physician and echocardiogram showed an ejection fraction of 55 %, left ventricular hypertrophy and a severely calcified and thickened aortic valve with stenosis and mild regurgitation, in addition to an aortic valve area 0.9 cm² with calculated pressure gradient of 39 mmHg across the valve. There was also mild mitral regurgitation with a well-functioning left ventricle. She reported only dyspnea on exertion and was not

diagnosed with aortic stenosis previously.

A single-shot spinal block was primarily planned as anesthetic management for surgery. The operation was planned for when clopidogrel was stopped for 7 days. Meanwhile, calcium channel blocker and beta blocker were prescribed.

Intravenous fentanyl 25 mcg was given 30 min prior to induction of anesthesia. Non-invasive automated blood pressure cuff, pulse oximetry and continuous electrocardiography monitoring were used. Invasive arterial blood pressure monitoring was established in the right radial artery and double lumen central catheter was placed via the right subclavian vein. Her initial vital signs were as follow: invasive blood pressure (IBP) 147/65 mmHg, HR 62 bpm, central venous pressure (CVP) 2 mmHg, oxygen saturation 97 % and respiratory rate 16 bpm. While carefully monitoring central venous and radial artery pressure, lactated Ringer's solution (350 ml) was given prior to initiation of spinal anesthesia for prehydration. We approached between the L3/4 levels using 25-G Quinke needle via paramedian approach in left lateral recumbent position. After dural puncture, 9 mg of 0.5 % hyperbaric bupivacaine (Bupivacaine Heavy, Myungmoon, Korea) plus fentanyl 12.5 mcg was injected slowly over 10 seconds. At the same time, we started 50 ng/kg/min infusion of NE (Norpin, Dalim Bio Tech, Korea) to prevent expected perioperative hypotension. NE was injected via central venous catheter by a microinfusion pump (JMS syringe pump SP-500, JMS Co., Japan). The patient was repositioned supine.

IBP declined during initial 5 min of spinal injection, but recovered quickly. We identified sensory blockade of T8 thoracic dermatome by the pinprick test and motor blockade of condition unable to move feet and knees by Bromage scale at ten minutes after intrathecal administration. The patient was positioned right lateral decubitus for surgery. NE was maintained at the same dose and the patient was hemodynamically stable and did not need any treatments for surgery. Sinus rhythm was maintained and there were no signs of myocardial depression, bradycardia and hypertensive events perioperatively.

The NE infusion was tapered down over 15 min while skin incision was closed. IBP showed the tendency of reduction, but restored again and remained stable until conclusion of operation. Table 1 and figure 1 display hemodynamic variables monitored throughout the operation. Estimated blood loss was approximately 500 mL and the patient

received packed red blood cells 1 unit, 300 ml of colloid and 500 ml of crystalloid solution intraoperatively. Urine output was about 100 ml for surgery. The patient transported to the recovery room awake, alert and comfortable. The level of sensory regression was S2 dermatome and the patient was able to perform a straight right leg lift. Postoperative pain was managed successfully with intravenous patient-controlled analgesia using fentanyl.

Figure 1

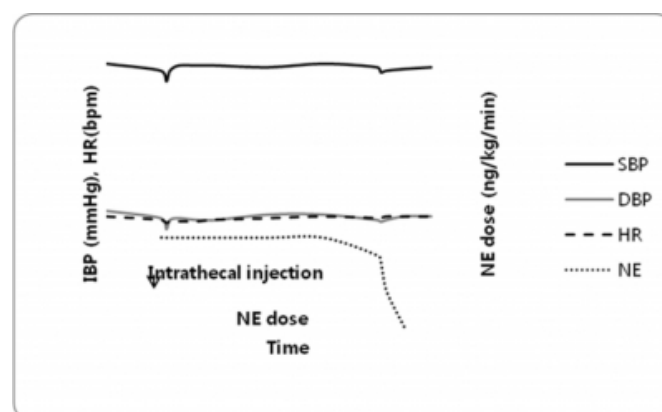
Table 1. Hemodynamic Variables for Patient.

Time	Event	IBP (mmHg)	HR (bpm)	CVP (mmHg)	SpO ₂ (%)
1:30	Preinduction	147/65	62	2	97
2:00	Bupivacaine + fentanyl, NE infusion	143/61	60	2	96
2:03		137/55	58	2	96
2:05		143/60	59	1	96
2:10		146/61	59	2	97
2:20		146/60	59	2	96
2:30	Skin incision	146/62	60	3	97
3:00		145/63	61	3	97
3:30		147/63	62	2	97
4:00	Skin suture, NE down-titration	145/60	61	2	97
4:02		142/59	61	2	97
4:05		143/60	62	2	97
4:15	Closing, NE discontinuation	144/62	62	2	97
4:30	PACU	145/62	62	2	96

NE, norepinephrine; IBP, invasive blood pressure; HR, heart rate; CVP, central venous pressure; SpO₂, oxygen saturation measured by pulse oximetry; PACU, postanesthesia care unit.

Figure 2

Figure 1. Vital signs and norepinephrine (NE) dose. Blood pressure and heart rate (HR) were maintained at stable levels. IBP, invasive blood pressure; SBP, systolic blood pressure; DBP, diastolic blood pressure.



DISCUSSION

Hip fractures are most often caused by a seemingly insignificant fall in the elderly¹⁰ and degenerative calcific AS

is a typical example of pathological cardiovascular aging process. Traditionally, many clinicians avoided using spinal anesthesia in patients with AS because the peripheral sympathetic blockade produced by regional anesthesia can rapidly cause a marked decrease in systemic vascular resistance.¹¹ However, several authors have experienced greater hemodynamic control achieved with continuous spinal and epidural block and intrathecal opioid addition over single-shot spinal block^{5-7, 12} and McDonald¹³ suggested stable patients with severe AS may do well with regional anesthetic or analgesic techniques.

Although continuous spinal and epidural block can reduce the disadvantages of single-shot spinal block, the techniques can be contraindicated relatively in patients taking anticoagulants. Based on the pharmacological aspects of clopidogrel, the safety interval for performing neuraxial block from most guidelines is recommended as 7 days after last dose of drug.¹⁴ But Litz¹⁵ and Tam¹⁶ have reported cases of spinal-epidural hematoma associated with neuraxial block and clopidogrel despite clopidogrel being stopped 7 days prior and suggested risk factors such as renal impairment, traumatic procedure and spinal abnormality. Among the types of procedures for neuraxial block the risk of spinal-epidural hematoma is highest for indwelling intrathecal and epidural catheters, followed by single-shot epidural anesthesia, and then single-shot spinal anesthesia.^{14, 17} So we planned single-shot spinal block to reduce risks of spinal-epidural hematoma in our patient in spite of expected profound hypotension induced by single-shot spinal block although we stopped clopidogrel for 7 days.

In patients aged >75 years with asymptomatic and severe AS, Calleja¹⁸ found that intraoperative hypotension was frequent and required prompt and aggressive treatment. Hypotension induced by single-shot spinal block should be avoided to prevent the vicious cycle of hypotension-induced ischemia, subsequent ventricular dysfunction and worsening hypotension in AS.¹¹ Consequently, vasopressors were required to treat intraoperative hypotension. Furthermore, because rapid decrease in blood pressure after single-shot spinal block tend to happen for first 20~30min particularly and the extent is reported to be about 20% in elderly patients,¹⁹ we considered a prophylactic use of vasopressors to minimize expected hypotensive changes.

NE is indicated for acute hypotension (drug reaction, septicemia, sympathectomy, myocardial infarction, and others) and has a very rapid onset of action documented to

be well within 1-2 min when given by intravenous⁹ and a continuous infusion is preferred because of its short half-life of 2.5 min.²⁰ It produces vasoconstriction by activation of α -adrenoreceptors but has also β -adrenergic properties. Although optimal dose of NE using spinal block was not became known, where less than 2 mcg/min (30 ng/kg/min) may uncover the effects of β_1 -adrenergic stimulation, the usual infusion rates of greater than 3 mcg/min (50 ng/kg/min) elicit peripheral vasoconstriction from α -adrenergic stimulation.²⁰ Physiologically, direct actions of β_1 -adrenergic stimulation of NE may increase HR, but HR is maintained an overall neutral state because of reflex bradycardia by β -adrenergic stimulation.⁹

In our case, local anesthetics were injected to subarachnoid space and NE (50 ng/kg/min) was infused at the same time. Fortunately, there was no significant hypotension for initial 30 min in spite of starting dose of NE and stable IBP and HR were maintained for surgery. HR was maintained at normal pre-anesthetic state in spite of additional decreasing effect in HR by sympathetic block. Because maintenance of sinus rhythm is desirable in AS, we think NE is preferable to phenylephrine for neuraxial block for patients with AS. Phenylephrine is a pure α -adrenergic agonist and may be used as a vasoconstrictor in regional block. However it reduces cardiac output due to reflex bradycardia.^{9, 21}

Adverse effects of NE were brady- or tachyarrhythmias, extreme hypertension, anxiety, transient headaches, nausea/vomiting and dyspnea,⁹ but there were no side effects in our case.

We prevented a single-shot spinal block induced hypotension by using a NE infusion the moment local anesthetics were injected to the subarachnoid space. Prophylactic NE infusion afforded stable vital signs without any side effects. Certainly, NE administration may cause ischemic injury, tissue hypoxia and renal hypoperfusion, especially with excessive doses.⁹ But the doses of NE required to treat hypotension secondary to spinal anesthesia were not high and do not reduce the increase in skin perfusion induced by spinal block²² and NE administered to raise blood pressure 20% does not affect urine flow or glomerular filtration.²³ Also short-term NE dose up-titration leading to arterial pressure rise was tolerated well by AS and do not cause clinical adverse effect.²⁴ Although further reports are required to confirm the usefulness, safety, infusion timing, optimal dose and dose-dependent effects of NE for prevention of hypotension induced by single-shot

spinal block in elderly patients with severe AS because of rarity of the disease, severity of stenosis, ventricular function, etc, we conclude that prophylactic short-term NE infusion can be safely used for expected hypotension induced by single-shot spinal block in an elderly patient with severe AS.

References

1. Detsky AS, Abrams HB, McLaughlin JR, et al. Predicting cardiac complications in patients undergoing non-cardiac surgery. *J Gen Intern Med.* 1986;1:211-9.
2. Stoelting RK, Dierdorf SF. Valvular heart disease. In: Stoelting RK, Dierdorf SF, editors. *Anesthesia and Co-Existing Disease*. 4th ed. New York: Churchill Livingstone; 2002. p. 28-40.
3. Horlocker TT. Concurrent medical problems and regional anesthesia and analgesia. In: Brown DL, editor. *Regional anesthesia and Analgesia*. 1st ed. Philadelphia: Saunders; 1996. p. 427-8.
4. Kleinman W, Mikhail MS. Spinal, epidural, caudal blocks. In: Morgan GE, Mikhail MS, Murray MJ, editors. *Clinical anesthesiology*. 4rd ed. McGraw-Hill Companies; 2006. p. 289-323.
5. Hamlyn EL, Douglass CA, Plaat F, Crowhurst JA, Stocks GM. Low-dose sequential combined spinal-epidural: an anaesthetic technique for caesarean section in patients with significant cardiac disease. *Int J Obstet Anesth.* 2005;14:335-61.
6. Pittard A, Vucevic M. Regional anaesthesia with a subarachnoid microcatheter for caesarean section in a parturient with aortic stenosis. *Anaesthesia* 1998;53:169-73.
7. VanHelder T, Smedstad KG. Combined spinal epidural anaesthesia in primigravida with valvular heart disease. *Can J Anaesth.* 1998;45:488-90.
8. Brown J, Morgan-Hughes NJ. Aortic stenosis and non-cardiac surgery. *Contin Edu Anaesth Crit Care Pain* 2005;5:1-4.
9. Ferguson-Myrthil N. Vasopressor use in adult patients. *Cardiol Rev* 2012;20:153-8.
10. Kim DW, Seo JY, Ahn ME, et al. A clinical review of geriatric patients with pelvic bone fractures. *J Korean Geriatr Soc* 2010;14:221-6.
11. Collard CD, Eappen S, Lynch EP, Concepcion M. Continuous spinal anesthesia with invasive hemodynamic monitoring for surgical repair of the hip in two patients with severe aortic stenosis. *Anesth Analg* 1995;81:195-8.
12. Eaton MP. Intrathecal sufentanil analgesia for extracorporeal shock wave lithotripsy in three patients with aortic stenosis. *Anesth Analg* 1998;86:943-4.
13. McDonald SB. Is neuroaxial blockade contraindicated in the patient with aortic stenosis? *Reg Anesth Pain Med* 2004;29:496-502.
14. Green L, Machin SJ. Managing anticoagulated patients during neuroaxial anaesthesia. *Br J Haematol* 2010;149:195-208.
15. Litz RJ, Hubler M, Koch T, Albrecht DM. Spinal-epidural hematoma following epidural anesthesia in the presence of antiplatelet and heparin therapy. *Anesthesiology* 2001;95:1031-3.
16. Tam NL, Pac-Soo C, Pretorius PM. Epidural haematoma after a combined spinal-epidural anaesthetic in a patient treated with clopidogrel and dalteparin. *Br J Anesth* 2006;96:262-5.
17. Tryba M, Wedel DJ. Central neuraxial block and low molecular weight heparin (enoxaparin): lessons learned from different dosage regimens in two continents. *Acta Anaesthesiol Scand Suppl.* 1997;111:100-4.
18. Calleja AM, Dommaraju S, Gaddam R, Cha S, Khandheria BK, Chaliki HP. Cardiac risk in patients aged >75 years with asymptomatic, severe aortic stenosis undergoing noncardiac surgery. *Am J Cardiol* 2010;105:1159-63.
19. Klimscha W, Weinstabl C, Ilias W, et al. Continuous spinal anesthesia with a microcatheter and low-dose bupivacaine decreases the hemodynamic effects of centroneuraxis blocks in elderly patients. *Anesth Analg* 1993;77:275-80.
20. Miller RD, Eriksson LI, Fleisher LA, Wiener-Kronish JP, Young WL. *Miller's anesthesia*. 7th ed. Philadelphia: Churchill Livingstone; 2010. p. 283.
21. Stewart A, Fernando R, McDonald S, Hignett R, Jones T, Columb M. The dose-dependent effects of phenylephrine for elective cesarean delivery under spinal anesthesia. *Anesth Analg* 2010;111:1230-7.
22. Lecoq JP, Brichant JF, Lamy ML, Joris JL. Norepinephrine and ephedrine do not counteract the increase in cutaneous microcirculation induced by spinal anaesthesia. *Br J Anaesth* 2010;105:214-9.
23. Albane`se J, Leone M, Garnier F, Bourgoin A, Antonini F, Martin C. Renal effects norepinephrine in septic and nonseptic patients. *Chest* 2004;126:534-9.
24. Rokytka R Jr, Tesarova J, Pechman V, Gajdos P, Krouzecky A. The effects of short-term norepinephrine up-titration on hemodynamics in cardiogenic shock. *Physiol Res* 2010;59:373-8.

Author Information

Dae Seok Oh, MD

Department Of Anesthesia & Pain Medicine, Tongyeong Red Cross Hospital

Hyae Jin Kim, MD

Department Of Anesthesia & Pain Medicine, Pusan National University Of School