

Cysticercosis Of The Extraocular Muscles. Our Experience And Review Of The Medical Literature.

H Foyaca-Sibat, M Salazar-Campos, L Ibañez-Valdés

Citation

H Foyaca-Sibat, M Salazar-Campos, L Ibañez-Valdés. *Cysticercosis Of The Extraocular Muscles. Our Experience And Review Of The Medical Literature..* The Internet Journal of Neurology. 2012 Volume 14 Number 1.

Abstract

Ocular cysticercosis is caused by the growth of the larvae of *Taenia solium* within the ocular tissues and the cysts may be located in descending order of frequency, sub retinal (35%), vitreous (22%), conjunctiva (22%), anterior segment (5%) and orbit (1%). The extraocular muscle form is the most common type of orbital cysticercosis. In the ocular form, the most favored sites are the vitreous and the sub retinal space whereas the inferior rectus and the medial rectus are the most common extraocular muscles involved. Intraocular cysticercosis is predominant in the Western countries, whereas extraocular is more common in the Indian population and several authors have attributed geographic and environmental factors.

INTRODUCTION

Cysticercosis is a zoonotic parasitic infection caused by the larval stage (*Cysticercus cellulosae*) of the pig tapeworm *Taenia solium*. This is the most common helminth to produce CNS infection in human beings (neurocysticercosis). The occurrence of acquired epilepsy or the syndrome of raised intracranial pressure in a person living in or visiting a region where tenaciosis is endemic or even in one living in close contact with people who have taeniasis should suggest a diagnosis of cysticercosis. Neurocysticercosis (NCC) may remain asymptomatic for months to years and sometimes its diagnosis is made incidentally when neuroimaging is performed. Symptoms and signs are related both: the parasite and the inflammatory-immunological response of the host. NCC is the most common cause of acquired epilepsy worldwide and most of the patients taking valproate acid, or carbamazepine for a proper control of their seizures, respond very well [1-7].

The orbits are two bony cavities occupied by the eyes and associated muscles, nerves, blood vessels, fat, and much of the lachrymal apparatus. Each orbit is shaped like a pear or a four-sided pyramid, with its apex situated posteriorly and its base anteriorly. The orbit is related to its superior side to the anterior cranial fossa and usually to the frontal sinus, laterally to the temporal fossa in (anterior) and to the middle cranial fossa (posterior), on its inferior side of the maxillary sinus, and medially to the ethmoid bone and the anterior extent of the sphenoid sinus.

Orbital cysticercosis is caused by the infestation of the larval form of the pork tapeworm *Taenia solium* in the orbital cavity affecting the eyeball (ocular cysticercosis) or the extraocular structures found within the orbital cavity such as: extraocular muscles, nerves, ganglions, and fatty tissue. Orbital cysticercosis may cause significant visual loss, especially if the cyst is located intraocular or is compressing the optic nerve. [6]

Ocular cysticercosis may be extraocular (in the sub-conjunctival or orbital tissues) or intraocular (in the vitreous, sub-retinal space, or anterior chamber). [6-8] Ocular manifestations of cysticercosis vary from asymptomatic to painful blind eye and may be associated with neurological symptoms such as headache, fits, diplopia, and restriction of the ocular movements, and visual problem.

According to some authors the most common location of the ocular CC is the sub retinal region (35 %), followed by the vitreous cysticercosis (22 %), conjunctival cysticercosis (22 %), and anterior segment cysticercosis (5 %) [9] while involvement of other regions (e.g., extraocular muscles, optic nerve) are relatively less common. [6]

Sub retinal cysticercosis (SrCC), vitreous cysticercosis (VCC) and anterior segment cysticercosis (AsCC) are more common in India. While either eye may be affected, bilateral involvement is rare [10] and multiple cysts may develop in the same eye. [11] Ocular manifestations may be devastating as the cysticercus enlarges. The cysticercus may lead to

blindness in 3-5 years. [12] Decreased vision, pain, and recurrent redness of the involved eye are common symptoms of intraocular cysticercosis. [6]

Some authors consider that intraocular cysticercosis is predominant in the Western countries, whereas extraocular is more common in the Indian population attributed to geographic and environmental factors. [13, 15] However, other affirms that intraocular involvement is more common in India compared with Western countries. [15] and involvement of conjunctiva is most commonly reported in India [16-35], whereas involvement of posterior segment of the eye is most commonly seen in Western countries. [36-45] compared with conjunctival region but it also can be seen in India. [46, 47]

Orbital cysticercosis should be suspected in patients who have lived in an endemic area and who develop uveitis, leucocoria or neuro-ophthalmological signs, also in the presence of sub conjunctival cysts or lids nodules. Cysts deep within the orbit are best treated conservatively with a 4-week regimen of oral albendazole (15 mg/kg/d) in conjunction with oral steroids (1.5 mg/kg/d) in a tapering dose over a 1-month period. Treatment may increase inflammation as the cyst involutes, leading to worsening clinical status. Thus, concomitant administration of corticosteroids is recommended to avert an inflammatory response. [49,50] Extraocular myocysticercosis is a challenge for a neurologist, ophthalmologist, neuroophthalmologist and general practitioner not familiarize with this pathological process and delayed diagnosis can cause permanent blindness.

EXTRAOCULAR MUSCLE CYSTICERCOSIS

One of the primary symptoms of extraocular cysticercosis is double vision (diplopia) from misalignment of the visual axes, and the pattern of image separation is the key to diagnosing which particular cranial nerve (and extraocular muscle) is involved.

LEVATOR PALPEBRAE SUPERIORIS MUSCLE CYSTICERCOSIS AND PALPEBRAL PTOSIS

It is well known that cysticercosis of the extraocular musculature is rare and within this group the affection of the eyelid is about 0.6% [13] despite the number of patients reported in the medical literature. [51-54] The Levator palpebrae superioris muscle cysticercosis presenting clinically as ptosis is much more uncommon than other affected extraocular muscles. [55,56]

Cysticercosis of the Levator palpebrae superioris, superior rectus, eyelid or anterior orbit are important differential diagnoses for acquiring ptosis. [56] Features suggestive of Levator palpebrae superioris myocysticercosis include a young patient from an endemic region with a suggestive exposure history, proptosis, mild lid edema or erythema and a palpable cystic eyelid mass. [57]

Only six patients (all from India) have been reported in the medical literature, they had between 9 and 23 years of age and most of some of them complained of unilateral ptosis, inflammation of the upper eyelid and restricted ocular motility while another complained of mild upper eyelid discomfort without display or decreased vision and no lid erythema or edema plus full extraocular movements in all directions of gaze [56, 57, [14, 29, 58,59]

In patients presenting fluctuating palpebral ptosis with negative neostigmine and electrophysiological tests (pseudo myasthenia) cysticercosis of midbrain should be investigated because focal encephalitis and edema at the midbrain may cause this symptomatology. [60]

Indeed, ocular cysticercosis is not a rare disease in the developing countries, and ptosis due to cysticercosis is sporadically reported [61] but it should keep in mind during the differential diagnosis of unilateral eyelid ptosis.

SUPERIOR RECTUS MUSCLE CYSTICERCOSIS

Extraocular muscle cysticercosis is the most common site of this parasitic disease when involving the orbit. [62]

In some series of patients with extraocular cysticercosis, the superior rectus muscle is one of the most commonly affected (33.3%) compared other muscles involved. [13] and clinical features usually are painful unilateral ptosis, inflammation of the upper eyelid and some restriction on down gaze. Diagnosis is made by neuroimagen studies that show a well-defined ring-enhancing lesion in the superior rectus muscle. [14]

Angotti-Neto et. al., [62] reported a 38-year-old Brazilian female patient with extraocular muscle enlargement and a small cystic lesion near the insertion of the superior rectus muscle treated with oral prednisone for almost one year due to a non-specific inflammation of right orbit diagnosis later confirmed as superior rectus muscle cysticercosis. That report illustrates the consequences of delayed antiparasitic treatment leading to leading to marked hypertrophy and limitation of infraduction and later an incomplete recovery.

It also serves to emphasize that cysticercosis should be included in the differential diagnosis of extraocular muscle enlargement, especially in cases of orbital inflammation non-responsive to corticosteroid treatment.

INFERIOR RECTUS MUSCLE CYSTICERCOSIS

The inferior rectus muscle was commonly involved in one study. [56] Inferior rectus cysticercosis like other the affected extraocular muscle typically shows fusiform enlargement of its belly and contain a well-defined, spherical cyst with a nodule attached to its wall. This nodule and the enlarged muscle show intense enhancement on the contrast-enhanced studies. [60, 61]

In a Meher ' series [60] about six patients presenting extraocular muscle cysticercosis two of them had inferior rectus muscle involvement and proptosis for the eyes but imaging studies of the brain showed no evidence of cerebral cysticerci in any of the patients and not palpable subcutaneous nodules were found.

Based on the clinical features of patients reported in the medical literature [62] and our observations, the commonest symptom and signs of the inferior rectus cysticercosis are eccentric proptosis and restriction of upward gaze no associated with loss of vision or painful eyes. MRI orbit is the investigation of choice which can reveal a cystic lesion in the belly of inferior rectus muscle, hypointense on T1 and hyperintense on T2 weighted images and a tiny eccentric hypointense speck suggestive of scolex can be seen.

Shadangi et al [63] have noticed that the cysticerci of the extraocular muscles travel forward, come to lie in a subconjunctival location and then extrude out spontaneously and they have adopted a policy to wait and watch in these cases. They avoid giving steroids and anthelmintic as these suppress inflammation and delay the movement of the cyst outward, and hence, its extrusion. Because delayed treatment can favored chronic inflammatory process, associated fibrosis and permanent damage on the physiology of the muscles, in our opinion, each patient should be assessed individually and a decision should be taken accordingly. [64,65]

SUPERIOR OBLIQUE MUSCLE CYSTICERCOSIS

In one of the large series of patients presenting extraocular muscle cysticercosis (n=35) the average age was 19.6 years, no differences between female and males were found and the most common clinical feature was restricted ocular motility

with diplopia and recurrent pain and redness. [66, 67] In the superior oblique muscle cysticercosis are kept the same demographic and clinical feature described for other extraocular muscles. However, the lateral rectus, medial rectus and the superior oblique were affected to a greater extent and in all cases the extraocular muscle cysticercosis can be suspected in cases of acquired ocular motility disorder with recurrent ocular congestion. Perhaps the most interesting aspect of superior oblique cysticercosis is its clinical presentation as: Brown syndrome and Canine tooth syndrome.

Brown syndrome is defined as an ocular motility disorder, characterized by an inability to elevate the adducted eye actively or passively. In 1950, Harold W. Brown first published on an unusual motility disorder, characterized by the following: limited elevation in adduction; divergence in straight upgaze (V-pattern); same degree of limitation on versions, ductions, and forced ductions; widening of the palpebral fissure on adduction; normal or near normal elevation in abduction; restricted forced ductions to elevation in adduction; and compensatory chin elevation for binocular fusion.

Diplopia may occur when the patient looks up and to the contralateral side of the affected eye. The most common signs of Brown syndrome include: supranasal orbital pain, tenderness. Limited elevation in adduction, an invariable sign, is the hallmark of Brown syndrome and pain that is associated with this ocular movement. The canine tooth syndrome is an ocular motility disorder comprising ipsilateral Brown's syndrome and superior oblique muscle dysfunction. Ocular motility shows ipsilateral deficit of elevation and depression, maximum in an adducted position. Superior rectus muscle cysticercosis should be considered in the differential diagnosis of acquired motility disorder. The acquired Brown syndrome is known to occur after trauma, iatrogenic events, cysts of superior oblique muscle, tenosynovitis, and systemic lupus erythematosus [68]. Rao et al [69] reported seven patients presenting Brown syndrome secondary to superior oblique muscle cysticercosis. All patients had the ocular motility limitation, ie, limitation of elevation in adduction (characteristic of Brown syndrome) and associated pain and swelling in the superior nasal orbit.

INFERIOR OBLIQUE MUSCLE CYSTICERCOSIS

Based on our experience and an extensive review of the medical literature we conclude that cysticercosis of the inferior oblique muscle practically does not exist in human

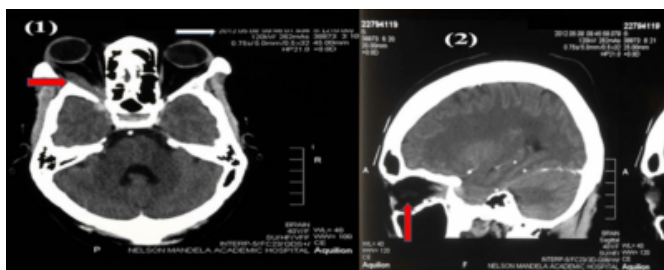
beings compare with other presentations. Despite the inferior oblique muscle has the same chance to be infected by *T. solium* like other extraocular muscles, we think it is rarer than the other because the inferior oblique is unique among the extraocular muscles in that, in many cases, weakening of this muscle, even with extensive surgery, seems to have relatively little effect on the movement of the globe or alignment of the eyes. Therefore isolated cysticercotic lesion on the inferior oblique muscle can be asymptomatic. Even in patients presenting a relatively uncommon inferior oblique paresis due to other causes, strabismus is much less than would occur after paresis of any of the other muscles. Effective weakening of this muscle could be made more difficult because of the unique anatomy. Likewise neurologically, the muscle innervation by the inferior branch of cranial nerve III makes isolated paralysis extremely uncommon. [71]

LATERAL RECTUS MUSCLE CYSTICERCOSIS

A few weeks ago one of our patients came to the department of ophthalmology in Nelson Mandela Academic Hospital complaining of pain on the left eye, horizontal diplopia, poor vision, and proptosis of the left eye. She was assessed by two of us (MCSC and HFS). Apart from CT scan findings (See figure 6), the ELISA test for IgG antigen (*Teniasolium*) in the cerebro-spinal fluid was positive. She is still under medical treatment with prednisone and albendazole and responding well to the medications.

Figure 1

Figure 1: CT scan axial view (1) shows proptosis of the left eyes and lateral rectus myocysticercosis. Intramuscular cyst with "scolex" within is seen. Lateral view (2) shows enlargement of the lateral rectus muscle and an associated intraparenchymal calcified neurocysticercosis.



Extraocular cysticercosis associated to disseminate cysticercosis including NCC can be seen. It was communicated by Patwardhan and Bhatti [47] in India. They reported a young male patient complaint of blurring of vision in the left eye for a few days. Funduscopy examination showed vitreous haze, localized in the lower

half, of the vitreous. A clearly defined, spherical, white mass somewhat resembling a dislocated lens, was seen in the vitreous body and anterior to the retina, freely mobile, lying in the lower temporal quadrant. This mass showed occasional contractile waves passing through it. Systemic examination showed the presence of subcutaneous nodules on the scalp, and neck. CT scan confirmed multiple neurocysticercosis cysts involving superior and medial rectus bilaterally and right lateral rectus.

One or more extraocular muscles may be simultaneously involved, although a propensity for involvement of the superior muscle complex and the lateral rectus muscles has been most commonly reported. [26,63] As was before-cited, according to muscle involved, patients will present different clinical manifestations such as; Brown syndrome, Canine tooth syndrome, Duane retraction, Skew deviation, overreaction, different types of diplopia, and painful proptosis. Also acquired strabismus, recurrent redness and some of the clinical signs in patients with orbital cysticercosis can be observed. [6]

MEDIAL RECTUS MUSCLE CYSTICERCOSIS

It is the largest of the extraocular muscles and its only action is adduction of the eyeball. Its function is to bring the pupil closer to the midline of the body. It is tested clinically by asking the patient to look medially.

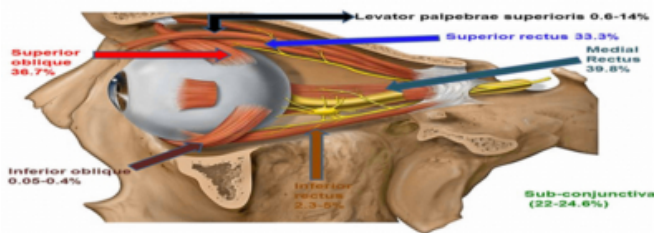
In our experience, an isolated paralysis of the medial rectus muscle due to cysticercosis without involvement of other muscles is very uncommon. In this type of weakness or paralysis the greatest defect of ocular motility occurs when the affected eye goes to adduction position. In the differential diagnosis of an isolated medial rectus paralysis, internuclear ophthalmoplegia is listed.

Cysticercosis as a cause of medial rectus myositis have been reported by others [58, 63, 64] most of the patients presented headache, orthotropia in primary gaze, painful drooping of the eyelid, decrease visual acuity, and an examination of the ocular motility, abduction deficit with the resulting horizontal diplopia is found. Sometimes the head of patients turns to the non-paretic side to allow them to attain single binocular vision. The most common extra ocular muscle to get involved in cysticercosis is the medial rectus. [63]

In the next figure we summarize the frequency of affected extraocular muscle by cysticercosis before medical treatment

Figure 2

Figure 2: Distribution of extraocular myocysticercosis in the orbital cavity.



TREATMENT OF EXTRAOCULAR MUSCLE CYSTICERCOSIS

Contact B-scan ultrasonography was a positive diagnostic test of cysticercosis in 84.4% of patients [13] but the accuracy of a CT scan and MRI is more than 98% in our series.

Surgical excision of an extraocular muscle cyst had been described [13, 61, 72, 73]. In contrast to medical treatment, surgical excision is technically difficult due to the attachment of the cysts to underlying orbital structures, the amorphous consistency of degenerating cysticerci and the risk to neurovascular structures in the posterior orbit. [29] There is also a likelihood of postoperative restrictive myopathy arising from the fibrotic response in surgical excisions of large cysts or in cysts requiring extensive dissection from the underlying muscle. The potential risk of damage to adjacent tissue and adhesion from surgical exploration should not be taken lightly, particularly when effective medical therapy is available. As a general consent medical treatment with albendazol and prednisone is the best choice taken by most of the authors and recommended duration of treatment varies from a few days to up to 6 weeks. [6,10,13,14, 46, 56, 70, 74-86]

In some, cyst elimination rates were more than 90%, and time to recovery of ocular motility ranged between 0.5 and 35 month. [87,88, 89]

Although oral albendazole and prednisone are efficient, a long history of disease can lead to important residual ocular motility restriction and some author found that oral albendazole and prednisone are not effective thus their role in ocular cysticercosis need to be studied. [90]

CONCLUSION

The cysticercosis of the orbit is an uncommon zoonotic parasitic disease. Its early diagnosis and appropriate treatment avoid the permanent loss of vision. The surgical

treatment is the best choice in intraocular cysticercosis while medical treatment is the best choice for extraocular presentations including the extraocular muscles cysticercosis. It must take into account other processes that mimic the orbital cysticercosis in their differential diagnosis. Although it is a rare disease it is a challenge for those health professionals committed to the management of these patients.

References

1. Sotelo J. Neurocysticercosis. Eradication of cysticercosis is an attainable goal. *BMJ*. 2003;326(7388):511-512.
2. Hotez PJ; Bottazi ME, Franco-Paredes C, Ault SK, Periago MR. The Neglected Tropical Diseases of Latin America and the Caribbean: A Review of Disease Burden and Distribution and a Roadmap for Control and Elimination. *PLoS Neglected Tropical Diseases* 2008; 2: e300 doi:10.1371/journal.pntd.0000300.
3. García HH, Gonzalez AE, Evans CA, Gilman RH; Cysticercosis Working Group in Peru. *Taenia solium* cysticercosis. *Lancet*. 2003; 362: 547-556.
4. García HH, Del Brutto OH; Cysticercosis Working Group in Peru. Neurocysticercosis: updated concepts about an old disease. *Lancet Neurol*. 2005; 4:653-661.
5. Román G, Sotelo J, Del Brutto O, Flisser A, Dumas M, Wadia N et al. A proposal to declare neurocysticercosis an international reportable disease. *Bull World Health Organ* 2000; 78: 399-406.
6. Sawhney IM, Singh G, Lekhra OP, Mathuriya SN, Parihar PS, Prabhakar S. Uncommon presentations of neurocysticercosis. *J Neurol Sci*. 1998;154(1):94-100.
7. Loo L, Braude A: Cerebral cysticercosis in San Diego: a report of 23 cases and review of the literature. *Medicine (Baltimore)* 1982;61:341-350.
8. McComick G, Zec Chi-S, Heiden J. Cysticercosis Cerebri. Review of 127 cases. *Arch Neurol* 1982; 39:534-539.
9. Carpio A. Neurocysticercosis: an update. *Lancet Infect Dis* 2002;2:751-762.
10. Wadia N, Desai S, Bhatt M: Disseminated cysticercosis. New observations, including CT scan findings and experience with treatment by praziquantel. *Brain* 1988, 111:597-614.
11. Bhalla A, Sood A, Sachdev A, Varma V. Disseminated cysticercosis: a case report and review of the literature *Medical Case Reports* 2008; 2:137-140. <http://www.jmedicalcasereports.com/content/2/1/137> (accessed May 04, 2012).
12. Foyaca-Sibat H, Ibanez-Valdes LdeF, Mashiyi MK. Disseminate Cysticercosis. One-day treatment in a case. *Rev Electron Biomed / Electron J Biomed* 2004;3:39-43. <http://biomed.uninet.edu/2004/n3/foyaca-n.ht> ml (accessed 05 May,2012).
13. Park SY, Min HK, Jung HK, Kwan YS. Disseminated cysticercosis. *Journal of Korean Neurosurgical Society*. 2011;49(3):190-193.
14. Basu G, Surekha V, Ganesh A. Disseminated cysticercosis. *Trop Doct*. 2009;39(1):48-99.
15. Pushker N, Bajaj MS, Balasubramanya R. Disseminated cysticercosis involving orbit, brain and subcutaneous tissue. *J Infect*. 2005;51(5):245-248.
16. Narang P, Chhibbers S, Puri SK. Middle-aged man with altered behaviour and seizures. *The British Journal of Radiology*, 81 (2008), 984-986.
17. Jakhere SG, Chemburkar VC, Yeragi BS, Bharambay

- HV. Imaging findings of disseminated cysticercosis with unusual involvement of spleen and pancreas. *J Glob Infect Dis.* 2011 Jul;3(3):306-308.
18. Sandeep GJ, Vipul CC, Bhakti SY, Himanshu VB. Imaging Findings of Disseminated Cysticercosis with Unusual Involvement of Spleen and Pancreas. *J Glob Infect Dis.* 2011;3(3):306-308.
20. Niakara A, Cisse R, Traore A, Niamba PA, et al. Myocardial localization of a disseminated cysticercosis. Echocardiographic diagnosis of a case. *Arch Mal Coer Vaiss* 2002;95(6):606-608.
21. Blandon R, Leandro IM: Human Cardiac cysticercosis. *Rev Med Panama.* 2002; 27:37- 40.
22. Foyaca-Sibat H, L. Ibanez-Valdes L: Generalized Cysticercosis With Cardiac Involvement. *The Internet Journal of Neurology.* 2007 Volume 7 Number 2. <http://www.ispub.com/journal/the-internet-journal-of-neurology/volume-7-number-2/generalized-cysticercosis-with-cardiac-involvement.html>. (accessed 05 May 2012)
23. Thomas MB, Thomas KM, Awotedu AA, Blanco-Blanco E, Anwary M. Cardiocysticercosis. *S Afr Med J* 2007;97(7):504-505.
24. Eberly MD, Soh EK, Bannister SP, Taraf-Motamen H, Scott JS: Isolated Cardiac Cysticercosis in an adolescent; *Pediatr Infect Dis J.* 2008; 27(4); 369-71.
25. Jain BK, Sankhe SS, Agrawal MD, Naphade PS. Disseminated cysticercosis with pulmonary and cardiac involvement. *Indian J Radiol Imaging* 2010;20:310-313.
26. Scholtz L & Mentis H, Pulmonary cysticercosis. *SAMT* 1987 ;72(17) :573
27. Mamere AE, Muglia VF, Simao GN, Belucci AD, Carlos dos Santos A, Trad CS, et al. Disseminated cysticercosis with pulmonary involvement. *J Thorac Imaging* 2004;19:109-111.
28. Banu A, Veena N. A rare case of disseminated cysticercosis: Case report and literature review. *Case Report.* 2011;29(2):180-183.
29. Sekhar GC, Honavar SG. Myocysticercosis: experience with imaging and therapy. *Ophthalmology.* 1999;106(12):2336-2340.
30. Bhigjee AI. Disseminated cysticercosis. *J Neurol Neurosurg Psychiatry* 1999;66(4):545
31. Thomas MB, Thomas KM, Awotedu AA, Blanco-Blanco E, Anwary M. Cardiocysticercosis. *South Africa Medical Journal.* 2007; 97(7): 504-505
32. Sobnach S, Khosa SA, Pather S, Longhurst S, Kahn D, Raubenheimer PJ. First case report of pharyngeal cysticercosis. *Trans R Soc Trop Med Hyg.* 2009;103(2):206-208.
33. White AC Jr. Neurocysticercosis: updates on epidemiology, pathogenesis, diagnosis and management. *Ann Rev Med* 2000;51:187-206.
34. Foyaca-Sibat H. Epilepsy Secondary to Parasitic Zoonoses of the Brain, Novel Aspects on Epilepsy, Humberto Foyaca-Sibat (Ed.), ISBN: 978-953-307-678-2, InTech, Rijeka, 2011.
35. Sarti E, Schantz PM, Plancharte A, Wilson M, Gutierrez R, Lopez AS, Roberts J, Flisser. Prevalence and risk factor for *Taenia solium* taeniasis and cysticercosis in humans and pigs in a village in Morelos, Mexico. *Am J Trop Med Hyg* 1992; 46:677-684.
36. Garg RK. Neurocysticercosis. *Postgrad Med J* 1998; 74(872):321-326.
37. Schantz PM, Moore AC, Muñoz JL, et al.: Neurocysticercosis in an Orthodox Jewish community in New York City. *N England J Med* 1992;327:692-696.
38. Rousseau MC, Guillotel B, Delmont J. Neurocysticercosis in the South-East of France 1988-1998. *Presse Med* 1999;28(39):2141-2144.
39. O'Neal S, Noh J, Wilkins P, Keene W, Lambert W, Anderson J, Compton Luman J, Townes J. *Taenia solium* Tapeworm Infection, Oregon, 2006-2009. *Emerg Infect Dis.* 2011 Jun;17(6):1030-1036.
40. Kelesidis T, Tsiodras S. Extraparenchymal neurocysticercosis in the United States: a case report. *Journal of Medical Case Reports* 2011;5:359 .
41. Serpa JA, Graviss EA, Kass JS, White AC Jr. Neurocysticercosis in Houston, Texas: an update. *Medicine (Baltimore).* 2011;90(1):81-86.
42. Wallin M, Kurtzke J. Neurocysticercosis in the United States: review of an important emerging infection. *Neurology* 2004; 63: 1559-1564.
43. Pawlowski ZS. Control of neurocysticercosis by routine medical and veterinary services. *Trans R Soc Trop Med Hyg* 2008;102:228-232.
44. Takayanagui OM, Odashima NS. Clinical aspects of neurocysticercosis. *Parasitol Int.* 2006;55:S111-S115.
45. Sánchez L, Abad L, Lozano E, Maldonado G. Neurocysticercosis intraventricular. Presentación de un caso localizado en el tercer ventrículo. *Radiología.* 2002;44:309-313.
46. Amaral L, Maschietto M, Maschietto R, Cury R, Ferreira NF, Mendonça R, et al. Unusual manifestations of neurocysticercosis in MR imaging : analysis of 172 cases. *Arq Neuropsiquiatr.* 2003;61:533-541.
47. Sarti E. La taeniasis y cisticercosis en México (revisión bibliográfica). *Salud Pública Mex* 1986; 28:556-563.
48. Rabiela MT, Lombardo L, Flores F. Cisticercosis cerebral. Estudio de 68 casos de autopsia. *Patología (Mex)* 1972; 10:27-40.
49. Lopez-Hernández A, Garaizar C. Childhood Cerebral Cysticercosis: clinical features and computed tomographic findings in 98 Mexican children. *Can J Neurol SC* 1982;9:401-407.
50. Flisser A. Neurocysticercosis in Mexico. *Parasitol Today.*1988; 4:131-137.
51. Sotelo J, Penagos P, Escobedo F, Del Brutto OH: Short course of albendazole therapy for neurocysticercosis. *Arch Neurol.* 1988;45:1130-1133.
52. Agapejev S. Epidemiology of Neurocysticercosis. in *Brazil. Rev Inst Med Trop Sao Paulo* 1996;38(3):207-216.
53. Ramírez G, Pradilla G, Rodríguez M, González C. Cisticercosis. Estudio de 80 casos. *Acta Med Colombiana* 1986;11:62-73.
54. Botero D. Cisticercosis en Colombia. Investigaciones realizadas hasta 1988. *An Acad Med Medellin* 1989;2(II):75-82.
55. Takayanagui OM, Jardim E. Clinical aspects of neurocysticercosis: analysis of 500 cases. *Arq Neuropsiquiatr* 1983; 41(1):50-63.
56. White AC Jr. Neurocysticercosis: updates on epidemiology, pathogenesis, diagnosis and management. *Ann Rev Med* 2000;51:187-206.
57. Foyaca-Sibat H, Del Rio AR, Ibañez-Valdés LdeF, Vega-Novoa EC, Awotedu A. "Neuroepidemiological survey for Epilepsy and knowledge about neurocysticercosis at Sidwadweni location, South Africa" *Electron J Biomed* 2004;2(1):40-48.<http://www.biomed.edu/2004/n1/foyaca.ht> ml
58. Foyaca-Sibat H, Del Rio-Romero AH, Ibañez-Valdés LdeF, Vega-Novoa E. Neuroepidemiological Survey For Epilepsy And Knowledge About Neurocysticercosis At Ngqwala Location, South Africa. *The Internet Journal of Neurology* 2005 3(2). http://www.ispub.com/journal/the_internet_journal_of_neurology/volume_3_number_2_31/article/neuroepidemiological

- _survey_for_epilepsy_and_knowledge_about_neurocysticercosis_at_ngqwala_location_south_africa.html
59. Foyaca-Sibat H, A. Del Rio-Romero, Ibañez-Valdés LdeF : Prevalence Of Epilepsy And General Knowledge About Neurocysticercosis At Ngangelizwe Location, South Africa . The Internet Journal of Neurology. 2005 Volume 4 Number 1.
http://www.ispub.com/journal/the_internet_journal_of_neurology/volume_4_number_1_30/article/prevalence_of_epilepsy_and_general_knowledge_about_neurocysticercosis_at_ngangelizwe_location_south_africa.html
60. Foyaca-Sibat H, Del Rio A: "Epilepsy, Neurocysticercosis and, Poverty at Mphumaze and Marhambeni Locations, in South Africa". The Internet Journal of Neurology (ISSN: 1531-295X). 2007;7(1):8-14.
http://www.ispub.com/journal/the_internet_journal_of_neurology/volume_7_number_1_7/article/epilepsy_neurocysticercosis_and_poverty_at_mphumaze_and_marhambeni_locations_in_south_africa.html
61. Foyaca-Sibat H, Ibañez-Valdés LdeF, Del Rio IA: "Prevalence of Epilepsy and General Knowledge about Neurocysticercosis at Ngangelizwe Location, South Africa". The Internet Journal of Neurology.(ISSN: 1531-295X). 2005; 4(1):23-37.
http://www.ispub.com/journal/the_internet_journal_of_neurology/volume_4_number_1_30/article/prevalence_of_epilepsy_and_general_knowledge_about_neurocysticercosis_at_ngangelizwe_location_south_africa.html
62. Foyaca-Sibat H, Del Rio- Romero AI: "Prevalence Of Epilepsy In An Endemic Area For Neurocysticercosis In South Africa". The Internet Journal of Neurology.(ISSN: 1531-295X). 2008;9(1):8-18.
http://www.ispub.com/journal/the_internet_journal_of_neurology/volume_9_number_1_6/article/prevalence_of_epilepsy_in_an_endemic_area_for_neurocysticercosis_in_south_africa.html
63. Turkulov V, madle-Samardzija N, Canak G, Vukadinov J, Aleksic-Dordevic M. Clinical and diagnostic approaches to neurocysticercosis. Med Pregl 2001; 54(7-8):353-356.
64. Chimelli L, Lovalho AF, Takayanagui OM. Neurocysticercosis: contribution of autopsies in the consolidated of mandatory notification in Ribeirao Preto-SP, Brazil. Arq Neuropsiquiatr 1998; 56(3B):577-584.
65. Sanchez AL, Ljungstrom I, Medina MT. Diagnosis of human neurocysticercosis in endemic countries: clinical study in Honduras. Parasitol Int 1999;48(1):81-89.
66. Foyaca-Sibat H, Ibañez-Valdés LdeF & J. Moré-Rodríguez : Parasitic Zoonoses Of The Brain: Another Challenger?. The Internet Journal of Neurology. 2010 Volume 12 Number 2.
http://www.ispub.com/journal/the_internet_journal_of_neurology/volume_12_number_2_4/article/parasitic-zoonoses-of-the-brain-another-challenger.html
67. Foyaca-Sibat H and Ibañez-Valdés L de F. (2011). Treatment of Epilepsy Secondary to Neurocysticercosis, Novel Treatment of Epilepsy, Humberto Foyaca-Sibat (Ed.), ISBN: 978-953-307-667-6, InTech, Available from: <http://www.intechopen.com/articles/show/title/treatment-of-epilepsy-secondary-to-neurocysticercosis>
68. Foyaca-Sibat H.(2011). Epilepsy Secondary to Parasitic Zoonoses of the Brain. Novel Aspects on Epilepsy, Humberto Foyaca-Sibat (Ed.), ISBN: 978-953-307-678-2, InTech, Available from: <http://www.intechopen.com/articles/show/title/epilepsy-secondary-to-parasitic-zoonoses-of-the-brain>
69. Murthy GR, Rao AV. Sub-conjunctival cysticercosis. Indian J Ophthalmol. Jul 1980;28(2):77-78.
70. Menon-Mehta S. Ocular Cysticercosis Treatment & Management. eMedicine.2011 <http://emedicine.medscape.com/article/1204683-treatment>
71. Ziaei M, Elgohary M, Bremner FD. Orbital cysticercosis, case report and review. Orbit. Oct 2011;30(5):230-235.
72. Ratra D, Phogat Ch, Singh M, Choudhari NS : Intravitreal cysticercosis presenting as neovascular glaucoma. Indian J Ophthalmol. 2010;58(1):70-73.
73. Kruger-Leite E, Jalkh AE, Quiroz H, Schepens CL. Intraocular cysticercosis. Am J Ophthalmol 1985; 99(3):252-257.
74. Topilow HW, Yimoyines DJ, Freeman HM, et al. Bilateral multifocal intraocular cysticercosis. Ophthalmology. 1981;88(11):1166-1172..
75. Kapoor S, Kapoor MS. Ocular cysticercosis. J Pediatr Ophthalmol Strabismus. May-Jun 1978;15(3):170-173..
76. Sharma T, Sinha S, Shah N, et al. Intraocular cysticercosis: clinical characteristics and visual outcome after vitreoretinal surgery. Ophthalmology. May 2003;110(5):996-1004.
77. Rath S, Honavar SG, Naik M, Anand R, Agarwal B, Krishnaiah S et al. Orbital cysticercosis: clinical manifestations, diagnosis, management, and outcome. Ophthalmology 2010; 117(3):600-5, 605.
78. Sekhar GC, Lemke BN. Orbital cysticercosis. Ophthalmology 1997; 104(10):1599-1604.
79. Natarajan S, Malpani A, Kumar NP, Dutta B. Management of intraocular cysticercosis. Graefes Arch Clin Exp Ophthalmol 1999; 237(10):812-814.
80. Reddy PS, Satyendran OM. Ocular cysticercosis. Am J Ophthalmol 1964;57:664-667
81. Malik SR, Gupta AK, Choudhry S. Ocular cysticercosis. Am J Ophthalmol 1968;66:1168-1171
82. Sen DK, Mathur RN, Thomas A. Ocular cysticercosis in India. Br J Ophthalmol 1967;51:630-632
83. Rao N, Balakrishnan E. Cysticercosis of the eye. Orient Arch Ophthalmol 1967;5:249-252.
84. Reddy CC, Gupta VP, Sarada P, Prabhakar V, Reddy DL, Anjaneyulu C. Ocular cysticercosis: A study of 15 cases. Indian J Ophthalmol 1980;28:69-72
85. Sen DK Cysticercosis cellulosa in the lacrimal gland. orbit end eye lid Acta Ophthalmologica 1980;58:144-147.
86. Murthy GR, Rao AV. Sub-conjunctival cysticercosis. Indian J Ophthalmol. 1980;28(2):77-78.
87. Pushker N, Bajaj MS, Chandra M, Neena. Ocular and orbital cysticercosis. ActaOphthalmol Scand. 2001;79 (4):408-413.
88. SihotaR, Honavar SG. Oral albendazole in the management to extraocular cysticercosis. Br J Ophthalmol 1994;78:621-623.
89. Pandey PK, Chaudhuri Z, Sharma P, Bhomaj S. Extraocular muscle cysticercosis:a clinical masquerade.J Pediatr Ophthalmol Strabismus 2000;37:273-278.
90. Tuli N. A Non Responding Case Of Extraocular Muscle Cysticercosis Mimicking As Pseudo-Tumor Orbit In A Child. The Internet Journal of Ophthalmology and Visual Science. 2010;7(2)

Author Information

H Foyaca-Sibat

Department of Neurology and Department of Ophthalmology, Foyaca-Sibat H Department of Neurology and Department of Ophthalmology. Nelson Mandela Academic Hospital. Faculty of Health Sciences. Walter Sisulu University, Walter Sisulu University

MC Salazar-Campos

Department of Neurology and Department of Ophthalmology, Foyaca-Sibat H Department of Neurology and Department of Ophthalmology. Nelson Mandela Academic Hospital. Faculty of Health Sciences. Walter Sisulu University, Walter Sisulu University

L de F Ibañez-Valdés

Department of Neurology and Department of Ophthalmology, Foyaca-Sibat H Department of Neurology and Department of Ophthalmology. Nelson Mandela Academic Hospital. Faculty of Health Sciences. Walter Sisulu University, Walter Sisulu University