

Isolated Gallbladder Perforation After Blunt Abdominal Trauma In Children: A Case Report.

O Ndour, H Moustapha, N Ndoeye, G NGom

Citation

O Ndour, H Moustapha, N Ndoeye, G NGom. *Isolated Gallbladder Perforation After Blunt Abdominal Trauma In Children: A Case Report..* The Internet Journal of Pediatrics and Neonatology. 2012 Volume 14 Number 1.

Abstract

Injury of the gallbladder after blunt abdominal trauma is rare. Isolated contusion of the gallbladder is exceptional because of its anatomical localization. It is protected by the liver, intestines, the omentum and ribs. Its clinical presentation is often insidious, the reason why the diagnosis is often made during an exploring laparotomy. The delayed diagnosis is often responsible of high morbidity and mortality. Early diagnosis is thus essential but still remains a challenge. We report a case of isolated perforation of the gallbladder after blunt abdominal trauma in a 15 years old boy found at the stage of generalized peritonitis. The exploratory laparotomy leads to diagnosis and treating the lesion by cholecystectomy.

INTRODUCTION

Isolated perforation of the gallbladder by blunt abdominal injury in children is exceptional. It represents only 1.9 to 2.1% of all abdominal traumas [1]. It results in vague symptoms which often lead to delayed diagnosis and therapy. Early exploratory laparotomy is recommended to reduce the high morbidity encountered in this context [2, 3]. We report an isolated gallbladder perforation by abdominal contusion in a 15 years old child with emphasis on diagnostic and therapeutic aspects.

CASE REPORT

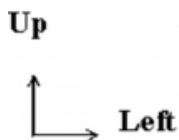
A 15 year old boy with unremarkable previous medical history has been referred by a peripheral hospital for better management in the context of painful abdominal distension. The onset of the symptoms would go back up 3 weeks prior to admission, following an accident in which he got a knee hit on the epigastrium. His abdomen increased progressively in volume with intermittent abdominal pain. One week prior to admission the symptoms worsened with severe insomniac abdominal pain, aggravated by any feeding attempt. This situation evolved in an afebrile context, food debris contained in vomitus and conserved digestive transit. On admission he had a good general condition with good hemodynamic constants: BP: 120/60mm Hg, RR: 28 beats/minute, and afebrile. We noted a significant abdominal distension. Palpation found a non depressible abdomen but diffuse sensitivity, with the umbilicus cry. The hernial

orifices were free. Plain abdominal X-ray showed a diffuse grayness. The ultrasound found an abundant haemoperitoneum without obvious signs of organic lesions. Guided Ultrasound puncture brought a brownish liquid. The full blood count showed: WBC: 8700; 10.4 g / dl of hemoglobin; platelets: 350,000; PT: 90.6%; TCA: 37' 2 and INR: 1.09.

With this peritoneal syndrome, an urgent laparotomy was indicated. Surgical exploration found a biliary peritonitis with aspiration of approximately 3 liters of bilious fluid, multiple enteric adhesions and abdominal wall adhesions to the small intestines. We discovered a perforation of the gallbladder measuring about 1 cm in diameter with regular edges (Fig. 1). Extrahepatic bile ducts were intact as well as the duodenum, spleen, kidneys, stomach, bladder, colon and small intestine. We performed adhesiolysis, washing of the abdominal cavity, antegrade cholecystectomy and the drainage of the peritoneal cavity. Antibiotic therapy based on cefotaxime, gentamicin and metronidazole was initiated. The postoperative phase was uneventful. The patient was effectively discharged on the 8th day. Histological examination of a piece of cholecystectomy noted hemorrhagic necrosis of the gallbladder wall. After four months, the child was symptom free.

Figure 1

Pierced gallbladder bottom by dissecting forceps showed numerous false membranes.



COMMENTS

The lesion of the gallbladder due to blunt abdominal trauma is rare [1]. It represents about 1.9 to 2.1% of all lesions by intra abdominal contusion [1,2]. It is frequently involved in association with other lesions (liver, spleen, stomach, duodenum, pancreas, and kidney). Isolated perforation of the gallbladder is rare if not exceptional [2]. This low incidence is due to its hidden anatomical location; the viscera and rib cage protects it [3]. Most cases are due to road traffic accident or after a direct blow on the abdomen, as it is the case in our patient. The clinical diagnosis is difficult because the signs are not specific. The clinical signs are often vague [3, 4]. This explains the observed delayed diagnosis in most cases [5]. In our patient the consultation period is three weeks with a clinical picture that was well tolerated by the patient. It was especially a marked abdominal distension that motivated the consultation. Para-clinic examinations may not be contributive. Peritoneal lavage is helpful only if the bile is fluid and so many false negative results were reported in the literature [5,6]. The MRI study of the gallbladder depends on its ability to take the contrast which can be disrupted in a trauma case. The ultrasound, CT, MRI may help to make the diagnosis in some rare cases [7]. The biliary isotope scintigraphy combined with computed

tomography, magnetic resonance imaging and retrograde endoscopic cholangiopancreatography, currently allow early diagnosis [3,8, 9]. Laparoscopy can be useful but it would be difficult to be indicated while the clinical picture is vague [1,8]. In our patient we performed an ultrasound which revealed hemoperitoneum and a plain abdominal radiograph which showed a diffuse grayness. These two paraclinical elements didn't allow making the diagnosis. We nevertheless indicated the surgical approach in this context of trauma and peritoneal syndrome. Indeed the continuous effusion of bile into the peritoneal cavity or retro peritoneal space is often fatal. That is why surgery is urgently needed. We performed a cholecystectomy that is currently the treatment of choice. As in our case, the outcome is often good. In isolated fractures of the gallbladder treated surgically, there were no deaths reported [2, 4, 5, 8].

CONCLUSION

We must keep in our minds the possibility of an extrahepatic bile system injury after blunt abdominal trauma with atypical clinical aspects marked especially by progressive abdominal distension. We must use modern methods particularly scintigraphy for early diagnosis. In the African context, this radiography is not often available and should not delay surgical exploration.

References

1. Jaggard MK, Johal NS, Choudhry M. Blunt Abdominal Trauma Resulting in Gallbladder Injury: A Review With Emphasis Pediatrics. *J Trauma-Injury Infect & Critic Care* 2011; 70 (4): 1005-1010.
2. Kim SH, Lee KJ, Kim HR, Kim SJ, Lee SC, Kim JG, Lee DH, Ahn CJ, You YK. Isolated Traumatic Gallbladder Rupture. *J. Korean Surg Soc* 2008 ; 75 (2):145-148.
3. Bainbridge J , Shaaban H, Kenefick N, Armstrong CP. Delayed presentation of an isolated gallbladder rupture following blunt abdominal trauma: a case report. *J Med Case Reports* 2007; 1 (52): 294 -295.
4. Di Carlo I, Sparatore F, Primo S, Toro A. Gallbladder Blunt Trauma: Unusual Presentation and difficult diagnosis. *Chir Gastroenterol* 2006; 22(4): 272-274.
5. Wittenberg A, Minotti AJ. CT Diagnosis of Traumatic Gallbladder Injury. *AJR* 2005; (185):1573-1574.
6. Mendrek MJ, Rodriguez JR, Hardjasudarma M. Traumatic rupture of the gallbladder. *Appl Radiol Arch* 2006; 35 (9).
7. Kao EY, Desser TS, Brooke Jeffrey R. Sonographic Diagnosis of Traumatic Gallbladder Rupture. *J Ultrasound Med* 2002; (21):1295-1297.
8. R. Kohler, R Millin, B Bonner, A Louw. Laparoscopic treatment of an isolated gallbladder rupture following blunt abdominal trauma in a schoolboy rugby player. *Br J Sports Med* 2002; (36) :378-379.
9. Kedra B, Sobocki J. A case of isolated gallbladder rupture after blunt abdominal trauma. *Przegl Lek* 2000; 57 (12): 766-767.

Author Information

Oumar Ndour

Pediatric Surgery Department, Aristide Le Dantec Hospital

Helle Moustapha

Pediatric Surgery Department, Aristide Le Dantec Hospital

Ndeye Aby Ndoye

Pediatric Surgery Department, Aristide Le Dantec Hospital

Gabriel NGom

Pediatric Surgery Department, Aristide Le Dantec Hospital