

Foreign Bodies In The Sigmoid Colon

B Surinder, M Sharma

Citation

B Surinder, M Sharma. *Foreign Bodies In The Sigmoid Colon*. The Internet Journal of Surgery. 2012 Volume 28 Number 5.

Abstract

Foreign bodies pushed into the rectum through the anus for sensuous pleasure are unusual and uncommon. A variety of objects like glass bottles, solid vegetables, fruits, cricket balls, tumblers, wooden handles, candles, bulbs, dildos, vibrators, stones and numerous other objects have been used. Invariably, the individuals do attempt to remove these devices themselves but are forced to seek surgical intervention because of failed attempts to retrieve them. Occasionally, foreign bodies in the form of tubes and catheters may get lodged in rectum or sigmoid following diagnostic and therapeutic interventions. These devices can be removed successfully manually through the anal route under conscious intravenous sedation and analgesia if they are visible and accessible, but will require surgery if they get firmly adherent to gut and become inaccessible or result in damage to gut with peritonitis. These foreign bodies pose a challenge to the surgeon because of delayed presentation and thus valuable time is lost as a result of patients attempting to remove the foreign body themselves or expecting its natural expulsion. Our patients developed acute intestinal obstruction following insertion of foreign bodies. The first case was unique as the device used to extract the plastic bottle from the sigmoid colon got itself stuck in its mucosa resulting in severe pain and obstruction thus necessitating surgery.

INTRODUCTION

Foreign bodies may get impacted in the gastrointestinal tract accidentally after swallowing or after self insertion through the anal canal to seek sexual arousal and pleasure. They may get pushed into the anal canal following assault or mischief or after accidental falls which can lead to serious complications and even death. A few of the foreign bodies like thermometers or tips of enema tubes may get lodged in the rectum as part of medical intervention. The foreign bodies, often in the nature of cylindrical objects, may get stuck in the rectum and might get further pushed up into the sigmoid colon during attempts to remove them. Invariably, attempts are made by individuals to remove these objects manually themselves without seeking medical help for fear of loss of self esteem, disgrace and ridicule by others. These objects may result in injury to rectum and sigmoid colon which calls for urgent surgical intervention. We report here two cases of foreign bodies in the sigmoid colon which necessitated laparotomy. Laparotomy for removal of foreign body is extremely rare. The first case is exceptionally unusual because the patient presented with two foreign bodies, an inextricable plastic bottle in the sigmoid colon and another foreign body, a wire that got stuck in the rectosigmoid in an attempt to remove the plastic bottle. This is the first reported case in the world literature in which a hooked wire has been used to remove the foreign body

which itself got stuck to gut mucosa, jutting out of the anus. The wire could only be removed by cutting it after availing the services of a mechanic during surgery. The second case involved a long solid handle of a broom finding its way into the sigmoid colon after the patient himself introduced it through the anal canal.

CASE REPORT 1

A young patient in the mid-twenties presented with diffuse severe abdominal pain of five hours duration following doubtful history of accidental fall in the toilet on a plastic bottle with its open end getting pushed up into the rectum per anum during defecation. The patient tried to remove the bottle manually unsuccessfully but during this maneuver the bottle got further pushed up proximally. The patient then tried to remove the plastic bottle with the help of a two feet long steel wire which he hooked at one end to engage the bottle and folded the other end for a firm hand grip. During the process the hooked end got stuck in recto sigmoid region, too, resulting in severe abdominal pain and thus also the wire could not be removed by him. The patient was brought to hospital on a stretcher with agonizing severe abdominal pain. On examination, the patient was found to be well built with normal vital parameters. Abdominal examination revealed reflex guarding with a visible and palpable hard tender lump in the left iliac fossa. A steel wire

was seen to be jutting out of the anus. The slightest movement of the wire provoked severe abdominal pain. No attempt was made to remove the wire to avoid further damage. The patient was resuscitated with IV fluids and antibiotics. Laparotomy revealed the sigmoid and rectum distended, stretched and thinned out over the bottle. An incision was made on the healthy colon proximal to the impacted bottle. The hooked end of the wire was maneuvered into the colonic wound and had to be cut with a saw, and both parts were safely pulled out. The longer part of the wire was removed per anum and the shorter part was removed from the colonic incision. The bottle was taken out from the colonic wound by gentle but difficult manipulation. The colonic wound was closed with interrupted 2/0 silk sutures without proximal colostomy. Postoperatively, the patient was managed with antibiotics, intravenous fluids and parenteral nutrition for more than a week. Oral feeding was withheld for a week to give rest to the colon and to reduce the bacterial load on the repaired colonic incision to avoid fistula formation. The patient made an uneventful postoperative recovery.

Figure 1

Figure 1 showing a steel wire introduced by the patient per anum to remove a plastic bottle. The wire was hooked to engage the bottle.

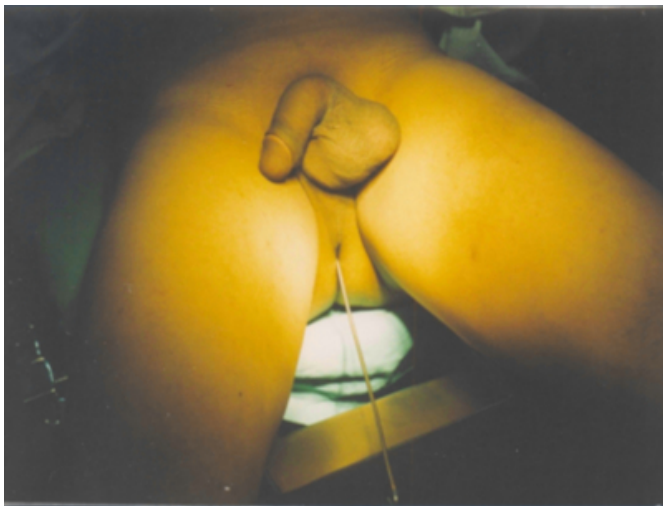

Figure 2

Figure 2: The hooked wire cut into two pieces and both parts of the wire removed. The outer end of the wire was also folded for a proper hand grip to remove the bottle.

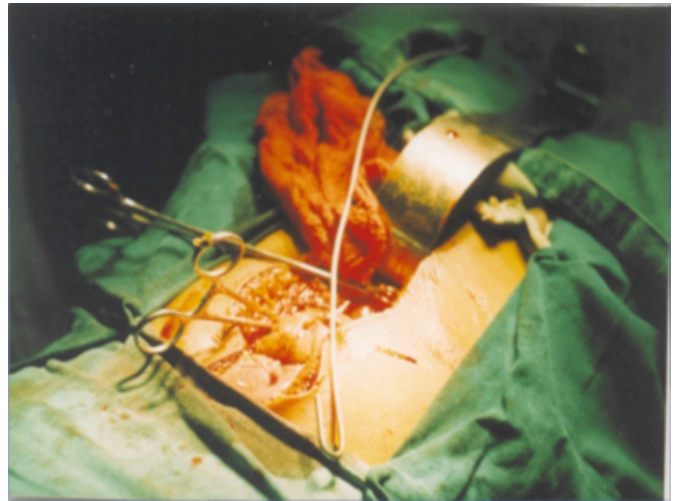


Figure 3

Figure 3: The plastic bottle emerging from the tight grip of the colon.

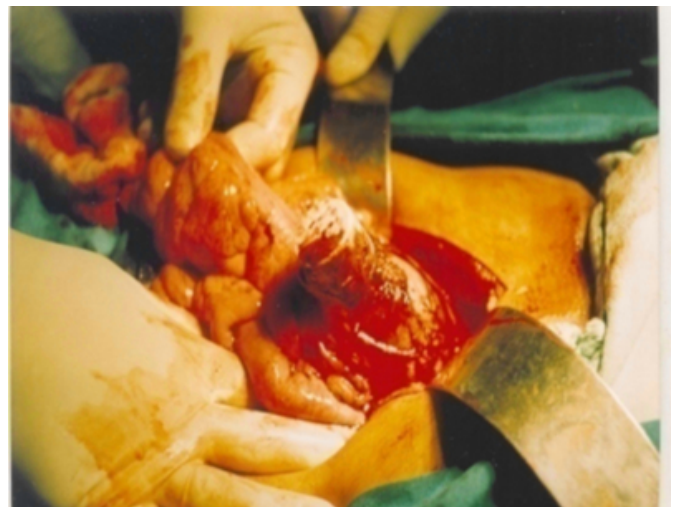
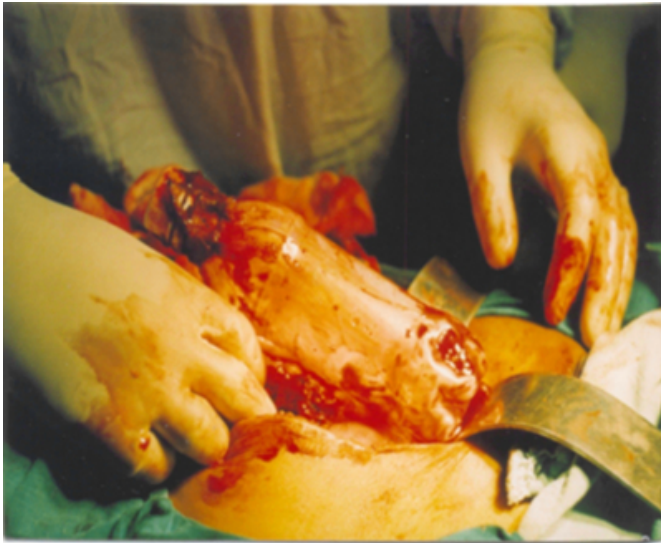

Figure 4

Figure 4: The plastic bottle eased out of the sigmoid colon with patience.



CASE REPORT 2

A 30-year-old patient was admitted to the hospital with clinical features of acute intestinal obstruction after he pushed a cylindrical object into his anal canal ten days back. The patient tried to remove the foreign body manually without success. The patient had mild fever, tachycardia and marked tenderness over the left iliac fossa. Keeping in view the inaccessibility of the foreign body through anal canal, the patient was subjected to surgery. Laparotomy revealed a distended sigmoid colon and a solid cylindrical handle of a broom measuring ten inches in length and two inches in width which was removed gently by rotatory movements without much difficulty. The transverse incision in sigmoid colon was closed primarily with interrupted 2/0 silk sutures in two layers and reinforced with a free omental patch without proximal colostomy. The patient had an uneventful postoperative recovery but oral feeding was started only after ten days to avoid fecal load at the colonic wound and therefore the patient was managed with IV fluids and parenteral nutrition during this period.

Figure 5

Figure 5: Cylindrical handle of a broom removed from the sigmoid colon (second case)



DISCUSSION

Foreign bodies inserted into anal canal or rectum deliberately by individuals to provoke anal eroticism may at times get firmly impacted. The objects may also find their way into the rectosigmoid after assault, trauma and following diagnostic and therapeutic interventions. Objects placed as a result of assault, trauma or eroticism comprise a diverse collection including sex toys (dildos), tools and instruments, bottles, cans, jars, pipes and tubing, fruits and vegetables, stones, light bulbs and flash lights.[1] Rectal foreign bodies, even though rather infrequent, are no longer considered clinical oddities in urgent care facilities and emergency departments, and it appears their incidence is increasing specifically in the urban population.[2] The patient may not always oblige with correct history and sequence of events. A detailed clinical history and physical examination are essential for the diagnosis and management of these lesions.[3] Foreign bodies should be suspected in patients with obscure anal pain. [4] These foreign bodies may slip proximally during vigorous anal action or during manipulation to extract them and result in mucosal edema and bleeding. They may get dislodged into the wider sigmoid colon due to sphincteric spasm and inadvertent manual push during the maneuver to extract them. Such impacted foreign bodies, besides causing intense embarrassment and pain to the individual, may result in complications like intestinal obstruction, perforation of gut and peritonitis. Besides history, clinical examination and investigations are necessary steps for successful outcome. Because of potential complications, rectal foreign bodies should be regarded seriously and treated expeditiously.[5]

The first step in the evaluation is that one should always be aware of the possibility of a large-bowel perforation and perform radiological investigations. An abdominal X-ray will also provide information on the localization of the foreign body, whether it is below or above the rectosigmoid junction.[6] The foreign bodies which are visible, unbreakable, smooth, accessible and non-friable can be removed under analgesia and sedation in the emergency department. These foreign bodies can also be removed under direct visualization with the help of forceps or snares after application of lubricants. Flexible endoscopy may also be useful at times. These objects should be carefully removed lengthwise to avoid injury to rectal mucosa. A unique technique is removal by creating pneumatic dilatation distal to foreign body by an inflatable balloon. A few of the foreign bodies have been removed with the help of Foley catheters negotiated along the foreign body proximally, creating pneumatic dilatation to reduce the negative suction in colon, inflating the balloon and finally pulling down the foreign body along with it. The expertise and ingenuity displayed in removing these objects far exceeds the diversity of objects used for introducing such objects. Glass tumblers with the open end looking downwards have been removed by setting plaster of Paris bandage in it and extracting it with the extruding tail of the bandage. Similarly, gimlets have been used to remove the wooden objects. An electric bulb has been removed by applying a socket. These objects should not be removed forcibly and the period of manipulation should not exceed beyond acceptable limits of thirty minutes. Patients with hypotension, sepsis and complications should be resuscitated with intravenous fluids and antibiotics before intervention. A foreign body palpable in the abdomen can be brought down under general anesthesia to a low-lying position and then should be extracted; however, firmly impacted foreign bodies, as exemplified by the two cases above, should be removed operatively. The sphincters should be assessed for continence after transanal removal of a foreign body. Sometimes, bimanual manipulation of the relaxed abdominal wall under spinal or general anesthesia may evade surgery.[7]

High-lying foreign bodies above the sacral curve cannot be removed without laparotomy. Factors which cause difficulty in extraction of foreign bodies are diffuse mucosal edema, colonic negative pressure, acute angulation of the rectosigmoid and intussusceptions of distal mucosa.[8] Foreign bodies in the low or mid rectum up to a level of 10cm can be most often removed transanally, while those

above 10cm may require laparotomy for retrieval.[9] The removal of a foreign body through the anal route can be facilitated by anal dilatation and sphincterotomy under local anesthesia. Extremely rarely, laparotomy is necessary to remove an object as a primary method of treatment with a high-lying foreign body in the rectum.[10] Early laparotomy is the only recourse left once the complications have set in or the attempts to extract it prove to be unrewarding. Foreign bodies stretching the rectosigmoid and lying firmly adherent to the mucosa must be delivered gently by freeing them from the firm grip of gut wall. The abdominal incision should be made in the infraumbilical midline region. The colonic wound can be closed primarily by interrupted silk sutures without resorting to proximal colostomy unless peritoneal sepsis, edema and rectosigmoid damage so demands. Primary colonic repair demands an extended period of parenteral fluid and nutritional support to ensure integrity of closure. Proximal diverting colostomy is unnecessary in case the sigmoid colon is found to be healthy. Primary colonic repair withstands any possibility of subsequent fistula formation provided the repair is secure and oral feeding is withheld for at least ten days. Primary colonic repair without proximal colostomy avoids prolonged morbidity and further surgery. Primary colonic repair can be done safely provided the gut is clean, viable and healthy. The colonic wound should preferably be repaired by interrupted 2/0 silk sutures as this imparts strength and ensures integrity of closure.

For successful outcome, patients must be evaluated for anatomical location of foreign body, resuscitated and managed by appropriate non-operative manipulation or by operative intervention depending upon indication. These patients must be followed up and investigated postoperatively to exclude injuries to involved gut. They should be suitably counseled to avoid such situations in the future.

CONCLUSION

Low-lying foreign bodies in the rectosigmoid which are solid and small-sized can be removed under conscious intravenous analgesia and sedation but high-lying, firmly impacted foreign bodies and those resulting in complications are best removed by laparotomy under general anesthesia to avoid morbidity and mortality.

References

1. Hellinger MD: Anorectal trauma and foreign bodies. *Surg Clin North Am*; 2002; 82: 1253-60.
2. Goldberg JE, Steele SR: Rectal foreign bodies. *Surg Clin North Am*; 2010; 90: 173-84.
3. Ruiz del Castillo J, Sellés Dechent R, Millán Scheiding

- M, Zumárraga Navas P, Asencio Arana F: Colorectal trauma caused by foreign bodies introduced during sexual activities: diagnosis and management. *Rev Esp Enferm Dig*; 2001; 93: 631-4.
4. Ooi BS, Ho YH, Eu KW, Nyam D, Leong A, Seow-Choen F: Management of anorectal foreign bodies: a cause of obscure anal pain. *Aust N Z J Surg*; 1988; 68: 852-5.
5. Yaman M, Deitel M, Burul CJ, Shahi B, Hadar B: Foreign bodies in the rectum. *Can J Surg*; 1993; 36: 173-7.
6. Narjis Y, Rabbani K, Hakkou K, Aboulhassan T, Louzi A, Benelkhatat R, Finech B, Dafali Ael I: Foreign body of the rectum: An unusual case. *J Emerg Trauma Shock*; 2010; 3: 306.
7. Koornstra JJ, Weersma RK: Management of rectal foreign bodies: Description of a new technique and clinical practice guidelines. *World J Gastroenterol*; 2008; 14: 4403-4406.
8. Bakaleinik M: Foreign bodies of the gastrointestinal tract, surgical considerations. *Mil Med*; 1989; 154: 11-4.
9. Nehme Kingsley A, Abcarian H: Colorectal foreign bodies. Management update. *Dis Colon Rectum*; 1985; 28: 941-4.
10. Schecter WP, Albo RJ: Removal of rectal foreign bodies. In: *Mastery of Surgery*, 3rd ed. Lippincott Williams & Wilkins, Philadelphia, PA; 1996, Vol. 2, pp. 1555-9.

Author Information

Brig (Dr) Surinder

Department of Surgery, Muzaffarnagar Medical College

Mohan Sharma, B.Sc, MBBS, MS, FAIS

Subharti Medical College