

Giant Postauricular Lipoma - A Case Report

S Jadhav, S Dubhashi, P Kumar

Citation

S Jadhav, S Dubhashi, P Kumar. *Giant Postauricular Lipoma - A Case Report*. The Internet Journal of Surgery. 2012 Volume 28 Number 5.

Abstract

Giant lipomas are benign mesenchymal soft-tissue tumors. They are found relatively rarely in the postauricular region. Surgical intervention in these tumors is challenging, because of neurovascular proximity and tendency of malignant change. Knowledge of anatomy and meticulous surgical technique is needed in such giant lipomas.

INTRODUCTION

Lipomas are the most common subcutaneous soft-tissue tumors of mesenchymal origin.

The estimated annual incidence is one per thousand persons¹. They are considered as one of the most “innocent of tumors”. Lipomas rarely may cause symptoms². While 80% of lipomas are less than 5cm in diameter, some can reach up to 20cm. For a lipoma to be referred as “giant”, the lesion should be at least 10cm in diameter. Lipomas growing to a larger size are usually encapsulated when located in the superficial soft tissues. Briefly, lipomas consist of bright yellow fat separated by fine trabeculae. Microscopically, they are composed of mature adipose tissue with no cellular atypia³. Although lipomas have been described in almost all the organs, occurring in the central nervous system, gastrointestinal tract, muscles and joints, most of the time they arise in subcutaneous tissue and can occur in every part of body. They have occasionally been encountered in other non-mesenchymal anatomic locations⁴.

The lesion is often asymptomatic and brought to medical attention because of cosmetic deformity or compression of nervous/vascular structures as occurs in giant lipomas⁵.

We present a rare case of giant lipoma in the postauricular region with diagnostic tests and surgical treatment that was managed successfully.

CASE REPORT

A 40-year-old male presented in our outpatient department with a large swelling in the postauricular region. He was aware of the slow-growing, painless swelling over the past six years. The patient was completely asymptomatic except

that he had cosmetic problems and fear of further enlargement.

Clinical examination revealed a soft, non-mobile, non-tender mass of 15 x 12cm over the postauricular region, i.e. 2cm posterior to the left ear, extending up to the mid-occipital region with its lower margin extending up to the middle of the neck. The skin over the swelling was stretched without any discoloration and there was no local rise of temperature (fig. 1 & fig. 2).

Neurological and physical examinations as well as laboratory investigations were normal. Fine-needle aspiration cytology was suggestive of lipoma. Ultrasonography revealed a heterogenous well-defined encapsulated lesion. On magnetic resonance imaging (MRI) it appeared as a mass with homogenous fat signal intensity surrounded by a pseudocapsule (fig. 3 & fig. 4).

As it was a giant lipoma, the surgery was performed under general anesthesia. The mass was well delineated and completely excised (fig. 5). The specimen weighed up to 750g and measured up to 14 x 9 x 6cm (fig. 6). Histopathological analysis of the resected mass revealed mature, proliferative lipocytes with no cellular atypia and it was diagnosed as benign giant lipoma.

Figure 1

Fig. 1: Benign lipoma of the postauricular region

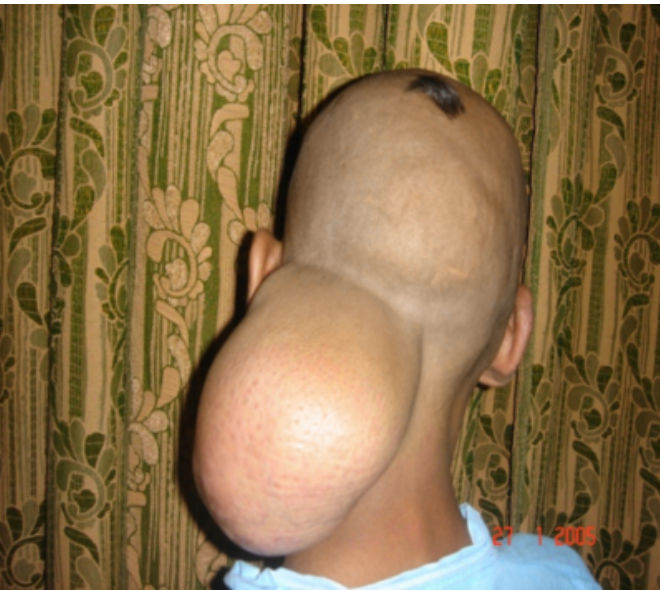

Figure 2

Fig. 2 Benign lipoma of the post auricular region

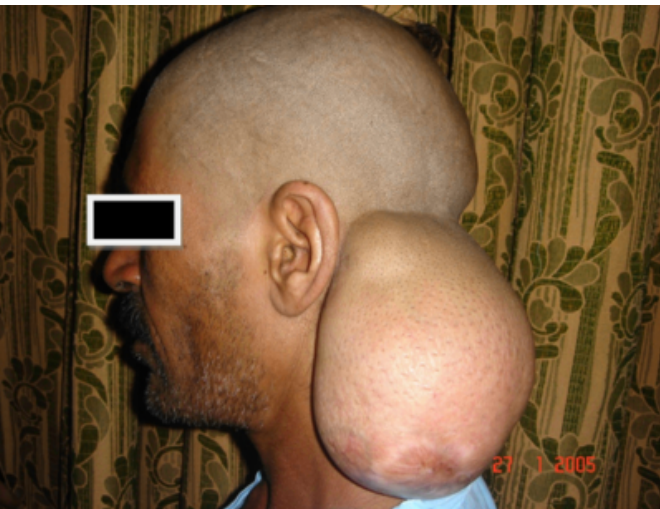

Figure 3

Fig. 3: Preoperative magnetic resonance imaging showing a large fatty mass in the postauricular region

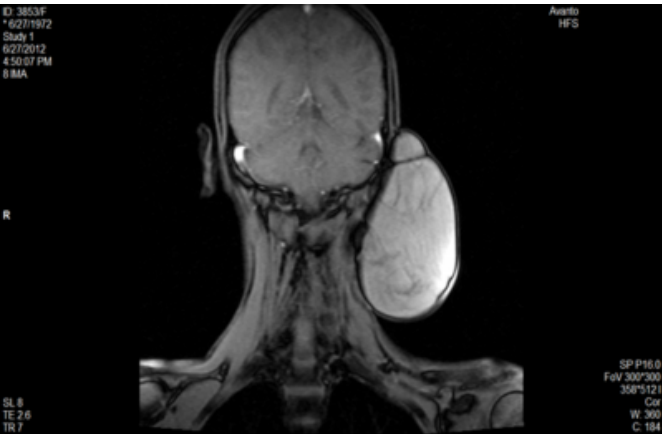


Figure 4

Fig. 4: Preoperative magnetic resonance imaging showing a large fatty mass in the postauricular region

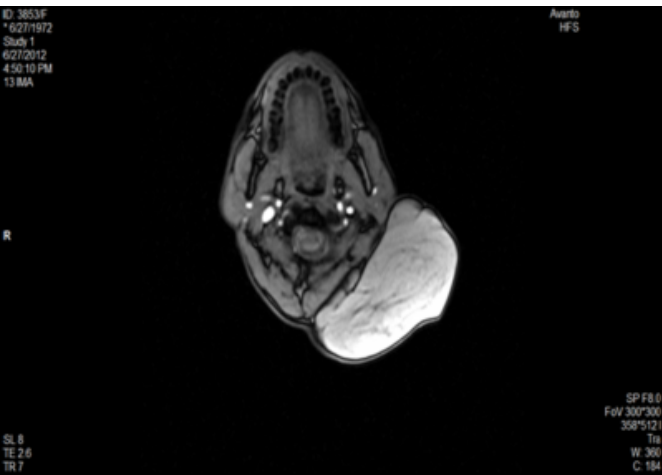


Figure 5

Fig. 5: Intraoperative image (excision)

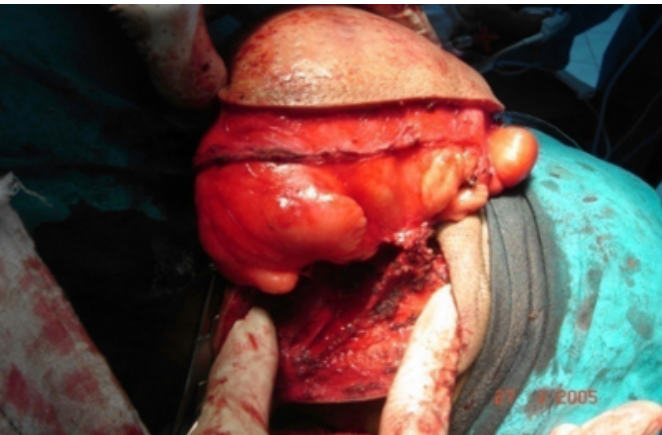
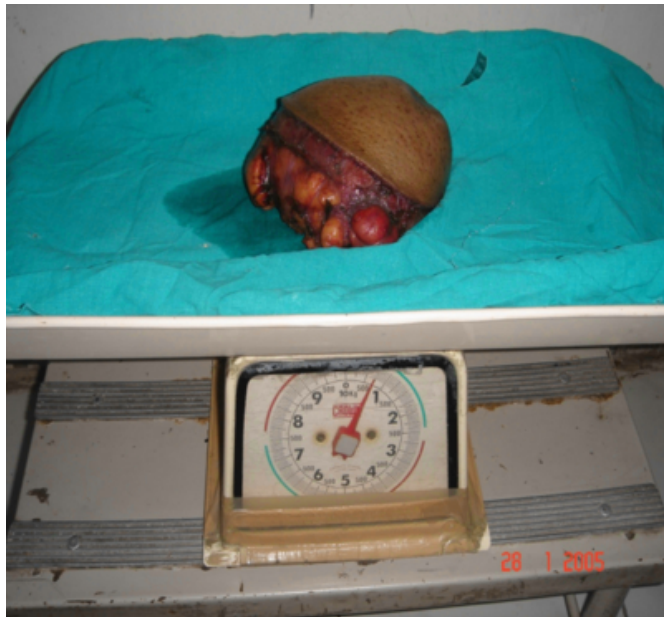
Figure 6

Fig. 6: Excised specimen



DISCUSSION

Most lipomas are small, weighing only a few grams². They are most frequent benign mesenchymal tumors with an estimated incidence of nearly 10%. A peak incidence of lipoma formation is noted in the fifth and sixth decade of life, and lipomas are more common in obese individuals⁷. There have been several reports of giant lipomas in the literature but the giant postauricular lipoma is a rare condition. They usually develop as well circumscribed encapsulated masses that have a doughy feel⁵. Benign fatty tumors may arise in any location in which fat is present, the majority occurring in the upper half of the body, particularly on the trunk, shoulder, posterior neck and axilla³. The occurrence on the head is relatively rare. Of those lipomas that occur in the head and neck region, the most common location is the posterior neck⁷.

The etiology of lipomas is unclear. They have been known to be sporadic, inherited, endocrine or dysmetabolic and genetic theories have been implicated. In recent years acute trauma has also been reported to be related to lipoma formation. They are believed to arise from primordial adipocytes, not from adult fat cells, therefore increasing in size as a patient accumulates adipose tissue, but not decreasing with weight loss. When located close to vital structures, giant lipomas may cause functional limitations on account of their excessive size and weight or lymphoedema, pain or nerve compression syndrome³.

Microscopically, the lesions show lobular growth of mature adipocytes with demarcated borders, a fibrous capsule and a central vacuole. Lipomas are classified into conventional lipomas, angiolipomas, fibrolipomas, spindle cell lipomas, pleomorphic lipomas, hibernomas, myelolipomas and atypical lipomas depending on their microscopic appearance. Lipomas are composed of physiologically distinct mature adipocytes; its lipids are not available for metabolic utilization. Conventional lipomas often show chromosomal rearrangements of 12q14-15, 6p and 13q9⁷.

They are associated with syndromes including hereditary multiple lipomatosis, Gardner's syndrome, Madelung's disease and Dercum's disease. The differential diagnoses include epidermal cysts, subcutaneous tumors, nodular fasciitis, liposarcomas, metastatic disease, erythema nodosum, nodular subcutaneous fat necrosis, vasculitic nodules, rheumatic nodules, sarcoidosis, infections and hematomas⁷.

On CT scans, lipomas have the typical characteristics of homogenous masses with few septations, a specific range of CT Hounsfield Unit (HU) values (usually between -50 and -150 HU), and they show no contrast enhancement. The margin of a lipoma is clearly defined by MRI as a "black-rim", enabling lipomas to be distinguished from the surrounding adipose tissue, a distinction that cannot be made from CT images⁶.

Recent rapid growth, size larger than 5cm and intramuscular location have all been reported to be risk factors for malignancy. MRI or biopsy are the two best options available. MRI scan is an excellent investigation for preoperative planning as it tells the details about the extent of tumor; also the homogeneous intensity of MRI indicates that the lesion is benign⁸. Proper management of giant lipoma is open excision. Lipomas are usually well encapsulated allowing relatively straightforward complete removal. Some of the most common complications from surgical excision include hematoma, ecchymosis, infection, deformity, damage to adjacent structures, excessive scarring and fat embolus. Recurrence after excision occurs in less than 5% of cases. Other modalities have been reported, ranging from liposuction to steroid injection⁷. Finally, histopathology of specimen determines the possible need for further management⁵.

Johnson et al. advised that any soft-tissue tumor lump which is greater than 5cm should be considered as malignant until proved otherwise⁸. In our case, the size was much more than

5cm but histopathology revealed no evidence of any malignant change.

CONCLUSION

Giant lipomas over the postauricular region are extremely rare. As they are occasionally capable of malignant behavior, MRI provides better information regarding tumor margin and further transformation to malignancy. Complete surgical excision is the treatment of choice.

References

1. Skomorac R: A benign giant lipoma of the posterior neck. *Medicinski Glasnik*; 2006; 3: 2.
2. Vandeweyer E, Scagnol I: Axillary giant lipoma. *Acta Chir Belg*; 2005; 105: 656-57.
3. Mazzocchi M, Onesti MG, Pasquini P, et al.: Giant fibrolipoma in the leg. *Anticancer Research*; 2006; 26: 3649-54.
4. Nigri G, Dente M, Valabrega S, et al.: Giant inframuscular lipoma disclosed 14 years after a blunt trauma. *J Med Case Rep*; 2008; 2: 318.
5. Allen B, Rader C, Babigian A: Giant lipomas of the upper extremity. *Can J Plast Surg*; 2007; 15(3): 141-4.
6. Verma S, Varma M, Kala S, Singh R: Giant lipoma of posterior neck with bleeding decubitus ulcer: a rare entity. *J Cutan Aesthet Surg*; 2010; 3: 119-21.
7. Medina CR, Schneider S, Mitra A, Spears J, Mitra A: Giant submental lipoma: case report and review of literature. *Can J Plast Surg*; 2007; 15: 219-22.
8. Kamath BJ, Kamath RK, Bhardwaj P, Shridhar, Sharma C: A giant lipoma in the hand - report of a rare case. *Online J Health Allied Scs*; 2006; 1: 6.

Author Information

Sangram Jadhav

Department Of General Surgery, Dr. D. Y. Patil Medical College & Hospital

Siddharth P. Dubhashi

Department Of General Surgery, Dr. D. Y. Patil Medical College & Hospital

Phani Kumar

Department Of General Surgery, Dr. D. Y. Patil Medical College & Hospital