

# Umbilical polyp in adulthood: A rare presentation

S Cheddie, B Singh

## Citation

S Cheddie, B Singh. *Umbilical polyp in adulthood: A rare presentation*. The Internet Journal of Surgery. 2012 Volume 28 Number 5.

## Abstract

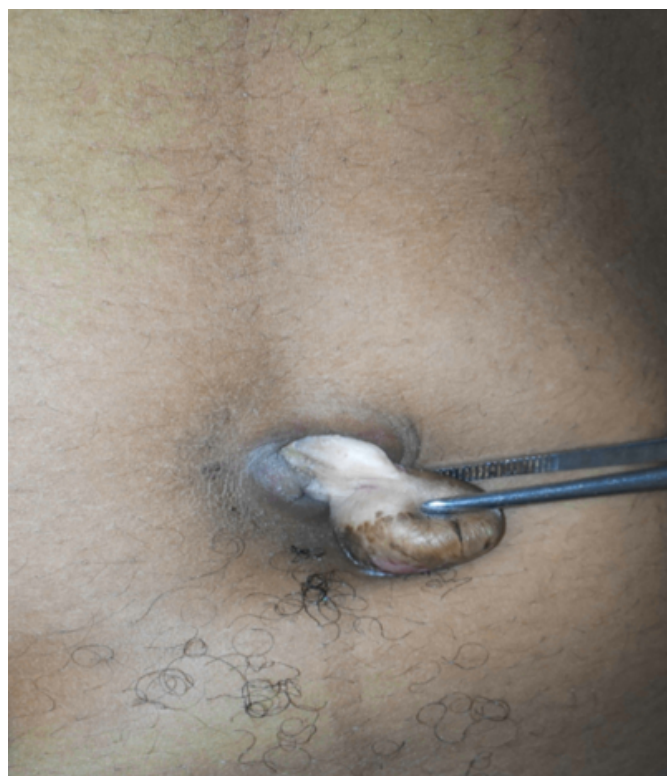Vitello-intestinal duct anomalies are rare and occur in 1-2% of the population. These anomalies may even present in adulthood with a spectrum of umbilical disorders that require surgical correction. We present a rare case of an umbilical polyp in a 25-year-old African female which was successfully resected surgically.

## CASE REPORT

A 25-year-old African female presented with an umbilical mass with an associated umbilical discharge from childhood. A CT abdomen showed no intra-abdominal communication. At surgery, an umbilical polyp was excised, the histology of which revealed columnar epithelium with villi formation suggesting small intestinal mucosa (fig. 1).

### Figure 1

Figure 1: Umbilical polyp with underlying stalk attached to the umbilicus



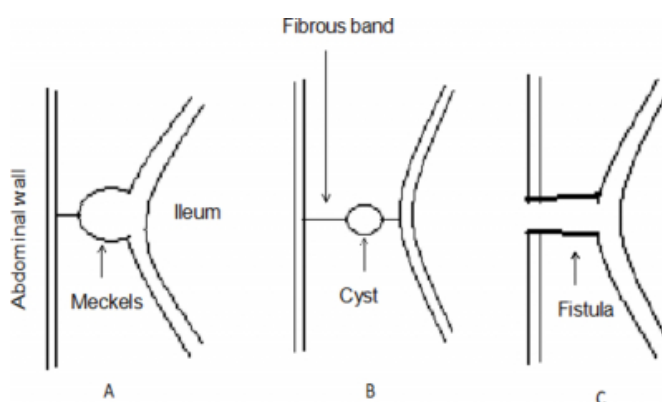
## DISCUSSION

The vitello-intestinal duct (VD) connects the embryonic yolk sac to the midgut and usually obliterates by the 8<sup>th</sup> week of gestation.<sup>1</sup> In 2% of the population, the duct may persist in varying degrees and present with a spectrum of congenital umbilical anomalies. The most common umbilical anomaly is the umbilical polyp which is often lined by small-bowel mucosa and less commonly, pancreatic and gastric mucosa.

Nix and Young classified the vitello-intestinal duct anomalies into four major categories: complete patent VD (umbilical enteric fistula); partially patent VD including peripheral portion (umbilical sinus), intermediate portion (vitelline cyst), and enteric portion (Meckel's diverticulum); mucosal remnant at the umbilicus (umbilical polyp); and congenital band (obliterated VD)<sup>2</sup> (fig. 2).

### Figure 2

Figure 2 (drawn by Cheddie S): A – Meckel's diverticulum with fibrous band; B – Vitelline cyst; C – Vitelline fistula



Umbilical polyps are generally regarded as innocuous but may be associated with other vitello-intestinal duct defects

such as underlying sinus, cyst, fistula, or band. When it is associated with other abnormalities, more complicated features, such as fecal fistula, infected cyst, or herniation of small bowel, may occur. The umbilical polyp may rarely arise from urachal remnants.<sup>3</sup>

Ultrasonography or computed tomography abdominal scans are recommended to exclude associated intra-abdominal anomalies. Surgical resection of the umbilical polyp is the treatment of choice; the extent of resection being guided by pre-operative imaging and intra-operative inspection of the base of the polyp. Patients should be consented for

laparotomy; however, routine exploration of the peritoneal cavity is unnecessary.<sup>4</sup>

### **References**

1. Sadler TW: Langman's Medical Embryology. 7th ed. USA: Williams and Wilkins, 1995:295-298
2. Nix TE, Jr., Young CJ: Congenital Umbilical Anomalies. Arch Dermatol; 1964; 90: 160-165.
3. You Y, Yang X, Hao F, Zhong B: The umbilical polyp: a report of two cases and review of the literature. Int J Dermatol; 2009; 48: 630-632
4. Pacilli M, Sebire NJ, Maritsi D, Kiely EM, Drake DP, Curry JJ, Pierro A: Umbilical polyp in infants and children. Eur J Paed Surg; 2007; 17: 397-9.

**Author Information**

**S. Cheddie, FCS(SA)**

King Edward VIII Hospital, Department of General Surgery, Nelson R Mandela School of Medicine, University of Kwa-Zulu Natal, South Africa

**B. Singh, FCS(SA) MD(Natal)**

King Edward VIII Hospital, Department of General Surgery, Nelson R Mandela School of Medicine, University of Kwa-Zulu Natal, South Africa