

T Tail Configuration Of Opsite On Suction Tubing Outlet For Modified Vacuum Assisted Closure.

S Ram, S Vijayan, A Kini

Citation

S Ram, S Vijayan, A Kini. *T Tail Configuration Of Opsite On Suction Tubing Outlet For Modified Vacuum Assisted Closure..* The Internet Journal of Plastic Surgery. 2012 Volume 8 Number 1.

Abstract

Many modified vacuum assisted closure methods have been proposed as an alternative to original VAC which are simple and cost-effective. M Singh et al has proposed the idea of a poor man's VAC (1-2). We would like to suggest few modifications in the methodology considering which will improve the efficiency of poor man's VAC. The port of exit of the suction tubing from the dressing remains a potential site of leakage. For the use of non electrical suction devices it is necessary to have complete leak proof dressing. Every attempt has to be made to minimize the leak. We recommend T- tailing of suction tubing which prevents leakage significantly from our experience.

INTRODUCTION

Many modified vacuum assisted closure methods have been proposed as an alternative to original VAC which are simple and cost-effective. M Singh et al has proposed the idea of a poor man's VAC (1-2). We would like to suggest few modifications in the methodology considering which will improve the efficiency of poor man's VAC. The port of exit of the suction tubing from the dressing remains a potential site of leakage. For the use of non electrical suction devices it is necessary to have complete leak proof dressing. Every attempt has to be made to minimize the leak. We recommend T- tailing of suction tubing which prevents leakage significantly from our experience.


METHODOLOGY

The opsite is applied in such a manner that the tubing is lifted one to two inches beyond the edge of the wound by the assistant, and the opsite is adhered to the whole circumference of the tubing and opposing beneath the suction tubing by the applicant in a key hole fashion creating an air tight seal towards the periphery. The "wings" of the opsite is adhered to the skin surface. Now the cross section appears a T shape (Figure 1). When this procedure is not performed there is always a chance of peritubal leak from the triangular dead space area tracking along the tubing into the wound especially when the opsite is stretched. This procedure prevents the leakage and the efficiency of modified VAC remains same for varying size of tubing. This process is similar to creation of witzel tube for feeding

jejunostomy.

Figure 1

Figure 1. (T tail configuration in different views)



ADVANTAGES

Avoids tunneling through the tissue as much as possible preventing the tissue damage and risk of spread of infection.

Change of tubing easily, frequently with every change of dressing

Avoiding pain and discomfort to the patient

Avoids unnecessary usage of adhesive plasters in attempt to sealing the leak.

It is easy, comfortable, cost-effective and decreases frequent monitoring for leakage.

Patients are relatively ambulant when the negative suction can be maintained through using 50 cc syringes and romovac

Though the leakage chances are more in regions involving ankle, groin, axilla, and uneven surfaces, pedal suction device with calibrated vacuum gauge can maintain for a longer period than usual.

Figure 2

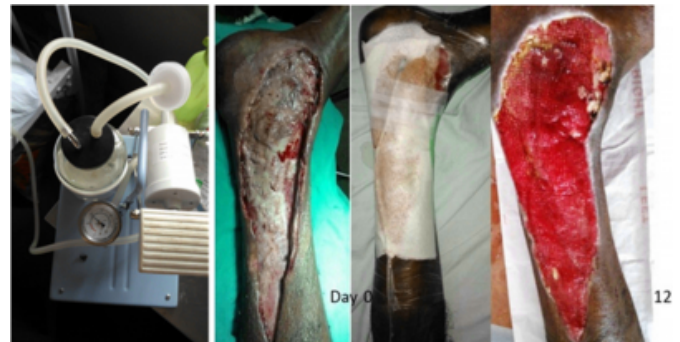
Figure 2: Measurement of negative pressure with suction gauge with syringe type, romovac and mucus sucker. The 50 cc syringe piston is held in position with a 20 cc syringe piston.



A standard 50cc syringe is able to create a maximum amount of 450 mm hg pressure. A standard romovac drain is able to create a negative pressure of 75 mm hg pressure and a mucus sucker produces a vacuum of similar amount. We have used infant feeding tube, ryle's tube and suction catheters as suction tubing's with good efficacy and these materials are readily available in government hospitals.

Figure 3

Figure 3: Wound healing after application of modified VAC with pedal suction.



It is beyond doubt the results are gratifying with poor man's VAC, we totally agree with the results. With the T- tailing the performance can be more enhanced in low resource setting. Wounds of extensive surface area is the limiting factor for poor man's VAC as there are multiple sites of leakage, hence may require a motorized suction device or central vacuum for maintaining the vacuum depending on the resource setting.

Vacuum dressing has to be done with great caution or avoided in peripheral vascular disease (3). Further studies regarding the microbial clearance rate, wound contraction time, bed occupancy, patient's compliance are required to formulate guidelines and standardize poor man's VAC. Simpler Low cost vacuum devices like these need to be encouraged, educated and improved with modifications which are user as well as patient friendly.

References

1. M. Singh, R. Singh, S. Singh, V. Pandey, D. Singh: Vacuum assisted Closure in wound management – Poor man's VAC©. The Internet Journal of Plastic Surgery. 2009;6(1).
2. Danu M, Rosadi S. The Simplest Modified Vacuum Assisted Closure to Treat Chronic Wound : Serial Case Report. Jurnal Plastik Rekonstruksi . 2012 :117-22.
3. Ahmad M, Malik SA. Vacuum Assisted Closure Therapy: Role in Modern Plastic Surgery. JLUMHS 2010; 9 (2):76-83.

Author Information

Shankar Ram, HS MBBS

Junior Resident, Department of General Surgery, Kasturba Medical College, Manipal University

Siddha K Loka Vijayan, MBBS

Junior Resident, Department of General Surgery, Kasturba Medical College, Manipal University

Anand Kini, MCh (Plastic)

Associate Professor, Department of General Surgery, Kasturba Medical College, Manipal University