

# Unusual Presentation Of A Lumbar Facet Joint Septic Arthritis Mimicking A Sports Injury: A Case Report

H Fawi, F Brooks, A Thomas, S Ahuja

## Citation

H Fawi, F Brooks, A Thomas, S Ahuja. *Unusual Presentation Of A Lumbar Facet Joint Septic Arthritis Mimicking A Sports Injury: A Case Report*. The Internet Journal of Spine Surgery. 2013 Volume 8 Number 1.

## Abstract

**Purpose:** To describe a case of Septic arthritis of lumbar facet joint with a very unusual presentation.

**Methods:** A detailed history, physical and radiological examinations were performed to diagnose and treat a case of a 20 years old patient who developed back pain after a squash game, which lasted for 3 weeks, with an episode of numbness below the waist lasting for a few days.

**Results:** There were no associated cardinal findings on examination or laboratory investigations, and MRI revealed Septic Arthritis of Lumbar Facet Joint (SALFJ) with epidural abscess. The patient was treated successfully with antibiotics.

**Conclusion:** Septic arthritis of lumbar facet joint is a very rare condition. This case report is to show that it can present with very unusual symptoms, so not to be missed.

## INTRODUCTION

A detailed history, physical and radiological examinations were performed to diagnose and treat a case of a 20 years old patient who developed back pain after a squash game, which lasted for 3 weeks, with an episode of numbness below the waist lasting for a few days.

## CASE REPORT

A 20 years old infanteer was referred by his unit's physiotherapist to our Spinal unit for assessment of a possible disc prolapse.

His symptoms started 3 weeks prior to admission after a squash game. After which he has been suffering with back pain, difficulty in walking, and bending. He had a few days duration of numbness below the waist bilaterally, which resolved spontaneously. This was not associated with any bowel or bladder disturbance.

He denied symptoms of fever or general malaise suggestive of sepsis.

On examination and throughout his hospital stay he remained afebrile. He was tender on the left paraspinal muscles side from L3-L5 region. He had power grade 4+ (MRC) on L2-L5 bilaterally. The rest of the examination

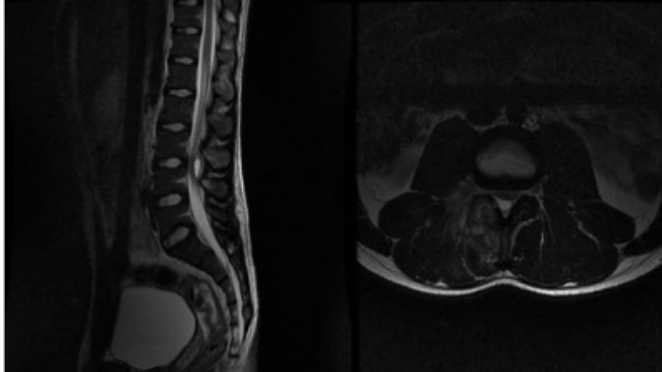
was unremarkable. Lumbar spine X-rays were normal.

Laboratory investigations revealed C-reactive protein (CRP) 11 (normal <6), Erythrocyte Sedimentation Rate (ESR) 46 (normal 1-10), and the White Blood Cells (WBC) were 9.9 (normal 4.0 – 10.5), Neutrophils 6.2 (normal 1.7 – 8). Blood cultures did not grow any organisms after 5 days incubation.

In view of his symptoms an inpatient MRI (a) was done, and it was reported as: Right L3/4 facet joint infection with a small epidural abscess extending posteriorly around the theca at and just below the level of the disc compressing the theca. There were evident inflammatory changes around the L3 nerve roots.

**Figure 1**

(a) T2 MRI scans of Sagittal and Axial views on presentation. Showing the inflammatory changes in the right L3/4 facet joint with a small epidural abscess extending posteriorly around the theca. There is inflammatory change around the L3 nerve root.



Local microbiologist was consulted and advised for a 6 weeks course of Clindamycin 300mg QDS PO and Ceftriaxone 1g IV OD. The latter was given via a Hickman line inserted specifically to facilitate patient's discharge and administration of the Ceftriaxone in the community by his GP. This was followed up by 2 weeks of Oral Clindamycin 300 mg QDS and Co-Amoxiclav 625mg TDS for 2 weeks.

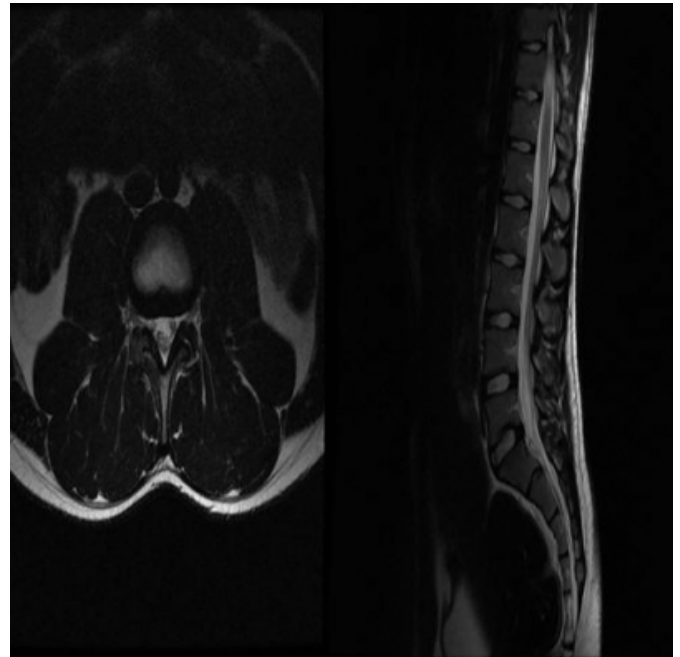
After 3 days of starting the antibiotics his symptoms had resolved completely.

Repeat laboratory test in 30 days showed his WBC 5.9, CRP <1, and ESR 2.

The patient was followed up regularly in clinic, and he remained asymptomatic. As his inflammatory markers were mildly elevated before diagnosis, and as his repeat investigations remained normal, we arranged a Lumbar spine X-ray which did not show any changes, and an MRI scan 12 weeks post presentation (b) that showed complete resolution with no residual inflammatory changes within the parafacetal soft tissues, as well as the previously seen epidural abscess has completely resolved.

**Figure 2**

(b) Repeat MRI scan 6 weeks after completion of antibiotics, and total of 12 weeks after first presentation. Shows complete resolution.



## DISCUSSION

Septic arthritis of Lumbar facet joint is a very rare infection. The first case report in English literature was by Halpin and Gibson (1) in 1987.

The incidence is between 0.2% - 4%.(2) Average age is reported to be 55 years.

SALFJ is usually of a haematogenous aetiology, but direct inoculation by epidural catheters, facet joint infiltrations, discectomies or spinal surgery has been reported (3).

Halpin and Gibson in their case report arising after back strain; suggested that a secondary effusion or haemarthrosis in a facet joint allowed its colonisation by bacteria. (1)

Typical presentation of lumbar facet joint septic arthritis is with acute onset of low back pain, not relieved with rest, and fever (4). Patients may have neurological deficit on presentation which could be caused by epidural abscess formation complicating 25% of the cases, and 38% might develop severe neurologic deficit for example Cauda equina syndrome (2).

Flexion to the contra lateral side usually aggravates the pain. Forceful hyperextension sharpens the pain, whereas flexion reduces it; lumbar motion is restricted in all directions, and the straight leg raise test increases the back pain. This is

similar to spondylodiscitis.

In comparison, SALFJ symptoms tend to be unilateral, present more acutely, with average duration before diagnosis of approximately 4 weeks compared to 3 months for spondylodiscitis (2).

White cells count is usually elevated in 50% of cases, and the ESR and the CRP are usually elevated in all cases.

Blood cultures are positive in 50% of cases. Staphylo coccus aureus is the most commonly reported causative organism. Other bacteria, such as streptococcus and gram negative rods, are reported less frequently (2,4).

Clinical and laboratory investigations are insufficient to diagnose septic arthritis of lumbar facet joints. Therefore imaging is required to help establish the diagnosis, and as well to evaluate the spread of infection.

Plain radiographs are of no value initially as it takes between 3 weeks and 3 months for bony abnormalities to become visible.

CT allows early diagnosis but Gadolinium-enhanced MRI is the imaging modality of choice. MRI is more sensitive than CT in detecting epidural abscess, and easily rules out differential diagnosis like spondylodiscitis (2,3).

SALFJ can be successfully managed conservatively with antibiotic therapy without surgical intervention. The latter is only indicated when there is neurologic dysfunction or when there is persistence of back pain and sepsis despite appropriate antibiotic therapy when immediate decompressive laminectomy might be indicated.(2)

The history of presenting illness of our presented case described in this report was suggestive of a possible

herniated lumbar disc rather than a differential diagnosis of SALFJ. His unusual presentation with no fever, and only one raised inflammatory marker (ESR) and mild raise in (CRP), without a clear source of infection, and the fact that he had subjective numbness below the waist for few days and pain localizing lateral to the spine; all these collectively were raising the suspicion of a localized pathology.

As the literature suggests that the investigation of choice is an MRI; this indeed helped us to establish the diagnosis in this rather unusual case.

The patient was managed conservatively with no residual deficit and full resolution of his findings.

The message from our case is to raise the awareness about Septic Arthritis of Lumbar Facet Joint (SALFJ), and to emphasize that if early effective treatment is commenced the outcomes are usually favorable.

It also raises an interesting fact that epidural abscess is not always caused by discitis, but clinical symptoms could be the same, and not only old patients or those immunosuppressed can develop epidural abscesses.

### **References**

- (1) Halpin DS, Gibson RD. Septic arthritis of a lumbar facet joint. J Bone Joint Surg 1987 ; 69-B : 457-459.
- (2) Muffoletto AJ, Ketonen LM, Mader JT et al. Hematogenous pyogenic facet joint infection. Spine 2001 ; 26 : 1570-1576.
- (3) Marson F, Cognard C, Guillem P et al. Arthrite septique interapophysaire postérieure lombaire avec abcès épidural et des parties molles paravertébrales. J Radiol 2001 ; 82 : 63-66.
- (4) Doita M, Nabeshima Y, Nishida K et al. Septic Arthritis Of Lumbar Facet Joints Without Predisposing Infection. J Spinal Discord Tech. 2007; 20: 290-5.

**Author Information**

**H.M.T. Fawi**

Welsh Spinal Surgery Unit, Trauma and Orthopaedics Directorate, University Hospital of Wales  
Wales, Great Brittan

**F. Brooks**

Welsh Spinal Surgery Unit, Trauma and Orthopaedics Directorate, University Hospital of Wales  
Wales, Great Brittan

**A.M. Thomas**

Welsh Spinal Surgery Unit, Trauma and Orthopaedics Directorate, University Hospital of Wales  
Wales, Great Brittan

**S. Ahuja**

Welsh Spinal Surgery Unit, Trauma and Orthopaedics Directorate, University Hospital of Wales  
Wales, Great Brittan