

Primary Ewings Sarcoma Of The Lumbar Spine Presenting As Cauda Equina Syndrome

R Shankar, A Rao, C Ballal, R Naik

Citation

R Shankar, A Rao, C Ballal, R Naik. *Primary Ewings Sarcoma Of The Lumbar Spine Presenting As Cauda Equina Syndrome*. The Internet Journal of Spine Surgery. 2012 Volume 6 Number 2.

Abstract

A 16 year old girl presented with low back ache and insidious progressive weakness of both lower limbs of 2 months duration with bilateral foot drop. She had bowel and bladder incontinence . MRI of Lumbo sacral spine showed lytic destruction with irregular soft tissue mass involving the spinous process L3 in to spinal canal and erector spinae muscles causing significant narrowing and extradural compression on the cauda equine (L3 4) roots. A CT guided FNAC was suggestive of PNET. She underwent L3,4 decompressive laminectomy with biopsy of tumor tissue. Immunohistochemistry showed CD 99 positivity suggestive of Ewings sarcoma. Postoperatively lower limb power improved. The patient has received chemotherapy but incontinence persisted.

INTRODUCTION

Primary Ewing's sarcoma of spine is very rare with poor prognosis. The ESFT (Ewings sarcoma family tumors) also comprises a skin tumor and PNET. The possibility of primary PNET should be considered in the pediatric age group with spinal tumors presenting as Cauda equine syndrome. Usual presentation is in second or third decade of Life. They present with local pain, gait disturbance, motor deficit, or sphincter dysfunction. Peripheral PNET (pNET) of spine refers to all those tumors arising from the surrounding soft tissues vertebra or spinal nerve roots. The mean period of postoperative survival ranges from 18 to 20 months from various reports and case series¹⁻⁵. Nearly one third of the spinal PNET present with Cauda equina Syndrome². So far 15 cases of spinal PNET have been reported presenting with Cauda equine syndrome^{1,3}. We report a case of Ewings Sarcoma emanating from L3 spinous process presenting as Cauda equina syndrome.

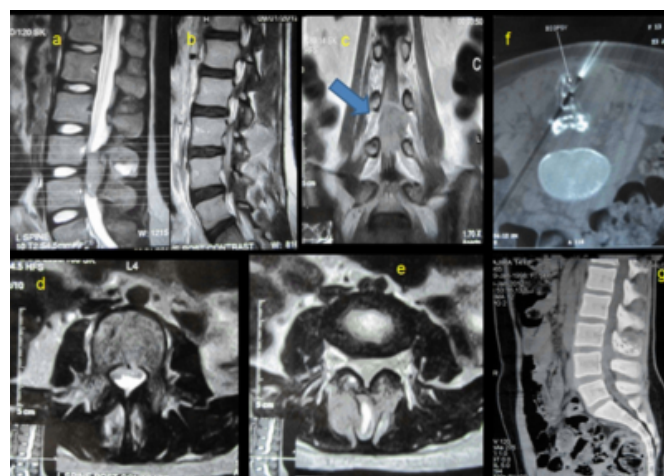
CASE

A 16 year old girl presented with low back ache and insidious progressive weakness of both lower limbs of 2 months duration with bilateral foot drop. She had bowel and bladder incontinence. There was no history of trauma, tuberculosis and constitutional symptoms. She was conscious oriented and her vitals were stable. No pallor, clubbing ,lymphadenopath or edema was present. Neurological examination showed bilateral lower limb

hypotonia, motor weakness grade 3/5 power around the hip and knee, sensory blunting (below L3 dermatome) with absent ankle and knee jerks. A diffuse tender area of fullness felt in the lower lumbar region more towards the right. Respiratory and cardiovascular systems were within normal limits. Blood investigations: Hb 11gm %, TLC-6800, N-55% L35% M6% E4 %,ESR -59, Plts 4.9, normal peripheral smear, LFT, RFT, Ca 9.2 , P-10.6, ALP- 187.

Figure 1

Figure 1 : MRI of LS spine showing extent of tumor and compressing the nerve roots (a-e).CT images of guided biopsy (f) and lytic destruction of L3 spinous process(g)

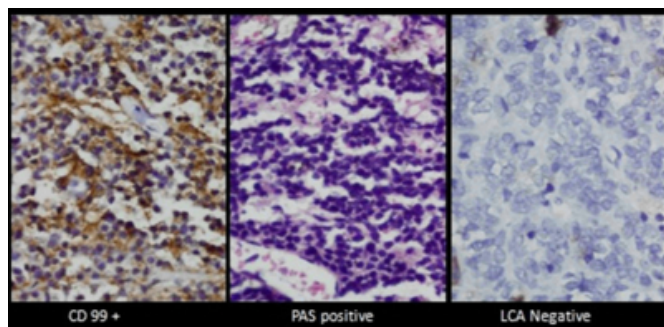


MRI of Lumbo sacral spine (Figure 1a-e) shows lytic destruction with irregular soft tissue mass involving the

spinous process L3 and lamina of L3 vertebra with extension in to spinal canal and erector spinae muscles causing significant narrowing and extradural compression on the cauda equine (L3 4) roots. The soft tissue lesion appear hypointense on T1W images and heterogeneously hyperintense on T2W images On post contrast images there is uniform enhancement. CXR, CT Brain and USG abdomen was normal. Further investigation by CT guided biopsy from L3 spinous process (figure 1f,g) revealed the possibility of PNET.

Figure 2

Figure 2: Immunohistochemistry shows CD 99 positivity



She underwent L3,4 decompressive laminectomy with debulking of majority of the tumor tissue. Intraoperatively; superficially seen necrotic pultaceous with hard solid component was curetted between L3 and L4 spaces. The dura was not infiltrated. Microscopic appearance showed highly cellular tumor predominantly composed of sheets of uniform round cells with scanty cytoplasm. The tumor islands are separated by fibrous stroma. Areas of necrosis were also seen. The tumor infiltrated the fibrous tissue and bone. Immunohistochemistry showed PAS positivity, LCA was negative and CD 99 was positive.

Postoperatively dorsi and plantar flexion improved with bilateral lower limb power to 4/5. She was started on alternating cycles VAC (Vincristine Adriamycin

Cyclophosphamide) with (IE) Etoposide and Ifosfamide and is on follow up. However incontinence persisted after 2 months of follow-up.

DISCUSSION

Primary Ewing's sarcoma of spine has male preponderance with posterior elements of the spine are commonly involved and are mostly extradural and extramedullary. The incidence in the sacrum is rare compared to other parts of the spine with equal distribution. Complete Surgical resection is difficult most of the times. Distant metastasis is seen in 38 % cases commonest being the lungs. They are CD 99 positive and associated with t (11, 22) translocation⁶. These highly aggressive tumors warrant high index of suspicion and prompt tissue diagnosis with surgical intervention at the earliest and chemotherapy. Also there are no definite guidelines for optimal management. The prognosis remains poor with local recurrences and systemic complications with survival in the range of months to couple of years. Multimodal treatment offers hope of longterm and good quality survival.

References

1. Dhath S, Dhillon MS, Tripathy SK, Goyal T, Jagadeesh V. Peripheral primitive neuroectodermal tumor causing cauda equina syndrome with destruction of L5 vertebra. *Indian J Orthop* 2010;44:339-41
2. Jithendra K S, rachna S, karak AK, Thavaraj V, Kabra SK. Primitive Neuroectodermal Tumor presenting as Cauda equine syndrome. *Indian J Med and Paediatr Oncol* 2007;28:34-37
3. Krishnakumar R, Renjitkumar J. Acute cauda equina syndrome due to primary Ewing's sarcoma of the spine. *Neurol India* 2011;59:931-3
4. Goel D, Singhal A, Gupta C, Kishor S, Anuradha K. Acute presentation of epidural Ewing's sarcoma. *J Pediatr Neurosci* 2007;2:18-9
5. Jia L, Li G, You C, He M, Ye F. Intramedullary ewings Sarcoma of the spinal cord associated with Hydrocephalus. *Neurol India* 2009;57:628-9
6. Saeedinia S, Nouri M, Alimohammadi M, Moradi H, Amjirjamshidi A. Primary spinal extradural Ewings sarcoma(PNET); Report of a case and meta analysis of the reported cases in the literature. *Surg Neurol Int* 2012 :3:55

Author Information

Ram HS Shankar

Junior Resident, Department of General Surgery, Kasturba Medical College . Manipal University

A Divaker Rao

Professor, Dept of Neurosurgery, Kasturba Medical College . Manipal University

Chandra Kumar Ballal

Professor, Dept of Neurosurgery, Kasturba Medical College . Manipal University

Ramdas Naik

Professor, Department of Pathology, Kasturba Medical College . Manipal University