

Oral Ranula: An Insight Into Paediatric Dentistry.

B Godhi, N Agarwal, P Verma, S Kumar

Citation

B Godhi, N Agarwal, P Verma, S Kumar. *Oral Ranula: An Insight Into Paediatric Dentistry.*. The Internet Journal of Dental Science. 2013 Volume 11 Number 1.

Abstract

Oral ranula is a retention cyst arising from the sublingual gland on the floor of the mouth as a result of ductal obstruction and fluid retention. There are various techniques to manage ranula in the literature. There is no doubt that excision of the offending sublingual gland will cure all ranulas. Still, some surgeons prefer to initially treat ranulas by marsupialization, perhaps because of the potential surgical complications when removing the sublingual gland, most notably injury to the lingual nerve, injury to Wharton's duct with the possibility of stenosis leading to obstructive sialadenitis, and ductal laceration causing salivary leakage. This paper highlights a case report of ranula in the floor of the mouth which was less than 2cm and has been successfully treated by marsupialization .

INTRODUCTION

Oral ranulas are cystic lesions located on the floor of the mouth that arise from obstruction of the excretory duct of the sublingual gland. It is formed by rupture of excretory duct followed by extravasation of the mucus and accumulation of saliva into the surrounding tissue which forms a pseudo cyst that lacks the epithelial lining (1). There are many methods in the literature for the treatment of ranulas including excision of the ranula only, excision of the ranula and the ipsilateral sublingual gland, marsupialisation and cryosurgery(2, 3), but the two widely practiced techniques are marsupialisation i.e unroofing of cyst (2) and sublingual gland excision. Recent studies have shown that surgical excision of the ranula along with the sublingual gland excision is a standard method of treatment. By doing these technique there is a risk of damaging the surrounding anatomical structures like lingual nerve and submandibular duct, which are close to the sublingual gland (4). Hence marsupialisation is still practiced to avoid injury to the surrounding anatomical structures, despite of reported recurrence rates of 61 to 89% (5) . Here with presenting a case report of oral ranula and its management in 11 year old male patient.

REVIEW OF THE LITERATURE

Ranula was reported by Hippocrates and Celsius (6). Ranula is derived from the Latin word 'rana' which means "frog", because this lesions in the floor of the mouth resemble the bulging underbelly of a frog (7). Oral ranula is an infrequent pathology (8,9), usually occurring in children and

adolescents. (9-13)

In the literature there are various studies on ranula, specific to children aged between 0-15 years (Table 1). Gul et al.(12) estimate the incidence of congenital ranula as 0.74%. Oral ranulas are most prevalent in females(8,19,21). According to the literature,(11,20,21) the most common site of oral ranula is on the left side of the floor of the mouth. Oral ranulas ranges from 0.5 to 3.3 cm. in diameter (4, 22). Ranulas are generally asymptomatic, although large ranula can cause aesthetic and functional problems (4, 22).

Figure 1

Table 1: Comparison of various studies on ranula in children

Author	Year	Sex		Age	Location
		Female	Male		
Baummaush (36)	2002	-	-	>10 years	-
Morita et al. (14)	2003	5	4	6-9 years	-
Haberal et al. (16)	2004	12	4	17days-14 years	-
Yuca et al. (11)	2005	6	3	7-15 years	left
Lee et al. (17)	2006	8	5	6-15 years	Right
Zola et al. (37)	2006	1	-	12 years	Left
Garofalo (9)	2007	9	9	2months-15 years	-
Chidzonga et al.(19)	2007	47	36	0-10 years	left
Zhi et al. (8)	2008	6	5	3days-3months	-

There are various methods of treating oral ranula. Garofalo S et.al (9) evaluated the effectiveness of orally administered Nickel Gluconate-Mercurius Heel-Potentised Swine Organ Preparations D10/D30/D200, a homo-toxicological agent and concluded that medication acts to stimulate pseudocyst re- absorption and glandular repair and also aids in

improving the physiologic functioning of the gland.

Surgically ranula can be treated by excision of the cyst with or without excision of the ipsilateral sublingual gland, marsupialization, cryosurgery, CO2 laser excision and radiotherapy. Spontaneous resolution may be another option for paediatric population. If the lesion does not resolve after 6 months of observation then, surgical treatment is recommended (23).

Sublingual gland excision removes the source of the mucus and thus significantly decreases the risk of recurrence (23), but there are associated complication with surgical excision of ranula like injury to Wharton's duct, obstruction of the sublingual gland, lingual nerve injury, sensory impairment of the tongue, recurrence and the development of a cervical ranula (Table 2)(4,18,22).

Figure 2

Table 2: Complication rates associated with procedures for treatment of ranula (8, 12)

COMPLICATIONS	SURGICAL PROCEDURES				TOTAL
	Marsupialization	Excision of ranula	Excision of sublingual gland	Excision of sublingual gland and ranula.	
Damage of Wharton duct	0(0%)	0 (0%)	5 (1.40%)	6 (2.82%)	11 (1.82%)
Bleeding or hematoma	0 (0%)	0 (0%)	1 (0.28%)	4 (1.88%)	5 (0.83%)
Dehiscence of wound	0 (0%)	0 (0%)	3 (0.84%)	3 (1.41%)	6 (0.99%)
Postoperative infection	0 (0%)	0 (0%)	1 (0.28%)	4 (1.88%)	5(0.83%)
Numbness of tongue	0 (0%)	1 (3.85%)	6 (2.10%)	15 (11.63%)	22(4.89%)
Recurrence	6 (66.67%)	15 (57.69%)	3 (1.05%)	2 (1.55%)	26(5.78%)

Carbon dioxide laser is used in limited patients where there is good success to remove the cyst (24). Radiation therapy is done in patient who cannot tolerate surgery. Low doses, from 20-25 grays (Gy), are effective (25).

Marsupialisation is the oldest and most widely reported treatment for ranula. Though marsupialization is not in favour because of excessive failures, a high recurrence rate [anywhere from 61% to 89%, as reported in the literature] (5) and the high incidence of iatrogenically caused cervical ranula (26), is still used to avoid potential surgical injury to adjacent structures when removing the sublingual gland.

Marsupialisation involves 'unroofing' the cyst and tacking the edges of the cyst to adjacent tissue with the placement of a silk suture or seton into the dome of the cyst under local anaesthesia (2). This is left in place while an epithelial tract forms, to allow for mucus drainage between the surface and

the underlying salivary glandular tissue. Packing the cyst cavity with gauze for 7 - 10 days also improves the success rate. With the simple addition of packing the entire pseudocystic cavity with gauze after its unroofing, the rate of recurrence is minimized. Baurmash HD has recommended that oral ranula can be treated initially by marsupialization with packing and, if there is recurrence, then the offending sublingual gland should be excised(26). Alternatively sclerosing agents such as Bleomycin and OK-432 can be used to increase the success in treatment (15) Keqian Zhi et.al have reported two infant patients treated by marsupialization showed no recurrence of lesion with follow-up 24 months (27).

Complete removal of a ranula is technically very difficult to achieve as it involves an extremely fine mucosa that will usually rupture on excision. Among the various surgical procedures, marsupilization has no complication associated except for higher recurrence rate. Here with presenting a case report of oral ranula in 11 year old boy who is treated with marsupilization considering it as the most ideal treatment for ranula (23).

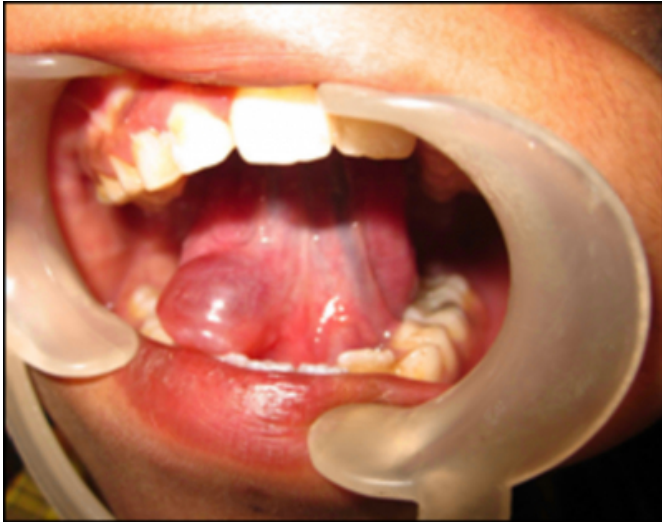CASE REPORT

An 11 year old boy reported to the Department of Pedodontics and Preventive Dentistry ITS-CDSR, Muradnagar, Ghaziabad with the chief complaint of a painless swelling below the tongue on the right side of the oral cavity for the past 4 months. The swelling started about 4 months back and increased gradually to attain its present size. There was no history of pain, but the patient had difficulty in speech, mastication and swallowing.

On examination, a 1.5 x 2cm dome-shaped, fluctuant swelling was seen in the floor of the mouth on the right side (Figure 1) swelling was seen attached to the right ventral surface of the tongue. The submucosal swelling was painless and fluctuant on palpation.

Figure 3

Figure: 1 Pre operative photograph



Aspiration biopsy yielded thick, viscous fluid and histopathological examination (HPE) revealed it to be mucous. Based on the aspiration & clinical findings the swelling was provisionally diagnosed as ranula. Other hematological and biochemical investigations including Complete Blood Count (CBC), Erythrocyte Sedimentation Rate (ESR) were all within normal limits. Chest x-ray was normal. After routine preoperative investigations, as the size of the cyst was small (< 2 cm) and it was superficial in nature, a conservative approach of marsupialization of ranula was planned. Local anaesthesia was given. The marking of the cystic swelling of the ranula was done by tacking the edges of the cyst to adjacent surrounding mucosa with resorbable suture, followed by de-roofing of the cystic lesion. The cavity which resulted from marsupialization was packed with betadine gauze (10% povidine –iodine topical antiseptic solution) and the pack size was gradually cut short as per the obliteration of the defect. The patient had an uneventful postoperative course and fully recovered. A tissue was sent to HPE for confirmation. HPE report confirmed the specimen to be ranula (Figure 2a, 2b,2c,2d). The case was followed up for 18 months at bimonthly interval. There is no reoccurrence of the lesion (Figure 3). Patient is still under follow up.

Figure 4

Figure 2a: Marking of cystic wall; Figure 2b: De-roofing; Figure 2c: Specimen; Figure 2d: Signs of healing after one week of marsupialization

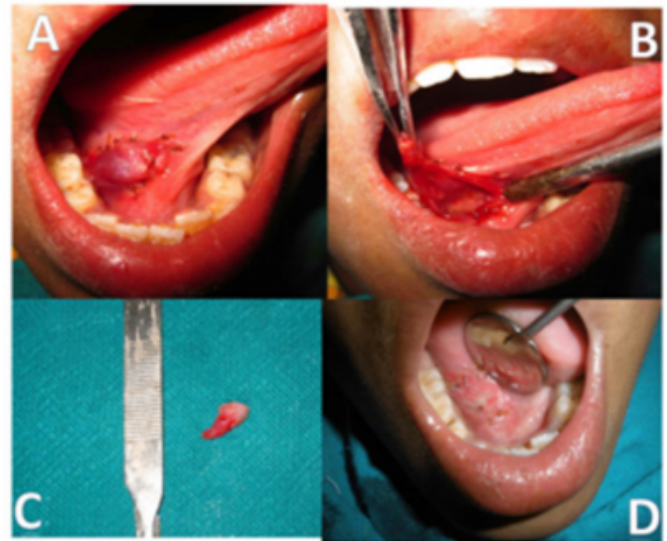
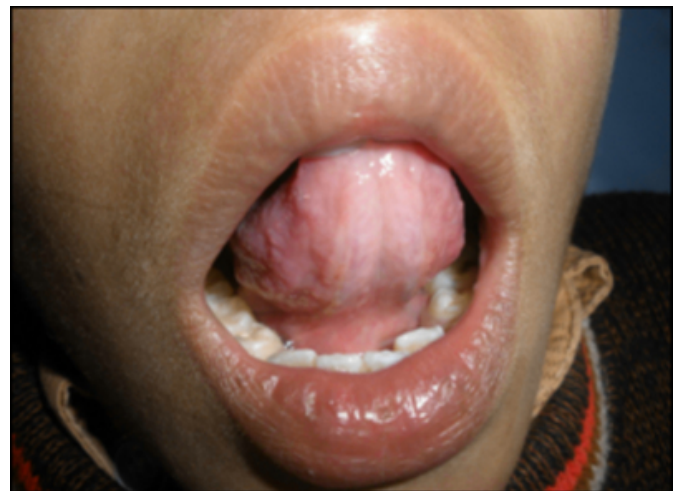

Figure 5

Figure 3: Post operative follow up of 18 months



DISCUSSION

Obstruction of excretory ducts or extravasations and subsequent accumulation of saliva from the sublingual gland in the tissue are responsible for the formation of ranulas (28-31).

Ranula is formed from one of the two processes:

Partial obstruction of a sublingual duct can lead to formation of an epithelial-lined retention cyst which is unusual, occurring in less than 10% of all ranula

Trauma can lead to formation of ranula. If a duct is obstructed, there is build up of secretory back-pressure leading to salivary duct rupture with mucus being forced into the surrounding tissues. Alternatively, trauma causes direct damage to the duct or acini, leading to mucus extravasation and forms a pseudocyst.

Based on the formation ranula can be classified into two groups, simple (intraoral) and the plunging (cervical) type. Simple ranulas are more common than plunging type. A simple ranula are formed by localized collection of mucus within the floor of the mouth and may arise from the submandibular duct or from the body of the sublingual gland (32). In plunging ranula, ranulas will attain sufficient fluid pressure as to herniate through the mylohyoid muscle and produce swelling within the neck (33, 34,38).

Differential diagnosis of ranula should include dermoid cyst, teratid cyst, lymphangioma, mucocele of the minor salivary gland, lymphoma and HIV- related lymphadenopathy. CT and MRI imaging studies can be helpful in supporting a diagnosis of and in determining the origin of the lesion (34).

With this literature background marsupialization was opted as treatment choice in our case as this technique is simple, conservative and is not associated with damage to the important anatomic structures in this location (20). With the simple addition of packing the entire pseudocystic cavity with betadine soaked gauze after the deroofting of the cystic lesion, the rate of recurrence is minimized (26). Also, there is enough documentation to support this technique as treatment of choice (7). There is a need to do marsupialization for several times to resolve a large ranula. If ranula in oral cavity does not resolve after marsupialization, then surgical removal of the sublingual gland and pseudo cyst is recommended.

CONCLUSION

Though sublingual gland excision is considered as the most effective treatment for ranula, in children this procedure is very difficult as it involves an extremely fine mucosa that may rupture on excision also there is risk of injury to the lingual nerve and sublingual duct. Hence marsupialization is suitable and effective treatment for intraoral ranula (<2 cm) in children.

References

1. S.L. Bronstein, M.S.Clark. Sublingual gland salivary fistula and sialoceles. *Oral Surg*;1984;57: 357- 61
2. R.P. Morton, J.R. Bartley. Simple sublingual ranula pathogenesis and management. *J. Otolaryngol*; 1995; 24:

- 253- 54.
3. Y. Yoshimura, S. Obara, T. Kondoh, S. Naitoh. A comparison of three methods used for treatment of ranula. *J. Oral Maxillofac. Surg*; 1995; 53: 280-82.
4. Baurmash HD . A case against sublingual gland removal as primary treatment of ranulas. *J Oral Maxillofac Surg*; 2007; 65:117-21.
5. Joseph CA, Davidge-Pitts KJ. Mucous extravasation cysts of the head and neck. *S Afr J Surg*; 1985; 23:95.
6. C.A. Quick, S.H. Lowell. Ranula and sublingual salivary glands. *Arch. Otolaryngol*; 1977; 103:397- 400.
7. W.S. Crysdale, J.D. Mendelsohn, S. Conley. Ranulas mucoceles of the oral cavity- experience in children. *Laryngoscope*; 1988; 98: 296-98.
8. Zhi K, Wen Y, Ren W, Zhang Y. Management of infant ranula. *Int J Pediatr Otorhinolaryngol*; 2008; 72:823-26.
9. Garofalo S, Briganti V, Cavallaro S, Pepe E, Prete M, Suteu L, et al.. Nickel Gluconate-Mercurius Heel-Potentised Swine Organ Preparations: a new therapeutical approach for the primary treatment of pediatric ranula and intraoral mucocele. *Int J Pediatr Otorhinolaryngol*; 2007; 71:247-55.
10. Onderoglu L, Saygan-Karamürsel B, Deren O, Bozdog G, Tekşam O, Tekinalp G. Prenatal diagnosis of ranula at 21 weeks of gestation: Ultrasound Obstet Gynecol. 2003;22:399-401.
11. Yuca K, Bayram I, Cankaya H, Caksen H, Kiroğlu AF, Kiriş M. Pediatric intraoral ranulas:-an analysis of nine cases. *Tohoku J Exp Med*; 2005;205:151-55.
12. Gul A, Gungorduk K, Yildirim G, Gedikbasi A, Ceylan Y. Prenatal diagnosis and management of a ranula. *J Obstet Gynaecol Res*; 2008; 34:262-65.
13. Zhao YF, Jia Y, Chen XM, Zhang WF. Clinical review of 580 ranulas. *Oral Surg Oral Med Oral Pathol Oral Radiol Endod*; 2004; 98:281-87.
14. Morita Y, Sato K, Kawana M, Takahasi S, Ikarashi F. Treatment of ranula-excision of the sublingual gland versus marsupialization. *Auris Nasus Larynx*; 2003; 30:311-14.
15. Roh JL. Primary treatment of ranula with intracystic injection of OK-432. *Laryngoscope*; 2006; 116:169-72.
16. Haberal I, Göçmen H, Samim E. Surgical management of pediatric ranula. *Int J Pediatr Otorhinolaryngol*; 2004; 68:161-63.
17. Lee HM, Lim HW, Kang HJ, Chae SW, Hwang SJ, Jung KY, et al. . Treatment of ranula in pediatric patients with intralesional injection of OK-432. *Laryngoscope*; 2006; 116:966-69.
18. McGurk M, Eyeson J, Thomas B, Harrison JD. Conservative treatment of oral ranula by excision with minimal excision of the sublingual gland-histological support for a traumatic etiology. *J Oral Maxillofac Surg*; 2008; 66:2050-57.
19. Chidzonga MM, Mahomva L. Ranula-experience with 83 cases in Zimbabwe. *J Oral Maxillofac Surg*; 2007; 65:79-82.
20. Y.F. Zhao, J. Jia, Y. Jia . Complications associated with surgical management of ranulas. *J. Oral Maxillofac. Surg*; 2005; 63 (1): 51-54.
21. Cristina Bonet-Coloma , Ignacio Minguez-Martinez , Amparo Aloy-Prósper , Sonnica Galán-Gil , Mary Peñarrocha-Diago , Juan-Manuel Mínguez-Sanz . Pediatric oral ranula: Clinical follow-up study of 57 cases. *Med Oral Patol Oral Cir Bucal*; 2011; 16 (2):158-62.
22. McGurk M: Management of the ranula. *J Oral Maxillofac Surg*; 2007;65:115-16.
23. R.T. Pandit, A.H. Park. Management of pediatric ranula. *Otolaryngol. Head Neck Surg*;2002; 127 (1): 115-18.
24. Mintz S, Barak S, Horowitz I. Carbon dioxide laser excision and vaporization of nonplunging ranulas: a

comparison of two treatment protocols. *J Oral Maxillofac Surg*; 1994; 52(4):370-72.

25. Shimm DS, Berk FK, Tilsner TJ. Low-dose radiation therapy for benign salivary disorders. *Am J Clin Oncol*; 1992; 15(1):76-78.

26. Baurmash HD. Marsupialization for treatment of oral ranula: a second look at the procedure. *J Oral Maxillofac Surg*; 1992; 50(12):1274-76

27. Keqian Zhi, Yumin Wen, Wenhao Ren, Yincheng Zhang. Management of infant ranula. *International Journal of Pediatric Otorhinolaryngology*; 2008; 72: 823-26.

28. Catone GA, Merrill RG, Henny FA. Sublingual gland mucusescape phenomenon—treatment by excision of sublingual gland. *J Oral Surg*; 1969; 27:774-786.

29. Regezi JA, Sciubba JJ. Oral pathology, clinical pathologic correlations. 3rd ed. Philadelphia: WB Saunders Company; 1999. p. 220-2.

30. Lida S, Kogo M, Tominaga G, Matsuya T. Plunging ranula as a complication of intraoral removal of a submandibular sialolith. *Brit J Oral Maxillofac Surg*; 2001; 39:214-16.

31. Balakrishnan A, Ford GR, Bailey CM. Plunging ranula

following bilateral submandibular duct transposition. *J Laryngol Otol*; 1991; 105:667-69.

32. Galloway RH, Gross PD, Thompson SH et.al. Pathogenesis and treatment of ranula: report of three cases. *J Oral Maxillofac Surg*; 1989; 47: 299-302.

33. Davison MJ, Morton RP, Mc Ivor NP. Plunging ranula- Clinical observations. *Head neck*; 1998; 20: 63-68.

34. Mahaddevan M, Vasan N. Management of pediatric plunging ranula. *Int J pediatr otolaryngol*; 2006; 70: 1049-54.

35. Kurabayashi T, Ida M, Yasumoto M et.al. MRI of ranulas. *Neuro radiology*; 2000; 42: 917- 20.

36. Baurmash HD. Treating oral ranula: another case against blanket removal of the sublingual gland. *Br J Oral Maxillofac Surg*; 2001; 39:217-20.

37. Zola M, Rosenberg D, Anakwa K. Treatment of a ranula using an Er,Cr:YSGG laser. *J Oral Maxillofac Surg*; 2006; 64:823-27.

38. Arunachalam P and Priyadarshini N. Recurrent plunging ranula *J Indian Assoc Pediatr Surg*. 2010 Jan-Mar; 15(1): 36–38.

Author Information

Brinda Godhi, MDS

Lecturer, Department of Pedodontics and Preventive Dentistry, J.S.S Dental College & Hospital

Nidhi Agarwal, M.D.S

Professor, Department of Oral and Pedodontics & Preventive Dentistry, I.T.S – Centre for Dental Studies & Research

Priya Verma, M.D.S

Reader, Department of Pedodontics & Preventive Dentistry, I.T.S – Centre for Dental Studies & Research

Shruti S Kumar, MDS

Lecturer, Department of Pedodontics and Preventive Dentistry, J.S.S Dental College & Hospital, JSS University