

Neuromyotonia (Isaacs' Syndrome) In A Patient With Shistosomiasis With Good Response To Plasmapheresis: A Case Report

I Ibrahim, D Abdelzahir, A Mostafa, O Mansour

Citation

I Ibrahim, D Abdelzahir, A Mostafa, O Mansour. *Neuromyotonia (Isaacs' Syndrome) In A Patient With Shistosomiasis With Good Response To Plasmapheresis: A Case Report*. The Internet Journal of Interventional Medicine. 2013 Volume 2 Number 1.

Abstract

Isaacs' syndrome is a rare disorder characterized by hyperexcitability of peripheral motor nerves. The cardinal features consist of myokymia, pseudomyotonia and contracture of hands and feet. The diagnosis of Isaacs' syndrome is based on the clinical features and classic electromyographic findings. Serum antibodies against Voltage-Gated Potassium Channels (VGKCs) are detected in some cases. Our 61 years old patient presented with generalized stiffness, more in the upper limbs associated with fasciculations, muscle cramps, carpopedal spasm and attacks of sweating. Patient also reported paresthesia of both hands. Muscles were in a state of contraction, myokymia and carpopedal spasm with no clinical myotonia. Electromyography showed classical neuromyotonic and myokymic discharges. The investigations for conditions associated with Isaacs' syndrome were done excluding most of the causes. Association between Shistosomiasis and Isaac's syndrome is rare, yet reported in literature. VGKCs antibody were not performed. Treatment with Plasmapheresis resulted in substantial improvement of the symptoms.

CASE REPORT

A 61 years old male patient, farmer from Abo Humos, married with 7 offspring, presented with subacute onset, progressive course of painful spasms of the right upper limb since 1 year (Distal more than proximal) with no precipitating factor that progressed to stiffness of the right upper limb. The condition progressed to involve the left upper limb within 3 months in the form of stiffness and frequent spasms followed by the trunk and the paraspinal muscles, and lastly the lower limbs were affected since 4 months.

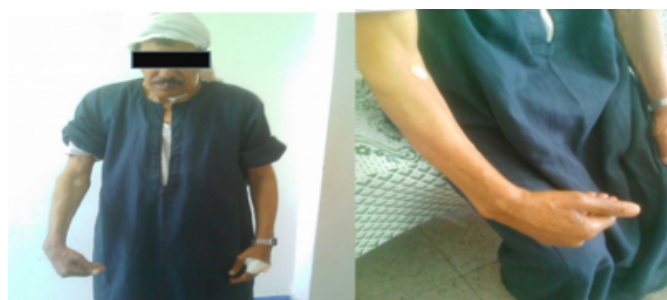The patient developed fasciculations through the course of the illness. It was generalized, spontaneous and involving the eyelids, face, upper and lower limb. Recurrent attacks of muscle cramps were of daily frequency mainly involving the upper limbs. Increase sweating was also reported by the patient. He complained of mild paraesthesia involving both upper limbs. No bulbar, sphincteric or cognitive manifestations and no constitutional manifestations or weight loss was seen. No past history of DM or hypertension was found. The patient had a history of Bilharziasis since 50 years, for which he received tartar emetic. The patient had

also a history of oral lesions since 5 years that recurred after surgical intervention. Family History and Drug History were negative.

General examination revealed average body built with stiffness of both hands (Fig 1). Consciousness and MSE were normal. Head and Neck examination was normal except for a submandibular lymph node. Gait was in short steps due to stiffness of the lower limb. Speech and articulation were normal. Cranial nerve examination only showed tongue wasting and fasciculations. Motor examination revealed average muscle status with no wasting. Stiffness all over more in the upper limbs and more distally was found. There was no weakness and the patient showed spontaneous gross fasciculations in both upper and lower limbs and in the face over the masseter muscle and around the eye. Sensory examination revealed short glove and stocking hypoesthesia. Coordination was normal and plantar reflex was flexor bilaterally.

Figure 1

Demonstrates muscle contracture and stiff posture more on the right upper limb

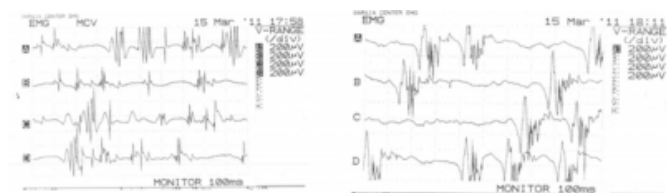


Routine laboratory investigations showed pancytopenia with WBC count of 1.900 mm^3 , RBCs were 3.3 million/mm^3 and Platelet count was $20,000/\text{mm}^3$. Other routine laboratory investigations were normal. Collagenic profile and Thyroid Function were Normal. Anti-VGKC Abs were not available in Alexandria.

CT Chest was normal. CT Abdomen showed Liver cirrhosis, mild periportal fibrosis, huge splenomegaly, portal hypertension and a polyp arising from sigmoid colon.

Figure 2

Fig. 2



Nerve conduction study and EMG were done and confirmed the diagnosis showing neuromyotonic discharge associated with denervation and polyphasic units with fibrillation, positive sharp waves and continuous muscle fiber activities (Fig 2).

The patient had many suspicious lesions; the recurrent oral lesion was investigated and was diagnosed as non-neoplastic vascular malformation.

The patient had a submandibular lymph node that was biopsied to exclude lymphoma and it was found to be reactive and non neoplastic. The pancytopenia was investigated thoroughly and together with the history of bilharziasis and blood film that showed Normocytic normochromic anaemia (with anisopoikilocytosis), neutropenia (toxic granules) and thrombocytopenia and the bone marrow aspiration that revealed hypercellular marrow with megakaryopoiesis and granulocytic hyperplasia. It was

clear that this is a picture of hypersplenism.

Colonoscopy and biopsy of the polyp showed adenomatous nature with no granuloma nor malignancy (Bilharzial Polyp) Paraneoplastic syndrome as a cause was ruled out in our patient as well as hereditary causes.

Our patient received 5 sessions of plasma exchange (0.4mg/kg) performed on an every-other-day schedule with marvelous improvement in myokymia, pseudomyokymia, gait difficulties and sweating and he was discharged on Carbamazepine 1000 mg per day.

DISCUSSION

Acquired neuromyotonia (Isaacs' syndrome) is a rare disorder where hyperexcitability of peripheral motor nerves leads to incapacitating muscle twitching, cramps, myokymia, pseudomyotonia (slow muscle relaxation after forceful contraction) and mild weakness (1). The muscle cramp may be prominent and accompanied by excessive sweating and weight loss (2). This uncommon disorder was first described in 1961 by Isaacs in his paper 'A syndrome of continuous muscle-fibre activity giving the triad of myokymia, muscular stiffness, and decreased deep tendon reflexes the paper's name (3).

Isaac's syndrome has been long recognized by several physicians (4), however its rarity and the variability of its clinical manifestation and ways of presentation is probable the most important reason why its frequently misdiagnosed or wrongly treated (5).

The diagnosis of Isaacs' syndrome is based on clinical features and electromyographic findings. The cardinal features consist of myokymia, pseudomyotonia and stiffness of trunk and limbs. Stiffness without severe pain is more pronounced in the distal than proximal muscles. This abnormal activity persists during sleep. Dyspnea may occur when respiratory muscle is involved. There have been only a few reports of bulbar and laryngeal involvement in Isaacs' syndrome. The tongue and jaw become stiff, making swallowing difficult, and the voice turn hoarse. Associating symptoms include weight loss and excessive sweating (1,2).

Most patients are sporadic. This is related to the autoimmune mechanism where the autoantibodies are usually detected against the Voltage-Gated Potassium Channels (VGKCs)(6,7).

This syndrome may also be related to other autoimmune diseases such as chronic inflammatory demyelinating

polyneuropathy, myasthenia gravis or the presence of antiacetylcholine receptor antibodies(8). The association to hematologic malignancies such as thymoma (9), plasmacytoma(10),Hodgkin's lymphoma (11) and bronchogenic carcinoma paraneoplastic syndromes, has been documented (12).

Clinical evidence suggesting a possible autoimmune etiology included the presence of oligoclonal bands in the spinal fluid of some patients and clinical improvement following plasma exchange (13).

Classical electrodiagnostic studies detect myokymic and neuromyotonic discharges. In addition, fasciculation, doublet, triplet, multiplet and positive sharp waves are also demonstrated in this syndrome. Stimulus-induced repetitive discharges, usually seen after the M wave, are also demonstrated during motor nerve conduction studies (14,15).

Treatment of Isaac's syndrome with antiepileptic drugs or immunotherapy often improves the clinical and electrophysiologic findings (16). Carbamazepine,phenytoin, lamotrigine and sodium valproate can be used alone or if necessary in combination. Paraneoplastic neuromyotonia usually improves after treatment of the underlying cancer (17). In patients whose symptoms are debilitating or refractory to symptomatic therapy, immunomodulatory therapies should be tried (18,19). Plasma exchange often produces useful clinical improvement lasting from 6 weeks up to 6-17 month accompanied by a reduction in EMG activity and a fall in VGKC antibody titres (7,20). IVIg is one the important and recent lines of management with good response (21). There are no good trials of long-term oral immunosuppression. However, prednisolone, with or without azathioprine or methotrexate, has been useful in selected patients (13). (Class IV evidence) (good practice point).

The interactions between helminths, including schistosomes, and the immune system have generated new concepts in immunology and significant advances in vaccine strategies (22).

Schistosomiasis is an important tropical disease affecting approximately 200 million people worldwide. Because of its chronicity and robust immunomodulatory activity, the effects of schistosomes on other diseases, such as allergies, autoimmunity, and infectious diseases, have been an area of interest (23).

Only a minority (<5%) of patients will develop CNS symptoms due to schistosomiasis, with cerebral complications being more prevalent than spinal (24).

Neuroschistosomiasis (NS) is the most severe presentation of schistosome infection; cerebral invasion is mostly caused by *S. japonicum*, with spinal cord involvement due mainly to *S. mansoni* or *S. haematobium* (25).

Some studies found high levels of circulating auto-antibodies in patients with schistosomiasis (26).

Whether the relation between Shistosomiasis and Isaac's syndrome is a causal relationship or a mere comorbidity is a matter of debate, as there is lack of publications in this issue, and further research is warranted.

References

1. Isaacs H. A syndrome of continuous muscle-fiber activity. *J Neurol Neurosurg Psychiatry* 1961; 24:319-25.
2. Lahrmann H, Albrecht G, Drlicek M, Oberndorfer S, Urbanits S, Wanschitz J, et al. Acquired neuromyotonia and peripheral neuropathy in a patient with Hodgkin's disease. *Muscle Nerve* 2001; 24:834-8.
3. Isaacs H. A syndrome of continuous muscle-fibre activity. *J Neurol Neurosurg Psychiatry* 1961; 24: 319-25
4. Ian KH. Acquired Neuromyotonia: A new Autoantibody-Mediated Neuronal Potassium Channelopathy. *Amer J Med Sci* 2000 APR; 319:209-216
5. Foyaca-Sibat H, Ibanez-Valdes LdeF, Awotedu A. Acute renal failure due to herbal medicine intoxication in acquired neuromyotonia.
6. Vincent A. Autoimmune aetiology for acquired neuromyotonia (Isaacs' syndrome). *Lancet* 1991;338: 75-7.
7. Shillito P, Molenaar PC, Vincent A, Leys K, Zheng W, van den Berg RJ, et al. Acquired neuromyotonia: evidence for autoantibodies directed against K⁺ channels of peripheral nerves. *Ann Neurol* 1995;38: 714-22.
8. Newsom-Davis J, Mills KR. Immunological associations of acquired neuromyotonia (Isaacs' syndrome). Report of five cases and literature review. *Brain* 1993; 116: 453-69.
9. Heidenreich F, Vincent A. Antibodies to ionchannel proteins in thymoma with myasthenia, neuromyotonia, and peripheral neuropathy. *Neurology* 1998; 50: 1483-5.
10. Zifko U, drlicek M, Machacek E, Jellinger K, Grisold W. Syndrome of continuous muscle fiber activity and plasmacytoma with IgM paraproteinemia. *Neurology* 1994; 44: 560-1.
11. Caress JB, Abend WK, Preston DC, Logigian EL. A case of Hodgkin's lymphoma producing neuromyotonia. *Neurology* 1997; 49: 258-9.
12. Auger RG. AAEM minimonograph #44: diseases associated with excess motor unit activity. *Muscle Nerve* 1994; 17: 1250-63.
13. Nakatsuji Y, Kaido M, Sugai F, et al. Isaacs' syndrome successfully treated by immunoadsorption plasmapheresis. *Acta Neurologica Scandinavica* 2000; 102: 271-273.
14. Gutmann L, Gutmann L. Myokymia and neuromyotonia 2004. *J Neurol* 2004; 254: 138-42.
15. Dumitru D, Amato AA, Zwarts M. Continuous motor unit activity syndromes. *Electrodiagnostic medicine*. 2nd ed.

- Philadelphia: Hanley & Belfus; 2002: 628-31.
16. Rana S, Ramanathan, Ramnath Santosh, Adamovich. Paraneoplastic Isaacs' Syndrome: A Case Series and Review of the Literature. *Journal of Clinical Neuromuscular Disease*. 2012 13(4):228–33.
17. Hayat GR, Kulkantrakorn K, Campbell WW, Giuliani MJ. Neuromyotonia: autoimmune pathogenesis and response to immune modulating therapy. *Journal of the Neurological Sciences* 2000; 181: 38–43.
18. Alessi G, De Reuck J, De Bleecker J, Vancayzeele S. Successful immunoglobulin treatment in a patient with neuromyotonia. *Clinical Neurology and Neurosurgery* 2000; 102: 173–175.
19. Ishii A, Hayashi A, Ohoshi N, . Clinical evaluation of plasma exchange and high dose intravenous immunoglobulin in a patient with Isaacs' syndrome. *J Neurol Neurosurg Psychiatry*.1994; : 840–2.
20. Elizabeth A. Jaben I JLWS. Plasma exchange as a therapeutic option in patients with neurologic symptoms due to antibodies to voltage-gated potassium channels: A report of five cases and review of the literature. *Journal [serial on the Internet]*. 2012 Date.
21. Nils E MP, Michael B, Skeie G, Verschuuren J. Autoimmune Neuromuscular Transmission Disorders. *European Handbook of Neurological Management*. *Journal [serial on the Internet]*. 2010 Date; Volume 1.
22. Capron et al, Schistosomes: the road from host-parasite interactions to vaccines in clinical trials. *Trends Parasitol*. 2005 Mar;21(3):143-9.
23. Osada Y, Kanazawa T. Schistosome: its benefit and harm in patients suffering from concomitant diseases. *J Biomed Biotechnol*. 2011;2011:264173. Epub 2011 Nov 3
24. Ross AG, Bartley PB, Sleight AC, Olds GR, Li YS, Williams GM, McManus DP: Schistosomiasis. *N Engl J Med* 2002, 346:1212-1220.
25. Wang P, Wu MC, Chen SJ, Luo GC, Cheng XL, Zhu ZS, Zhao GR: Research development of the pathogenesis pathways for Neuroschistosomiasis. *Neurosci Bull* 2010, 26:168-174
26. Abbas MM, Abdel Kader S. A study of autoimmunity in schistosomiasis. *J Egypt Soc Parasitol*. 1993 Apr;23(1):289-96

Author Information

Ismail Ibrahim

Neurology Department, Alexandria University

Doaa Abdelzahir

Neurology Department, Alexandria University

Abdulrahman Mostafa

Neurology Department, Alexandria University

Osama Y. Mansour

Neurology Department, Alexandria University