

Unusual Oral Cavity Metastasis From Follicular Carcinoma Of The Thyroid – A Case Report

A Kumar Naveena, T Elamurugan, G Sreenath, S Jagdish

Citation

A Kumar Naveena, T Elamurugan, G Sreenath, S Jagdish. *Unusual Oral Cavity Metastasis From Follicular Carcinoma Of The Thyroid – A Case Report*. The Internet Journal of Head and Neck Surgery. 2013 Volume 6 Number 1.

Abstract

Metastatic tumours in the oral cavity are relatively uncommon and account for 1% of all oral malignancies. The breast, the lung and the kidney are the common primary origin of metastasis. Metastasis to the oral cavity from a thyroid malignancy is very rare and cases described in literature are very few. We report a case of 70 year old lady who presented with a soft tissue swelling in the oral cavity without any other significant clinical findings. Ultrasound of the neck showed a very small anechoic area in the left lobe of thyroid. Fine needle aspiration cytology from both lesions showed malignant cells with follicular pattern.

INTRODUCTION

Metastatic tumours of the oral cavity are rare constituting approximately one percent of all oral malignancies¹. Breast, lung and kidney are the primary origin of metastasis in 50% to 60% of the cases². Thyroid malignancy metastasizing to the oral cavity is not very frequent and cases described in the literature are very few. We report one such rare case of oral cavity metastasis from a thyroid malignancy.

CASE REPORT

A 70 year old lady presented with complaints of gradually increasing painful swelling in the oral cavity for three months. On examination of the oral cavity, a 7 x 6 cm well defined swelling with soft consistency was noted in the floor of mouth extending into the lower alveolus (Fig.1 and Fig. 2). The swelling bleeds on touch. There was no thickening or irregularity of mandible detected on clinical examination. There were no palpable cervical lymph nodes. No abnormality detected on other systemic examination.

Based on the clinical findings, a provisional diagnosis of a primary oral malignancy was considered. Due to increase vascularity of the swelling, fine needle aspiration cytology (FNAC) was considered instead of biopsy and reported to have thyroid follicles. Ultrasound of the neck showed a 1.5x1x1 cm lobulated mass with central anechoic area in the left lobe of thyroid. There were no cervical lymph nodes detected. The FNAC of the thyroid swelling revealed follicular pattern. Based on the above investigations the provisional diagnosis of follicular carcinoma thyroid with

oral cavity metastasis was made. A biopsy was further considered to confirm the diagnosis. The histopathological examination showed thyroid follicles which is positive for PAS stain. There was thickened capsule with capsular invasion (Fig.3 and Fig 4). The CT scan of head and neck revealed metastatic lesion arising from mandible extending into oral cavity (Fig.5).

Figure 1

Fig.1: Metastatic lesion in the oral cavity

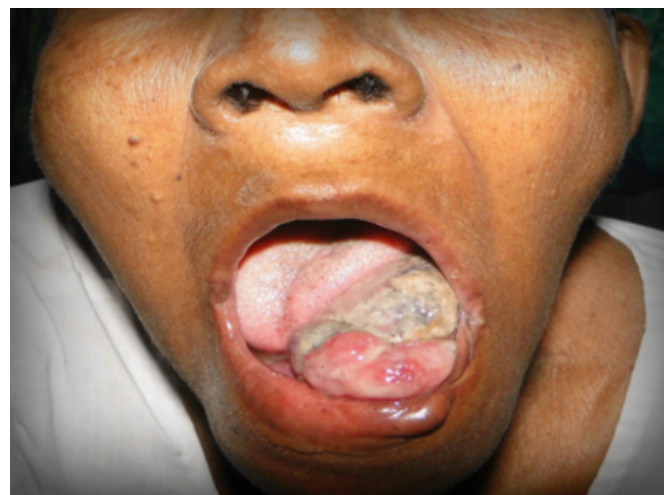

Figure 2

Fig.2: Metastatic lesion in the oral cavity

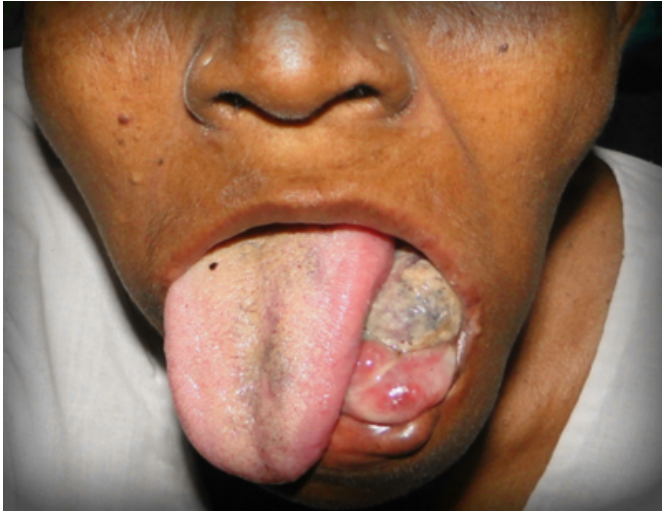

Figure 3

Fig. 3: Histopathology of Metastatic lesion (H & E stain, x100) showing thickened capsule with invasion

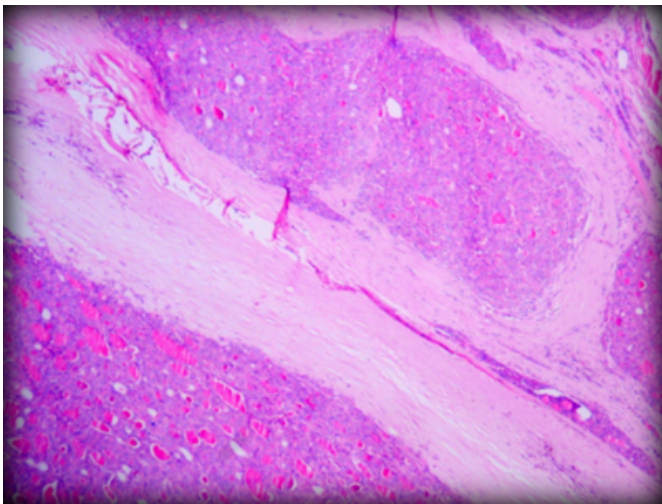


Figure 4

Fig. 4: Histopathology of Metastatic lesion (H & E stain, x400) showing similar sized micro follicles.

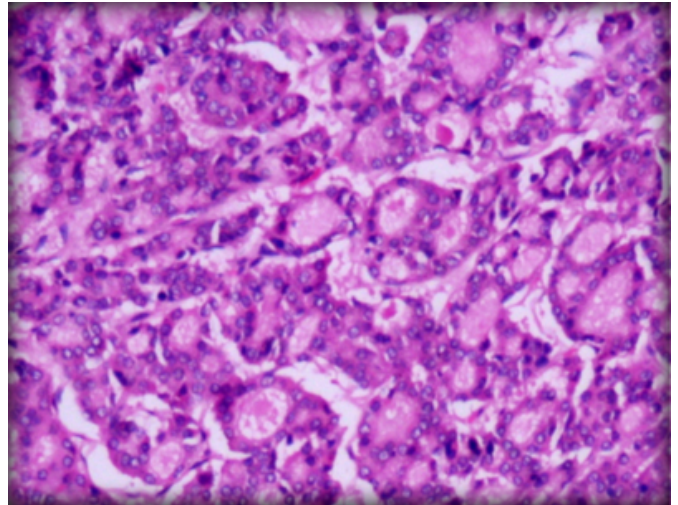
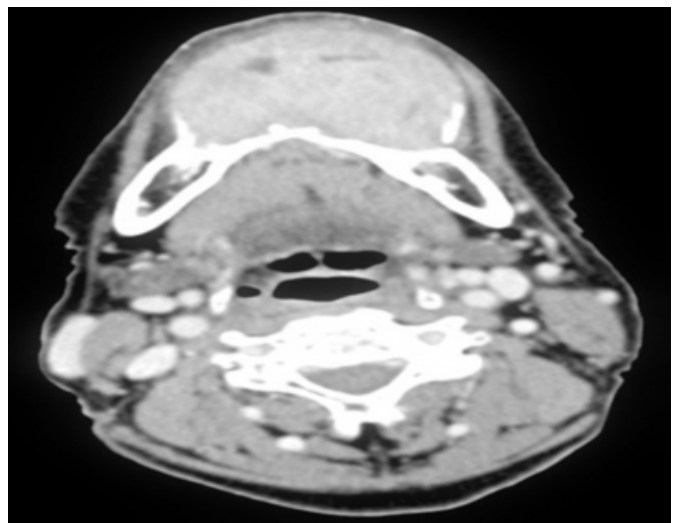


Figure 5

Fig. 5: CECT Head and Neck showing lesion arising from the mandible.



DISCUSSION

The metastases to the oral cavity are quite uncommon. Usually occurs in the fifth to seventh decades of life. Although the oral soft tissues may be affected, particularly the gingiva, mucosa of the alveolar ridge and the tongue, metastases to the jaw bones, especially the posterior mandible, is considerably more common³. The most common origins of metastasis are breast, ovary and thyroid in female patients and lung, prostate, kidney and liver in men. The lung is the most common origin of metastasis into oral soft tissues, whereas the breast is the most common origin of metastatic tumours in the jaw bones.

Follicular thyroid carcinoma (FTC) is most common in women between the ages of 22 and 50 years. The follicular thyroid carcinoma metastasizes through the hematologic route to the lungs, bone, liver and brain. It exhibits a relatively small propensity for lymphatic spread. Bone metastasis are found in 1 to 3 percent of well-differentiated thyroid carcinomas, occurring more often in follicular carcinoma and in patients more than 40 years of age⁴.

Jaw metastasis are found to be less common than other bones metastases as the amount of red bone marrow and blood vessels in the jaw bones tends to decrease with age³. Most (60%–80%) metastasis involving jaw bones occurs in the mandible, mainly in the molar and premolar areas. This is thought to be due to the greater presence of hematopoietic tissue in the mandible⁵. They tend to invade blood vessels and to metastasize hematogenously to visceral sites. The real incidence of metastatic tumours in the jaw bones is unknown. This is due to the fact that the jaws are seldom involved in the radiographic skeletal survey for metastasis or examined in autopsies.

Jaw metastasis manifests as painful swelling, abnormal mobility of teeth, delay in healing of extraction sockets, pathologic fractures or paresthesia. Less frequently the lesion can present as pain in the temporo-mandibular joint region or as an osteomyelitis in the jaw or as trigeminal neuralgia⁶. Patient complaining of numb chin or mental nerve neuropathy should always raise the possibility of a metastatic disease in the mandible. Radio graphically, metastatic lesions are most often ill-defined and are usually osteolytic or radiolucent, although they may be osteoblastic, radiopaque mixed lesions. In approximately 5% of cases, pathological changes are not detected radio graphically³. However it should be noted that in 29-33% of the cases, the metastatic lesion might be the first indication of an undiscovered malignancy at a distant site⁷.

A combination of various treatment modalities is commonly used in the management of metastatic lesions with poor success rates. Therefore, a palliative therapy is often advised

such as radiotherapy to the affected jawbone for pain relief⁵. Curative treatment of an oral metastatic tumor site is considered only if extensive search for other metastases reveal only the oral site combined with an identified primary tumor that is controlled or treated successfully. In this case patient was planned for total thyroidectomy followed by radiotherapy.

The presence of distant metastases is associated with poor prognosis. An overall 10-year survival rate of 27% for bone metastasis of differentiated thyroid carcinoma has been reported⁸. The prognosis of jaw metastasis is usually grave and average time from appearance of metastasis to a fatal outcome appears to be around 7-8 months.

To conclude, this case report was presented to emphasize the inclusion of metastatic neoplasm in the differential diagnosis of oral cavity lesions. An early detection of metastatic disease improves the overall survival rate and treatment results.

References

1. Vander Waal RI, Buter J, Vander Waal I. Oral Metastasis: Report of 24 Cases. *Br J Oral Maxillofac Surg* 2003; 41: 3-6.
2. Hirshberg A, Buchner A. Metastatic tumors to oral region: An overview. *Eur J Cancer B. Oral Oncol* 1995; 31B: 355-6.
3. Hirshberg A, Leibovich P, Buchner A. Metastatic tumors to the jawbones: analysis of 390 cases. *J Oral Pathol Med* 1994; 23(8): 337-341.
4. Mizukami Y, Michigishi T, Nonomura A. Distant metastases in Differentiated thyroid carcinomas: a clinical and pathologic study. *Human Pathology* 1990; 21(3): 283-290.
5. Zachariades N, Koumoura F, Vairaktaris E, Mezitis M. Metastatic tumors to the jaws: a report of seven cases. *J Oral Maxillofac Surg* 1989; 47(9): 991-6.
6. Glaser C, Lang S, Pruckmayer M, Millesi W, Rasse M et al. Clinical manifestations and diagnostic approach to metastatic cancer of the mandible. *Int J Oral Maxillofac Surg* 1997; 26: 365-8.
7. Lim SY, Kim SA, Ahn SG, Kim HK, Kim SG, Hwang B et al. Metastatic tumours to the jaws and oral soft tissues: A retrospective analysis of 41 Korean patients. *Int J Oral Maxillofac Surg* 2006; 35: 412-5.
8. Schlumberger M, Tubiana M, De Vathair F. Long term results of treatment of 283 patients with lung and bone metastases from differentiated thyroid carcinoma. *J Clin Endocrinol Metab* 1986; 63(4): 960-967.

Author Information

A N Kumar Naveena

Department of General Surgery, Jawaharlal Institute of Postgraduate Medical Education and Research

T P Elamurugan

Department of General Surgery, Jawaharlal Institute of Postgraduate Medical Education and Research

G S Sreenath

Department of General Surgery, Jawaharlal Institute of Postgraduate Medical Education and Research

S Jagdish

Department of General Surgery, Jawaharlal Institute of Postgraduate Medical Education and Research