

Pseudo-Duplication Of The Gall Bladder Due To Phrygian Cap – A Case Report

S Dalal, T Chauhan, R Kumar, S Choudhury

Citation

S Dalal, T Chauhan, R Kumar, S Choudhury. *Pseudo-Duplication Of The Gall Bladder Due To Phrygian Cap – A Case Report*. The Internet Journal of Surgery. 2013 Volume 29 Number 1.

Abstract

Congenital anomalies of the biliary tree including the gall bladder are not infrequent. It is important to diagnose them pre-operatively to avoid potential injuries to the ductal system. We are reporting a case of an elderly female, who presented with signs and symptoms suggestive of chronic cholecystitis. On radiological evaluation she was diagnosed as a case of duplication of the gall bladder, but during cholecystectomy only a single gall bladder was present and it was having a Phrygian cap. Radiological evaluation of such anomalies and their management with reference to literature are discussed in this report.

INTRODUCTION

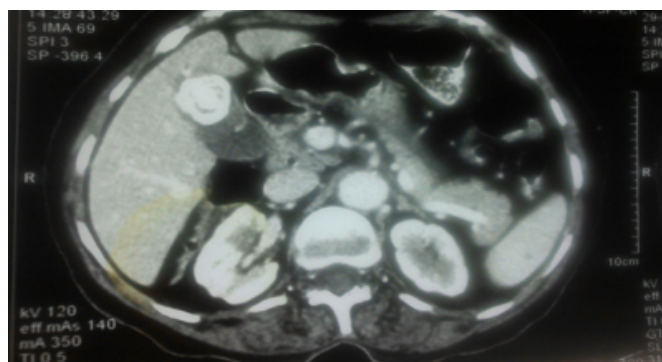
Gall bladder duplication is a rare congenital malformation, occurring in about one per 4000 births.¹ Pre-operative diagnosis is extremely important as, if diagnosed during surgery; the per-operative location of the second gall bladder may be difficult or even missed. Differential diagnosis of duplication of gall bladder includes gall bladder diverticula, gall bladder fold, Phrygian cap, choledochal cyst, pericholecystic fluid, etc.² We are reporting a case where the diagnosis of duplication of the gall bladder was made on imaging studies, but on per-operative examination it was found to be a case of a gall bladder with a Phrygian cap.

CASE REPORT

A 63-year-old female presented with right upper abdominal pain and fatty dyspepsia for the last three months. Physical examination revealed mild tenderness in the right hypochondrium and her vitals were normal. Routine hematological and liver function tests were within normal limits. Based on history and clinical examination, a clinical diagnosis of chronic cholecystitis was made and she was subjected to ultrasonography which revealed a double gall bladder with multiple stones. She was admitted to a surgical ward for confirmation of diagnosis and subsequent cholecystectomy. CECT of the abdomen was carried out to confirm the diagnosis, which revealed a double gall bladder with one of them showing cholesterosis (Fig.1).

Figure 1

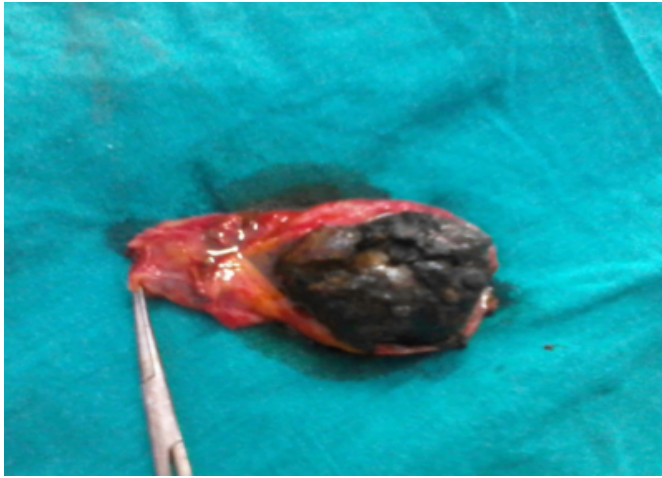
Fig.1: CECT of the abdomen showing duplication of the gall bladder with one of the gall bladders having cholesterosis.



Open cholecystectomy was planned due to the presence of cholesterosis. After careful dissection and removal of adhesions, the anatomy of Calot's triangle was displayed. There was a single cystic duct, a single artery and the gall bladder was not duplicated, rather it was having a Phrygian cap with a single large stone in it (Fig.2).

Figure 2

Fig.2: Split open gall bladder showing a single gall bladder with a big stone and a Phrygian cap.



Due to the presence of a Phrygian cap, there appeared to be a double gall bladder on USG and CECT of the abdomen. Cholecystectomy was completed successfully. The abdomen was closed after inspecting the gall bladder bed for any bleeding or biliary leak. There were no postoperative complications and the patient was discharged on the 3rd postoperative day in a healthy condition.

DISCUSSION

True gall bladder-duplication is a rare congenital anomaly that may cause diagnostic and surgical problems.¹ The presence of a double gall bladder is not associated with any specific symptoms and there is no known predisposition for cholelithiasis or cholecystitis in these patients.² Few cases have been reported in literature where repeated attacks of cholecystitis in the remaining gall bladder have required re-operation.³ Differential diagnosis includes gall bladder diverticula, gall bladder fold, Phrygian cap, choledochal cyst, pericholecystic fluid, etc.² Various modalities like USG, oral cholecystography (OCG), endoscopic retrograde cholangiopancreatography (ERCP), CT scan and MRI can be used to diagnose a double gall bladder. ERCP is the invasive procedure, so rarely used. The initial investigation of choice is ultrasonography, but in doubtful cases, CT and MRI can be used to delineate the anatomy of the biliary system.⁴

The most common congenital anomaly of the biliary tract is a folded gall bladder. Boyden described this anomaly as a “Phrygian cap” deformity in 1935, because it resembled a bonnet worn by the ancient Phrygians, who lived in Asia Minor during the 12th century BC.⁵ From the developmental

point of view, it may be considered a non-developed form of congenital septum. In order to cause symptoms, the connection between the two gall bladder cavities should be very narrow, obstructing the flow of bile between them. A Phrygian cap is suggested on the radionuclide scan when the gall bladder initially appears smaller than the size of the gall bladder fossa and then fills distally on delayed images obtained after two and three hours.⁶ This deformity may also be suspected when its characteristic appearance is seen on high-resolution ultrasonography.²

Clearly one would not suggest prophylactic cholecystectomy in every gall bladder showing some anatomical abnormality, but when symptoms are present in association with deformity, cholecystectomy is indicated even without gallstones. Complete pre-operative evaluation of anatomy is a must in these cases to avoid potential damage to the ductal system. Laparoscopic cholecystectomy, which has now become the gold standard for gall bladder removal, is safe for these cases including double gall bladder.⁷

The present patient was an elderly female who presented with clinical features suggestive of chronic cholecystitis. On radiological investigations, i.e. ultrasonography and CECT of the abdomen, a diagnosis of cholelithiasis with duplication of the gall bladder was made. During cholecystectomy it was found to be a Phrygian cap rather than a double gall bladder. The case is being reported to bring the following important facts into the notice of readers:

References

1. Lamah M, Karanjia ND, Dickson GH: Anatomical variations of the extrahepatic biliary tree: review of the world literature. *Clinical Anatomy*; 2001; 14(3): 167-72.
2. Goiney RC, Schoenecker SA, Cyr DR, Shuman WP, Peters MJ, Cooperberg PL: Sonography of gall bladder duplication and differential consideration. *Am J Roentgenol*; 1985; 145(2): 241-3.
3. Silvis R, van Wieringen AJ, van der Werken CH: Reoperation for a symptomatic double gallbladder. *Surg Endosc*; 1996; 10: 336-7.
4. Mazziotti S, Minutoli F, Blandino A, Vinci S, Salamone I, Gaeta M: Gall bladder duplication: MR cholangiography demonstration. *Abdom Imaging*; 2001; 26(3): 287-9.
5. Boyden EA: The Phrygian cap in cholecystography: a congenital anomaly of the gall bladder. *Am J Radiol*; 1935; 33: 589-90.
6. Smergel EM, Maurer AH: Phrygian cap simulating mass lesion in hepatobiliary scintigraphy. *Clin Nucl Med*; 1984; 9: 131-3.
7. Gigot J, Van Beers B, Goncette L, Etienne J, Collard A, Jadoul P, Therasse A, Otte JB, Kestens P: Laparoscopic treatment of gallbladder duplication. A plea for removal of both gallbladders. *Surg Endosc*; 1997; 11(5): 479-82.

Author Information

Satish Dalal, M.S., F.A.I.S., F.I.C.S.

Professor, Department of General Surgery, Pt.B.D.Sharma Postgraduate Institute of Medical Sciences (P.G.I.M.S.)

Tapan Singh Chauhan, M.S.

Senior Resident, Department of General Surgery, Pt.B.D.Sharma Postgraduate Institute of Medical Sciences (P.G.I.M.S.)

Ramesh Kumar

Junior Resident, Department of General Surgery, Pt.B.D.Sharma Postgraduate Institute of Medical Sciences (P.G.I.M.S.)

Satyaprakash Ray Choudhury

Junior Resident, Department of General Surgery, Pt.B.D.Sharma Postgraduate Institute of Medical Sciences (P.G.I.M.S.)