

# Klippel Trenaunay Syndrome And Pregnancy Associated With Post Partial Thyroidectomy And Gestational Diabetes Mellitus: A Case Report

S De, K Nagandla, S Kanagasabai, T Woh

## Citation

S De, K Nagandla, S Kanagasabai, T Woh. *Klippel Trenaunay Syndrome And Pregnancy Associated With Post Partial Thyroidectomy And Gestational Diabetes Mellitus: A Case Report*. The Internet Journal of Gynecology and Obstetrics. 2013 Volume 17 Number 3.

## Abstract

Pregnancy associated with Klippel Trenaunay syndrome is rare. Few cases have been reported in the medical literature. In this case report, we describe a patient who had partial thyroidectomy seven years prior to the pregnancy associated with gestational diabetes. She was monitored in the second half of the pregnancy by two weekly blood sugar profile, thyroid function test and serial ultrasound. The soft tissue hypertrophy restricted the movement of her entire left lower limb which made flexion of the hip and knee joint severely painful. Hence she was planned for an elective caesarean. Unfortunately she came with preterm prelabor rupture of membranes at 36 weeks of gestation and had an emergency caesarean. She had an uneventful intra and post operative period and was discharged on the fifth post-op day. This case report illustrates that women with Klippel Trenaunay syndrome with systematic management approach are likely to have an uneventful pregnancy.

## INTRODUCTION

Klippel Trenaunay Syndrome (KTS) is rare congenital malformation which includes a triad of features like vascular malformation, soft tissue hypertrophy and varicosities.<sup>1</sup> There are merely few cases reported of this syndrome with pregnancy in the medical literature hence there are no guidelines available as to the management of pregnancy with KTS. In this patient in addition to KTS, she had associated endocrine problems like subclinical hypothyroidism and gestational diabetes.

## CASE REPORT

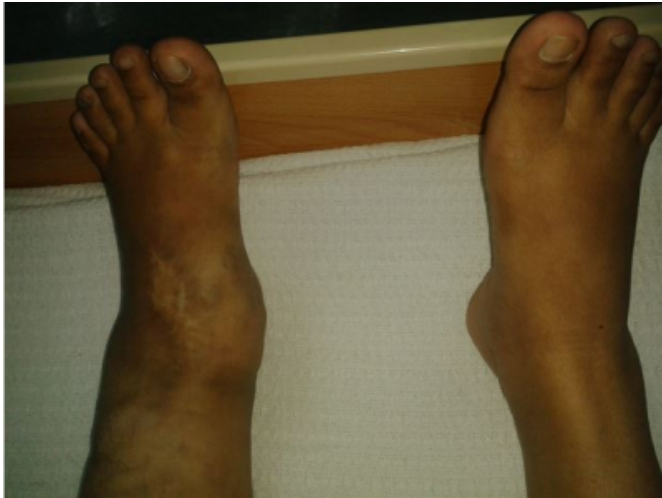A 37-year-old primigravida diagnosed as a case of Klippel Trenaunay syndrome since the age of 25 years, asymptomatic and on conservative follow up presented in the second trimester of her pregnancy for antenatal booking. At 16 weeks, she had gestational diabetes complicating pregnancy (modified glucose tolerance test; fasting 5.87mmol/L & 2 hrs 9.79mmol/L) and was initiated on insulin therapy [Actrapid 6/6/8 units and Monotard 8 units]. She was monitored fortnightly by postprandial blood sugar profile. She also had a past history of partial thyroidectomy done seven years back for goiter. During this pregnancy she never had any symptoms of hypothyroidism and the result of her thyroid function test prior to her caesarean section was

TSH 7.59 mU/L and T4 15.59 pmol/L

On examination, she had venous malformation in the left lower limb starting from the feet and extending to the lower thigh. No surgical intervention was done in view of involvement of deeper muscles and possibility of high morbidity from the procedure. She was on compression stockings. She had no muscle weakness however she complained of pain while walking. She could not flex her lower limb (hip and knee joints) due to severe pain and hence an elective lower segment caesarean section was planned at 38 weeks. The hypertrophy of the soft tissues was obvious when it was compared with the normal limb as shown in Fig 1 & 2.

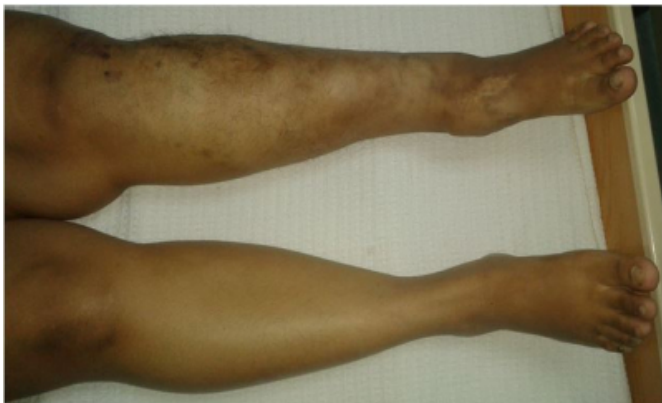**Figure 1**

Soft tissue hypertrophy of the left ankle



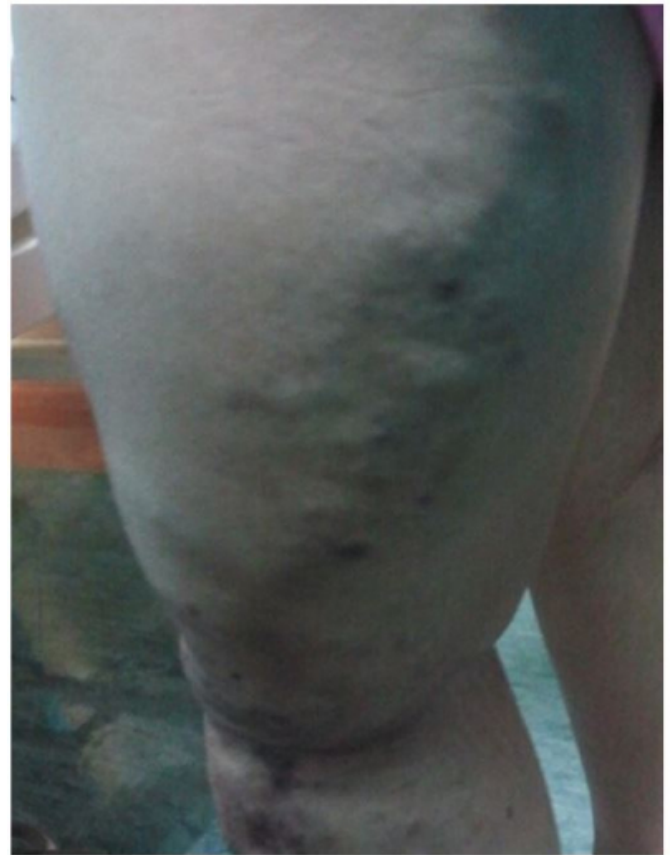**Figure 2**

Soft tissue hypertrophy of the left leg



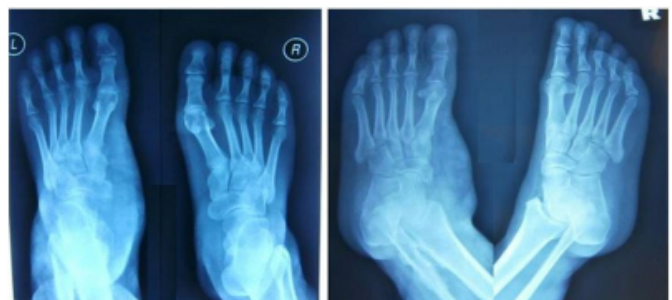**Figure 3**

Varicose veins of the left lower limb



**Figure 4**

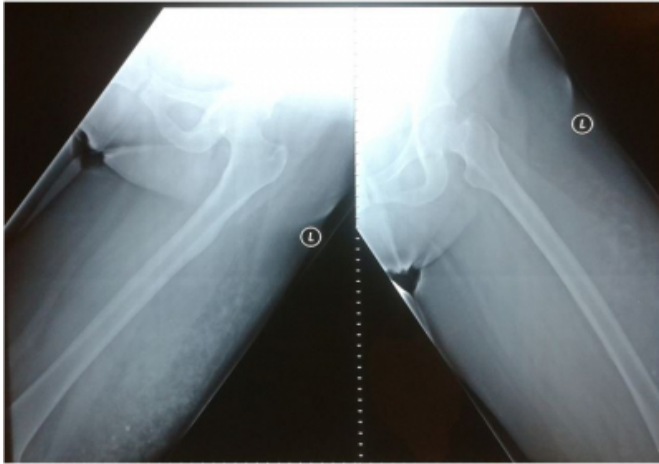
Soft tissue hypertrophy seen in the X ray of the left ankle



The left lower limb also had multiple varicosities as evident in Fig 3. There was no associated vulvovaginal varicosity. The pictures corroborated with the X ray pictures taken two days after her caesarean section. The ankles in both AP and lateral view showed soft tissue hypertrophy in the dorso-medial aspect (Fig 4). The left thigh in AP and lateral view showed soft tissue hypertrophy along with phleboliths and tubular opacities (Fig 5). The most remarkable change was evident in the X ray of the left leg (Fig 6) which revealed marked soft tissue hypertrophy along with calcification. There was thickening of the cortex of the mid lower tibia and lower fibula.

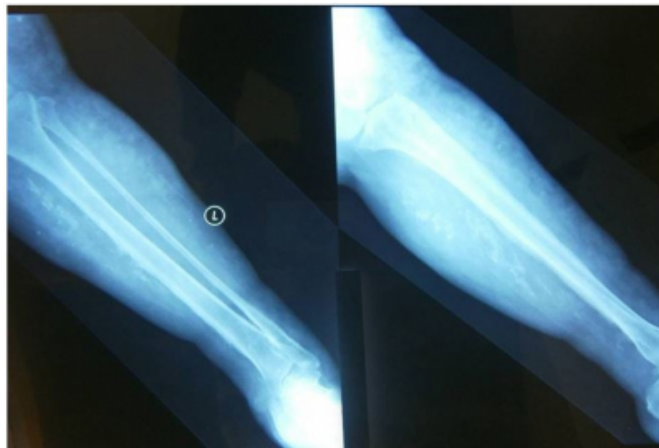
**Figure 5**

Phleboliths and opacities seen in the X ray of the left thigh



**Figure 6**

Opacities seen in the X ray of the left leg in two different view



The fetal anomaly scan done at 18 weeks was normal and she had serial ultrasound scans at 22 weeks, 27 weeks, 31 weeks and 35 weeks which revealed a fetus growing well without any evidence of growth restriction. Her blood sugar profile was normal during the regular monitoring. Her coagulation profile was also normal. At 36 weeks of gestation she came with leaking per vagina which was demonstrated and confirmed by speculum examination. The leaking was clear and was followed by contraction pains. Vaginal examination revealed a fully effaced cervix with dilatation of 3cm and head at station -1. She was taken up for emergency LSCS. There was no intra-operative complication and the estimated blood loss was 500mL. Her hemoglobin levels were normal before and after operation. She had a baby boy weighing 2.85kg. Intra-operatively no varicosities were seen on the uterus. Her post operative

period was uneventful and she ambulated from the first post-op day. The insulin was stopped and glucometer monitoring showed blood sugars were within normal range. She was discharged on the fifth post-op day.

## DISCUSSION

Pregnancy with KTS is a rare condition. From the case report of G. Fait et al it is evident that KTS with pregnancy poses more risk to the mother than the fetus. For the mother, the risk factors are mainly excessive bleeding, increased operative delivery and varicosities of external genitalia.<sup>2</sup> For the fetus the exact risk is not known however one study demonstrated fetal growth restriction.<sup>2</sup> Hergesell K et al advised in their case report that women with KTS should have an ultrasonographic scan at the end of first trimester to rule out angiodysplastic changes in the fetus.<sup>3</sup> In our case, the fetal anomaly scan was normal and the serial growth scans revealed normal fetal growth.

Our patient had varicose veins in her left thigh as shown in Fig 3. The presence of hemangioma was evident by the presence of phleboliths in the x ray pictures. There were no vulvovaginal varicosities and hence further evaluation with MR angiography to rule out abnormal vascular communications was not indicated.

The most prominent soft tissue and bony hypertrophy were revealed in Fig 4, 5 & 6. She underwent caesarean section because of inability of flexion of the left lower limb due to these soft tissue and bone hypertrophy. She did not have any excessive bleeding which was evident from the estimated blood loss and also from the full blood picture postoperatively.

There is no case report or literature to compare her medical problems which were subclinical hypothyroidism and gestational diabetes. However the baby had normal TSH levels and was not macrosomic as her diabetes was well controlled by insulin.

One case report mentioned about their patient having deep vein thrombosis and therefore advocated postpartum anticoagulant prophylaxis for patients with KTS in form of low molecular heparin.<sup>4,5</sup> In our case there was no episode of previous thrombotic attack and she never had any signs or symptoms suggestive of thrombosis during pregnancy. She was not administered any anticoagulant therapy or prophylaxis as her coagulation profile was normal. However Reiko Tanaka et al recommended that one should administer

prophylactic anticoagulants even if the coagulation profile is normal.<sup>6</sup> This fact was contradicted by A Gianlupi et al as they concluded since there were no prospective studies done on KTS with pregnancy for coagulopathy hence the need for anticoagulant therapy for KTS patient with pregnancy should be discussed on an individual basis.<sup>7</sup> Verheijen RH et al stated in their case report that the main risk for patients with KTS is disseminated intravascular coagulation either intrapartum or postpartum.<sup>8</sup> Rebarber A et al reported of three women with four pregnancies complicated by KTS and showed that only one had pulmonary embolism whereas the other three had uneventful outcome.<sup>9</sup> However Atis A et al reported that the complications during pregnancy are usually related to the severity of the disease.<sup>10</sup> Our patient never had any derangement of her coagulation profile or exacerbation of her symptoms during the pregnancy.

To conclude, in women with KTS, pregnancy is not

contraindicated as the outcome is usually favorable and a pre-conceptional counseling is paramount in further reducing the adverse outcomes. Our report shows that there was no adverse effect on the fetus but it is prudent to have a detailed structural scan done around mid trimester along with careful monitoring during antepartum, intrapartum and postpartum period which can reduce the morbidity and mortality associated with this syndrome. We also report that there was no alteration in the course of her endocrine disorders (diabetes and hypothyroidism) which was managed with the routine hospital protocols.

## **ACKNOWLEDGEMENTS**

We would like to thank Dr Faridah, Dr Nurulhuda and Sister Pavallaih for their efforts and help in retrieving the material and illustrations of the case report.

## **References**

**Author Information**

**Somsubhra De, MS (OBG), FAGE Associate Professor**

Department of Obstetrics & Gynecology, Melaka Manipal Medical College

Melaka, Malaysia

somde@yahoo.com

**Kavitha Nagandla, MRCOG Assistant Professor**

Department of Obstetrics & Gynecology, Melaka Manipal Medical College

Melaka, Malaysia

**Sachchithanantham Kanagasabai, FRCOG, FRANZCOG Professor & HOD**

Department of Obstetrics & Gynecology, Melaka Manipal Medical College

Melaka, Malaysia

**Tham Seng Woh, M. MED (O & G) Consultant & HOD**

Department of Obstetrics & Gynecology, General Hospital Malacca

Melaka, Malaysia