

Cardiac Vignette: A Case of Pericardial Lipoma

A Bhat, F Ting, J McCrohon, B Walker

Citation

A Bhat, F Ting, J McCrohon, B Walker. *Cardiac Vignette: A Case of Pericardial Lipoma*. The Internet Journal of Cardiology. 2013 Volume 11 Number 1.

Abstract

Pericardial lipoma is a rare cardiac condition involving extensive fat deposition in the pericardium. While typically an incidental finding on non-cardiac imaging, the condition has the potential to exert a mass effect and thus compromise ventricular filling, leading to symptomatic outcomes associated with cardiac insufficiency, conduction defects and arrhythmias. It is therefore of importance in clinical practice. In this cardiac vignette, we illustrate the diagnostic dilemma present with this condition, with first-line investigations such as echocardiography often misinterpreting this condition as a pericardial effusion. Less routine cardiac imaging modalities, including cardiac CT and CMR, are the preferred diagnostic tests for accurate diagnosis of this condition, however are scarcely utilised.

CARDIAC VIGNETTE: A CASE OF PERICARDIAL LIPOMA

A 79 year old female was referred for evaluation of a pericardial effusion detected on echocardiography in an outpatient cardiology service. She had a background of a recent pre-syncope episode during ambulation, with associated nausea and diaphoresis, requiring supine posturing for symptomatic relief. This episode was associated with tachycardia (135 beats /min) and significant orthostatic hypotension, however no chest pain or discomfort was noted.

The patient's relevant past medical history included stage 1 (uncontrolled) hypertension, transient ischemic attack requiring anti-platelet prophylaxis and alcohol-induced hepatitis. There was no significant family history of cardiac disease. The patient was a lifelong non-smoker, but consumed 40-60g of alcohol per day for the past 20 years.

Physical examination revealed unremarkable vital signs, with the exception of a significant postural blood pressure drop of 20mmHg. There was no pulsus paradoxus. The peripheral pulses were normal in character and volume with a resting heart rate of 84 beats /min. The carotid upstroke was brisk and the jugular venous pressure was not elevated. The patient had a negative Kussmaul's sign. Heart sounds were normal with no extra sounds, murmurs or pericardial frictions rubs noted. The chest was clear to auscultation and there was no peripheral oedema.

Blood biochemistry and haematology results were unremarkable, with the exception of macrocytosis consistent with the patient's alcohol history. A 12-lead electrocardiogram (ECG) during admission was unremarkable. Repeat transthoracic echocardiogram [Figure 1] revealed an echo-lucent pericardial space (maximum diameter 2cm with no evidence of cardiac tamponade). Left ventricular size and function was within normal limits. There were no other cardiac abnormalities. Cardiac Magnetic Resonance Imaging (CMR) [Figures 2 and 3] revealed marked pericardial fat with minor fatty replacement of the myocardium. No definitive features of constriction were present; however cardiac chamber volumes were reduced, possibly making the effects of dehydration prominent. A diagnosis of pericardial lipoma was made.

Figure 1

Transthoracic Echocardiography revealing an echo-lucent pericardial space with maximum ‘pocket’ diameter of 2cm. There is no evidence of cardiac tamponade.

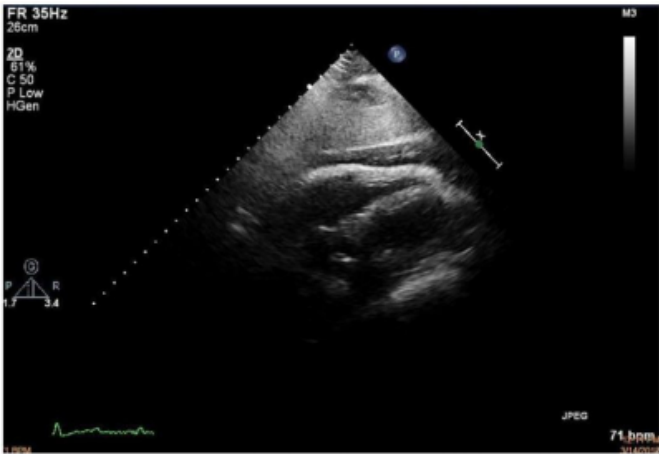


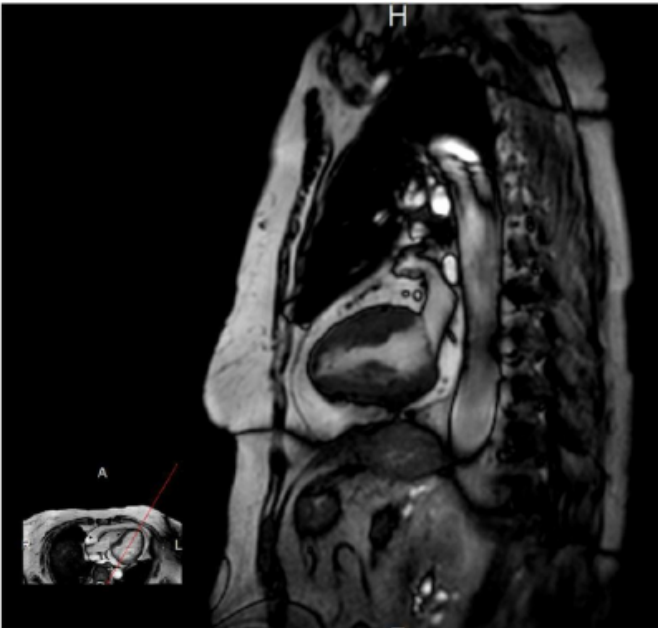
Figure 2

Cardiac MRI (Horizontal View) revealing marked pericardial fat with minor fatty replacement of the myocardium. There are no obvious features of cardiac constriction.

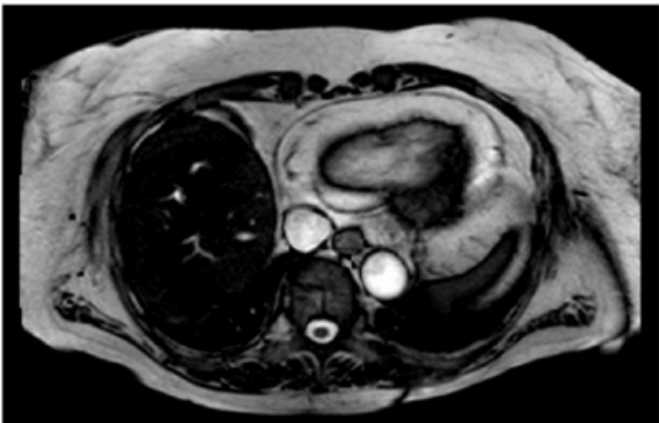

Figure 3

Cardiac MRI (Saggital View) revealing marked pericardial fat with minor fatty replacement of the myocardium. There are no obvious features of cardiac constriction.



The patient remained stable throughout admission with improvement in symptoms and orthostatic hypotension with oral rehydration. No further diagnostic interventions were performed and the patient was subsequently discharged. At three month follow-up, the patient remained asymptomatic and repeat echocardiogram revealed no change in the appearance of the pericardial space.

DISCUSSION

Pericardial lipoma is a rare cardiac condition involving extensive fat deposition in the pericardium. While typically an incidental finding on non-cardiac imaging, [1] the condition has the potential to exert a mass effect and thus compromise ventricular filling, leading to symptomatic outcomes associated with cardiac insufficiency, conduction defects and arrhythmias. [2] There is also a risk of valvular impairment and external “pseudo-stenosis” due to direct extension and compression of

ventricular outflow tracts. [3, 4] Furthermore, the frequency of interventricular septal and left ventricular free-wall rupture associated with myocardial infarction has been shown to be increased in patients with excess fat deposition around the myocardium. [5]

The aetiology and pathogenesis of this condition is unclear, with studies pointing to an association with prolonged endogenous or exogenous corticosteroid exposure. [6, 7] Furthermore, pericardial lipomas presents a diagnostic dilemma, with first-line investigations such as echocardiography often misinterpreting this condition as a pericardial effusion. Less routine cardiac imaging modalities, including cardiac CT and CMR, are the preferred

diagnostic tests for accurate diagnosis of this condition.

CMR has been shown to be superior to all other current imaging techniques in its ability to accurately define the location, size and extension of pericardial fat. Furthermore, utilising gadolinium uptake, CMR has the ability to distinguish benign fat deposition from potentially malignant neoplasms. Such factors are important in determination of management, including possible surgical approaches. [8, 9]

Management of pericardial lipomas are dependent on the degree of cardiac compromise and symptomatic status. If required, surgical removal of lipomatous material from the pericardium is feasible, however is not without risk. [10]

References

Author Information

Aditya Bhat, BMedSci, MBBS

Blacktown Hospital
Sydney, NSW, Australia
mradityabhat@gmail.com

Francis Ting, MBBS

St Vincent's Hospital
Sydney, NSW, Australia

Jane McCrohon, MBBS, FRACP, PhD, FCSANZ

St Vincent's Hospital
Sydney, NSW, Australia

Bruce Walker, MBBS, PhD, FRACP

St Vincent's Hospital
Sydney, NSW, Australia