

Management of Rare Craniofacial Anomalies in Charity Missions: Community-Based Solutions

T Abulezz, H A Fadaak, J Jadulkarim

Citation

T Abulezz, H A Fadaak, J Jadulkarim. *Management of Rare Craniofacial Anomalies in Charity Missions: Community-Based Solutions*. The Internet Journal of Plastic Surgery. 2013 Volume 10 Number 1.

Abstract

In poor communities, patients may suffer from health conditions requiring special management that are not available locally. Missionary visiting teams have attempted to address these issues in collaboration with local healthcare authorities. Children with craniofacial anomalies represent one of these challenging issues. Here we present the senior author's experience in management of rare craniofacial anomalies during missionary visits to Yemen highlighting outcomes of management of rare and challenging craniofacial anomalies using simple techniques of soft tissue repair adhering to the community limitations and lack of facilities.

INTRODUCTION

Patients suffering from conditions requiring specialist intervention cannot obtain treatment when facilities do not exist locally. Specialist visiting teams in a number of surgical disciplines have attempted to address these issues in collaboration with local clinicians. These interventions require careful planning and communication to achieve optimum results (1).

Children with craniofacial anomalies comprise a diverse group of patients, with problems involving many organ systems. In the past, no satisfactory treatment was available for many of these problems. Though the contributions of Tessier and many other innovators together with multidisciplinary team approach are now offering substantial improvement in the management of those patients. The best reconstruction for any given patient can be determined only after a careful analysis of the patient's problems and the patient's and family's wishes (2, 3, 5).

Unfortunately, management of these anomalies in underprivileged communities may be a real challenge because of the rarity of the qualified craniofacial surgeons, lack of multidisciplinary team approach and deficiency of facilities needed for adequate diagnosis and treatment.

Yemen is a country with rich history and culture but political conflicts during the last four decades have caused severe economic downturn that negatively affected healthcare level. This article describes the experience of two Saudi

volunteering plastic surgeons with the rare forms of craniofacial anomalies that had to be treated according to the very limited local resources. It discusses the possible approaches to these malformations based on local resources in these underprivileged areas of the world.

PATIENTS AND METHODS:

This article represents the senior author's experience (Dr. Fadaak) in treating rare craniofacial anomalies in different Yemeni cities in 35 charity missions over a period of 15 years from 1997 to 2011. A total of 5100 plastic surgical procedures were done during this period, the majority of the cases were cleft lip and/or palate and post-burn contractures. Rare craniofacial clefts were met occasionally and a total number of 33 cases were seen during these visits with age range from 9 months to 29 years. Surgeries were done for 14 cases only. All diagnoses were based only on clinical examination and intraoperative findings. No imaging techniques were available before surgery. The spectrum of cases included syndromic craniosynostosis (Apert syndrome=3, Crouzon syndrome=2), proboscis lateralis (n=1), double upper lip deformity (n=1), holoprosencephaly (n=1), and a variety of rare Tessier clefts both isolated and mixed (n=25). Because of the conditions of charity missions, surgical treatment was always tried to be performed as a one-step procedure. Additional surgeries were discussed with the patients and families but none of the patients could be seen again except for one patient who had a second surgery during the same mission two weeks after the first

surgery.

The cases operated upon were registered by the local doctors before being evaluated by the visiting plastic surgeons. Lacking the experience in this field - as none of the visiting team was a craniofacial surgeon - and limited resources decreased the chance that patients would get the optimum management. The question at that time was either to do something to improve the way the patient look, feel and function or not to do anything being sure that these patients have almost no other chance for a better treatment. Out of the 33 patients he could operate only on 14 of them with the minimum soft tissue repair to give a better look making sure that the procedures fulfill the criteria of: shortest recovery, least donor site morbidity, compatible with our experience and the availability of local resources. No bony procedures were done for any patient. Augmentation, whenever needed, was done mainly through conchal grafts. The results were satisfactory and appreciable to the patient and family. For other patients who were not operated on, the reasons were different, most of the time they were seen late just before leaving with no available time to do surgeries for them, diagnostic investigations including imaging techniques were needed and not available or the abnormalities were not included in our experience and required other specialties or a team approach including specialized craniofacial surgeon and neurosurgeon. We present here a sample series of cases presented with rare craniofacial anomalies.

CASE (1)

25 years old male with wide Tessier cleft no. 1-13 with encephalocele. Nothing was done for the encephalocele, only soft tissue dissection and mobilization of the displaced nasal ala was performed to close the widely gapped cleft and give a better shape taking care not to touch the encephalocele sac (Figure 1).

CASE (2)

7 years old boy with Tessier cleft no. 4 involving both the bony skeleton and soft tissue coverage and associated microphthalmia and corneal opacification. The approach in this case included soft tissue repair only and was staged in two surgeries one at the start of the visit in which repair of the lip and cheek soft tissues was done and the second was performed two weeks later just before leaving and included lower lid dissection, elevation, suturing to the medial canthus and full thickness skin graft (Figure 2).

CASE (3)

15 years old male has abnormally elongated upper lip with horizontal constricting band affecting upper lip both cheeks and extending all the way to the ear lobule with the tissues above the band hanging over it giving the appearance of double upper lip. Vertical shortening was done via removal of a horizontal ellipse including the constricting lip band and the hanging tissue (Figure 3).

CASE (4)

3 years old girl presented with Tessier clefts 0-14 and left no. 1 cleft with anterior midline encephalocele and intercanthal skin tag. Single stage repair was done including direct repair of the lip, approximation of the nasal domes, direct repair of the cleft, and removal of skin tag (Figure 4).

Figure 1

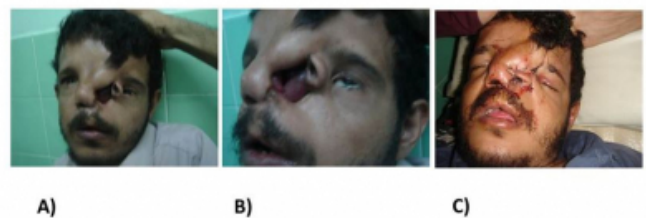

Figure 2

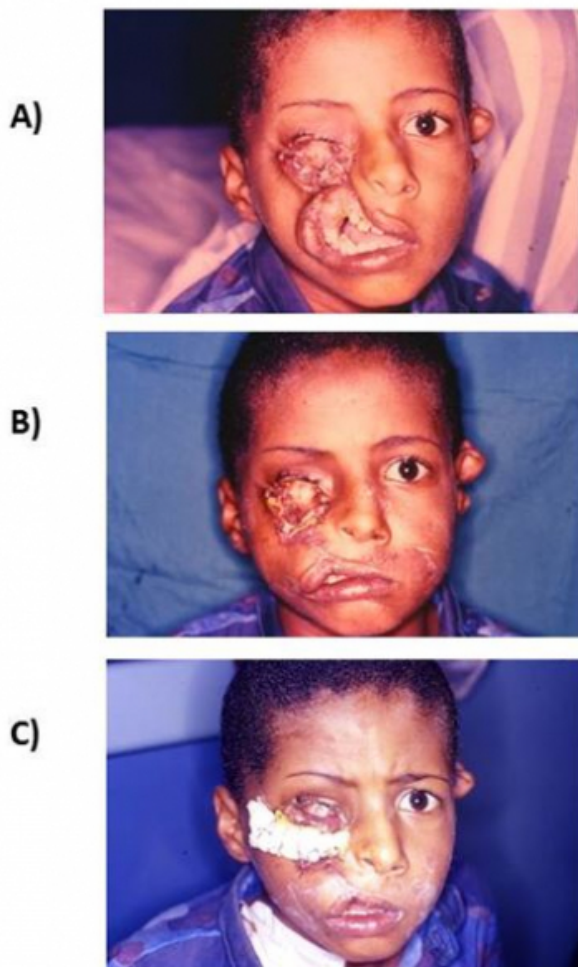

Figure 3

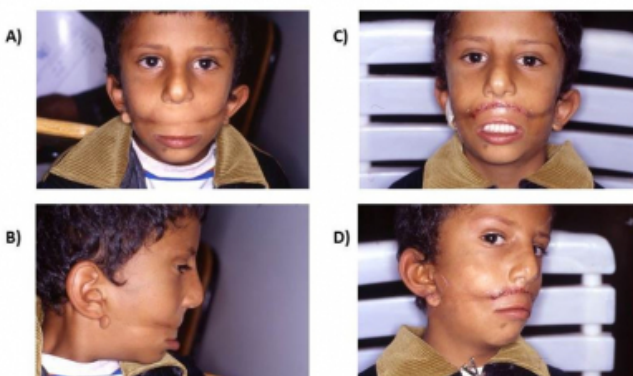
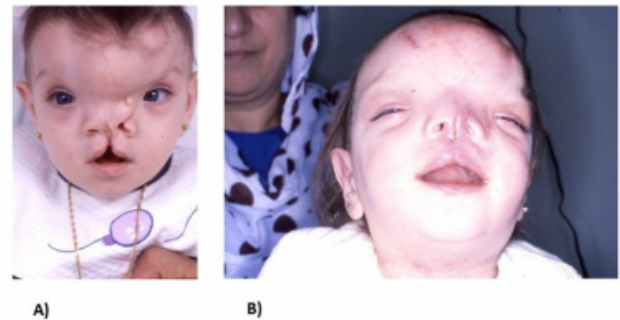


Figure 4



DISCUSSION

In many underprivileged countries, the options for individuals who require specialist interventions in plastic and other surgeries are limited and an unacceptable large percentage of population in the rural areas has no access to any form of surgical aid (6). Some countries have mechanisms to send patients abroad, but for the majority there is no service, and the individual is left to suffer the consequences of life-long disability, social exclusion. There are several options for alleviating the problem. One of these consists of visiting teams of experts working in collaboration with local clinicians to provide specialist treatment for specific conditions. The favorable impact of these efforts on the patients and families is obvious (1).

When he started his charity missions in 1997, there were only three plastic surgeons in the whole Yemen, two in Sana'a city the capital of Yemen and one in Aden and the majority of patients couldn't afford travelling abroad for treatment. He had to work in really difficult and challenging situations especially lack of resources (trained knowledgeable staff, basic setup and supplies). His first visit in 1997 was in Sayown city in Yemen, the only governmental hospital that hosted the mission showed lack of even the most basic requirements and he had to do his plastic surgeries on a regular wood table placed in a corridor in that small hospital, the patients went to surgery in their own clothes and all of that can be explained by knowing that the annual budget for the whole hospital is 30,000 Yemeni Riyals (\$137). With these tough situations and marked shortage of supplies he was sure that something has to be done for these underprivileged patients even if not optimal.

He has done a big number of cleft lip and palate cases with satisfactory outcomes. Meanwhile, he has been faced during these missions with less common craniofacial anomalies

most of them were rare facial clefts.

Unlike common cleft lip and palate anomalies, rare craniofacial clefts need much more complex diagnostic and treatment modalities. Because of their complexity, the individual degree of cleft formation, and the different structures and organs involved, successful reconstruction and rehabilitation in almost all cases demands full clinical and imaging assessment, multistep and multispecialty procedures (5).

All these requirements added to the rarity of volunteering specialized craniofacial surgeons and lack of local plastic surgeons to take care of the postoperative follow up added more limitations for optimal treatment of rare facial clefts in Yemen.

Transferring these children to experienced craniofacial centers has been considered the best way to give them the optimum care but the financial issues remained the main obstacle. Furthermore, one must consider that optimal treatment requires multi-stage reconstructive procedures at different ages of the children concerned. Consequently, treating those children abroad is limited to selected cases (4).

Dr. Fadaak here describes his experience in the one-step surgical treatment of these deformities during charity missions in Yemen. Apart from the surgical and anesthetic limits, there was a severe lack in diagnostic equipments and the diagnosis depended only on clinical examination and surgical exploration.

Surgical treatment focused on soft-tissue reconstruction while bony osteotomies and/or bone grafting were not options for many reasons including the lack of the appropriate instruments, unavailability of neurosurgeons and other specialties needed for team management of these complex disorders and the level of care required during the postoperative period in these patients after he leaves. One-stage pure soft-tissue repair achieved a distinct improvement in all cases while observing no severe complications. The immediate repair looks satisfactory with positive effect on the psyche of the patient and the family.

Depending on the degree of malformation, staged procedures are mandatory for many cases but this is always unavailable option for most of patients, the first operation would always be the biggest step on the way to achieving an optimal functional and aesthetic result. For children who were in need for further surgeries, he advised follow up and

communication during repeated visits of the team but he couldn't see any of them perhaps because of the financial problems that hindered them from following him in different Yemen cities or the degree of satisfaction they get after first surgeries.

No available data about postoperative complications in any of these patients. There are no means to contact them after end of the mission and they usually don't come back for follow up.

Dr. Fadaak has limited experience in surgical treatment of rare craniofacial clefts. However, for patients he operated upon, a clear improvement could be achieved even without major craniofacial surgery. For optimum aesthetic outcome, further complex craniofacial procedures would be necessary but this is unlikely to be done ever.

Our series certainly does not allow any conclusions about the incidence of the individual type of cleft, as the patients usually being presented during charity missions are part of a special selection of cases from that region.

He adopted very conservative approaches for repair of these deformities guided in decisions by certain facts including: lack of specialized craniofacial team, inability of the poor families to travel abroad, postoperative recovery and need for further follow up. For example, conchal cartilage grafts may not be the best choice for nasal dorsum augmentation compared to cranial bone and other reconstructive option but it has the least donor site morbidity if compared to other autogenous tissues and decreased risk of infection and extrusion and decreased cost if compared to synthetic materials, which all had to be considered in missionary treatment especially with lack of local plastic surgeons that can deal with postoperative possible complications. In other words, we offered community-based solutions to rarely encountered problems.

CONCLUSION

Based on the experiences described, it is suggested that, with initiative, effort and efficient organization of available facilities and resources, satisfactory results can be obtained through operating by regular plastic surgeon on patients with rare craniofacial anomalies in Yemen and other developing countries if specialized craniofacial team management is not possible.

References

Author Information

Tarek Abulezz, MD

Plastic Surgery Department, Sohag University
Sohag, Egypt
t_abulezz@yahoo.com

Hussein A. Fadaak, MD

Division of Plastic and Reconstructive Surgery, Department of Surgery, King Fahd Hospital and King Faisal University
Al-Khobar, Saudi Arabia
hfadaak@hotmail.com

Jamal Jadulkarim, MD

Division of Plastic and Reconstructive Surgery, Department of Surgery King Fahd Military Hospital
Jeddah, KSA