

Hemolymphangioma Of The Neck: A Rare Vascular Malformation In Children.

H C Rai, Krishnamoorthy, A Dayakar, Mahesh

Citation

H C Rai, Krishnamoorthy, A Dayakar, Mahesh. *Hemolymphangioma Of The Neck: A Rare Vascular Malformation In Children.* The Internet Journal of Pediatrics and Neonatology. 2013 Volume 16 Number 1.

Abstract

Hemolymphangioma is a rare, benign and non-invasive type of tumor. It occurs predominately in young patients, especially in newborns and infants and rare in adult's. It often arises from congenital malformation of vascular and lymphatic system. Very few cases of hemolymphangioma of the neck have been reported in literature so far. We are reporting the case of 7 year old female patient with slow growing swelling on the right side of the neck since 2 months, which was soft, fluctuant, non-tender and not fixed to the underlying structure. Histologically it consists of large multiple lymphatic vessels and also with numerous medium sized blood vessels. Based on clinical and histopathological findings a diagnosis of Hemolymphangioma was rendered.

INTRODUCTION

Hemolymphangioma is a rare, benign and non-invasive type of tumor. Hemolymphangiomas have been found in the pancreas, at the extremities, in the mediastinum, pericardium and on the tongue, as well as in the orbit, esophagus, retroperitoneally, adrenally, cervically, thoracically, hepatically and in the spleen. In addition, there are also reports of hemolymphangiomas in the skin, throat, stomach and scrotum¹⁸. However, very few cases of hemolymphangioma of the neck have been reported in literature so far.

Hemolymphangioma occurs predominately in young patients, especially in newborns and infants, and often arises from congenital malformation of vascular and lymphatic system. It is believed that hemolymphangioma is a benign disease without invasive ability⁴. Hemolymphangiomas are extremely rare and in most cases, detected at birth or within 2 years of life.

CASE REPORT

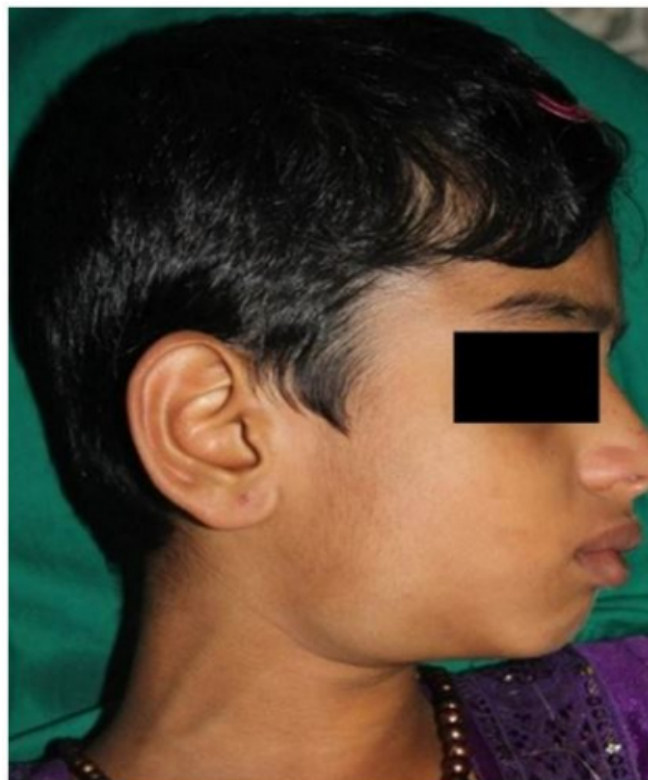A 7 year old female patient reported to our institution with a complaint of slowly growing swelling on the right side of the neck since 2 months. Parents have noted the swelling over the right side of the neck which was not associated with pain or any other symptoms.

Extra oral examination revealed an asymmetry on the right side of the neck. A solitary swelling measuring about 3X2cm was seen in the right submandibular region. The swelling

was oval in shape with well defined margins; skin over the swelling was not stretched. Transillumination was absent and it was soft, fluctuant, non-tender and not fixed to the underlying structure.

Figure 1

Photograph showing a solitary swelling in the right submandibular region.



Fine needle aspiration cytology was performed and it was reported as a cystic swelling. Ultrasonography revealed a cystic mass which was superficial to submandibular gland and not involving the gland. It was provisionally diagnosed as brachial cleft cyst.

Excisional biopsy was performed under general anaesthesia. Histopathologically it consists of connective tissue with large multiple cystic spaces lined by flattened endothelial cells filled with eosinophilic material or empty. Surrounding connective tissue was loose and contained numerous adipose tissues infiltrated with lymphocytes and plasma cells. Numerous RBCs filled spaces of varying sizes lined by endothelial cells were also observed.

Figure 2

Photomicrograph showing Large lymphatic vessels.

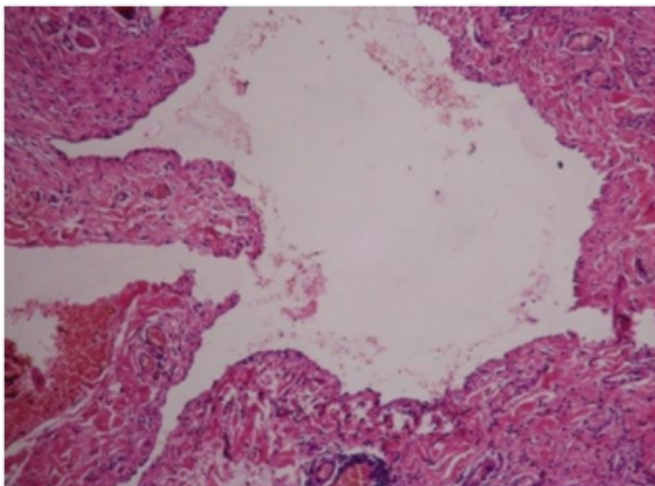
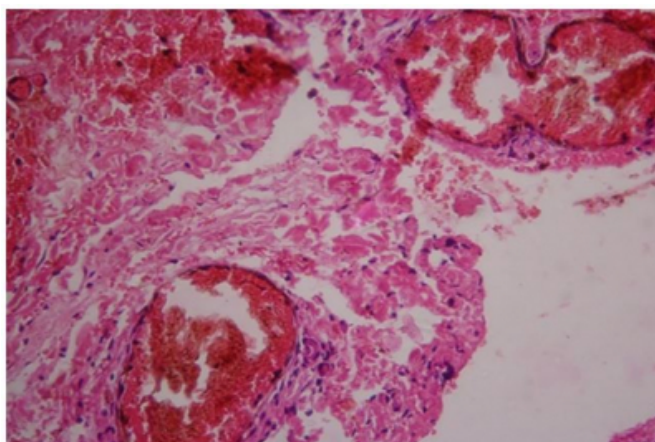


Figure 3

Photomicrograph showing numerous medium sized blood vessels.



Based on clinical and histopathological findings a diagnosis of Hemolymphangioma was rendered.

DISCUSSION

Lymphangiomas are a heterogeneous group of vascular malformations that are composed of cystically dilated lymphatics. These malformations can occur at any age and may involve any part of the body; however, 90% occur in children who are less than 2 years of age and involve the head and neck. These lesions are rarely found in adult patients^{19,1}. Lymphatic malformations are composed of endothelially lined lymphatic cysts that vary in size from a few millimetres to more than several centimetres in diameter⁹.

According to Landing and Farber, these benign malformations are classified into four categories: Capillary lymphangioma, cavernous lymphangioma, cystic lymphangioma (cystic hygroma) and hemolymphangioma (a combination of hemangioma and lymphangioma)¹⁸.

Based on studies correlating physical findings, natural history, and cellular features, there are two major types of vascular anomalies: tumors and malformations. Vascular tumors are endothelial neoplasms characterized by increased cellular proliferation. Hemangiomas are the most common and are almost exclusive to infants. Vascular malformations are the result of the abnormal development of vascular elements during embryogenesis and fetal life. These may be single formations (capillary, arterial, lymphatic or venous) or in combination. Vascular malformations do not generally demonstrate increased endothelial turn over; they are designated according to the predominant channel type as capillary malformations, lymphatic malformations, venous malformations, arteriovenous malformations, and complex forms such as capillary-lymphatico-venous malformations⁵.

Cystic hygromas are congenital vasculolymphatic malformations that are frequently present at birth. They have no predilection for sex or race, and they have no malignant potential. Typical cystic hygromas cause no symptoms unless they enlarge in size or surround or invade adjacent normal anatomic structures. In most cases, there is no difficulty in the diagnosis of cystic hygroma. A diagnostic dilemma may occur, however, if a cystic hygroma containing a suspicious vascular anomaly is seen in the lower neck or upper mediastinum. In this case, the vascular malformation should be differentiated from a thoracic duct aneurysm³.

Hemolymphangioma is thought to originate from the mesenchymal tissue. It may be divided into primary and secondary lymphatic vascular tumors. The primary tumor is considered

to be a congenital malformation of the lymphatic vascular system. The formation of this tumor may be explained by obstruction of the venolymphatic communication between dysembryoplastic vascular tissue and the systemic circulation. The secondary tumor is caused by poor lymph drainage and lymphatic damage resulting from surgery or trauma¹⁸. Banchini *et al* considered this tumor a congenital malformation of the vascular system²⁰.

The incidence of hemolymphangiomas varies from 1.2 to 2.8 per 1000 newborns, and both genders are equally affected. The diagnosis in most cases (90%) is made before the age of two, 60% of those patients display symptoms at the time of birth¹⁹. These lesions are rarely reported in adults¹⁰.

Imaging modalities, Ultrasonography, Computed Tomography and Magnetic Resonance, are useful in confirming the diagnosis, describing the margins of the mass and planning the surgical strategy. The ultrasound, that is a low cost modality, may demonstrate the solid or cystic nature of the lesion, therefore should be ordered in a routine base; the extension and the relationship of the tumor to the surrounding tissues is rather depicted by the MRI⁶.

Radiologic documentation is best performed by magnetic resonance imaging where lymphangiomas are characterized by the absence of feeding vessels and lack of intense contrast enhancement. Hemolymphangiomas like lymphangiomas and most vascular malformations demonstrate hyperintense signal intensity on T2-weighted and turbo short T1 inversion recovery images. The masses demonstrate peripheral and septal enhancement after administration of gadolinium⁵.

The formation of the tumor may be explained by obstruction of the venolymphatic communication, between dysembryoplastic vascular tissue and the systemic circulation. Hemolymphangiomas are mostly presented as cystic or cavernous lesions⁶.

The clinical onset of hemolymphangiomas can vary from a slowly growing cyst over a period of years to an aggressively enlarging but non-invasive tumor. Their size varies based on the anatomical location and relationship to the neighbouring tissues. Small tumors are usually superficial, whereas the larger ones are located in deeper layers and have a cystic texture. The most common complications are spontaneous or traumatic haemorrhage, rupture and infection. Lymphocytopenia has been documented in all these patients⁸. On physical examination, the tumors are usually palpated as soft and compressible

masses^{19,6,13}. Because of their soft, yielding consistency, they seldom produce symptoms¹⁴. It may occur in association with chromosomal anomalies, cardiovascular, pulmonary and musculoskeletal disorders³.

Enlargement of these lesions is common and may compress the adjacent organs, causing respiratory distress, feeding difficulties, or vascular compromise.[3]Difficulty in swallowing results from lesions extending to involve the oral cavity, oropharynx, and/or the hypopharynx. Isolated tongue involvement can lead to macroglossia with dysphagia and airway obstruction².

The differential diagnosis includes several conditions of the neck, presenting as soft, compressible mass like thyroglossal cyst, benign cystic lymph node, lipoma and plunging ranula¹⁶.

Microscopically, the tumor consists of abnormal blood and lymphatic vessels with polycystic spaces. These cysts have connective septa covered by endothelium⁴. They also consist of dense fibrous tissue that grows in bands between the numerous vascular spaces and invades the subcutaneous fat. Some of those are blood vessels, while others are lymphatic⁵.

Takahashi *et al.* demonstrated that during the proliferating phase, many growth factors such as vascular endothelial growth factor, basic fibroblast growth factor, proteases, and E-selectin (an adhesion molecule), may be involved⁵.

Observation is frequently the first step for small, non expanding lesions. Those that persist, continue to grow, or present with obstructive symptoms should be resected. To avoid injuring adjacent neurovascular structures, surgical planning is crucial before resection. Some surgeons prefer to use MRI to facilitate resection because it allows improved anatomical demarcation. Ultrasonography has limited ability to delineate the anatomical planes of resection or the extent of structural involvement¹¹.

Complete surgical excision is the treatment of choice. In case of inaccessible sites like base of the tongue, floor of mouth, larynx, neurovascular structures of neck, mediastinum and recurrent and residual tumors, intralesional injection of sclerosing agents have been tried before surgery. Commonly used agents include 25% dextrose, hypertonic saline, bleomycin, aethoxysklerol, OK-432 (picibanil)^{15,17}.

OK-432 (lyophilized incubation mixture of group A streptococcus pyogenes of human origin) have been used as an alternative treatment with promising results. It has been

suggested that OK-432 can be used alone as a primary therapy or after partial surgical excision, or in recurrent lymphangiomas. Other non-surgical treatments, including cryotherapy, laser therapy and radiotherapy are used. Radiotherapy by radium, roentgen ray or radon seed is done. Radiotherapy is used when surgical excision is not feasible; the radio-sensitivity of hemo-lymphangiomas is not well understood, however in the past they were considered to be radio-resistant. In children, radiotherapy may lead to tumor retardation or to malignant transformation⁶. But compared to surgical treatment, they do not show superiority; therefore, surgical excision remains the first choice of treatment to reduce the recurrence¹⁸. The risk of

recurrence or metastasis seems very low, but careful follow-up is necessary⁷.

CONCLUSION

Vascular malformations are the result of the abnormal development of vascular elements during embryogenesis and fetal life. These may be single formations (capillary, arterial, lymphatic or venous) or in combination. Cystic hygroma of the neck predominantly contains lymphatic vessels, but if equally presenting with more blood vessels then we should consider it more specifically as hemolymphangioma.

References

Author Information

Harish C Rai

Department Of Oral And Maxillofacial Pathology KVG Dental college and Hospital
Karnataka, India
hrishrai@gmail.com

Krishnamoorthy

Department Of Pedodontics KVG Dental college and Hospital
Karnataka, India
kmoorthysh21@gmail.com

Anitha Dayakar

Department Of Oral And Maxillofacial Pathology KVG Dental college and Hospital
Karnataka, India
anitadayakar99@gmail.com

Mahesh

Department Of Oral And Maxillofacial Pathology KVG Dental college and Hospital
Karnataka, India
rao7976@gmail.com