

Metaplastic Meningioma With Extensive Cartilaginous Transformation : A Diagnostic Dilemma

J Onen, O Coulibaly, S Derraz, A Harmouch, S Sefiani, A El Ouahabi, A El Khamlichi

Citation

J Onen, O Coulibaly, S Derraz, A Harmouch, S Sefiani, A El Ouahabi, A El Khamlichi. *Metaplastic Meningioma With Extensive Cartilaginous Transformation : A Diagnostic Dilemma*. The Internet Journal of Neurosurgery. 2013 Volume 9 Number 2.

Abstract

Meningiomas are the most common extraaxial central nervous system tumours often discovered in middle to late adult life and especially in women. About 85-90% of meningiomas are benign, 5-10 % are intermediate grade, and 3-5% are malignant. Metaplastic meningioma is a rare subtype of WHO grade I meningioma histologically characterized by the presence of mesenchymal components. The presence of pure and extensive cartilaginous differentiation in meningiomas is extremely rare and remains a diagnostic dilemma. We report a case of this entity in a 52 year old woman and discuss the pathogenesis, the imaging features and the histopathological data.

INTRODUCTION

Meningiomas are the most common extraaxial central nervous system tumours often discovered in middle to late adult life and especially in women and account approximately for 15-30 % of all intracranial tumours (Uygur Er, Doğa Gürkanlar , Atilla Kazanci et al., 2006; Markus et al., 2006). They are usually benign in about 85-90%, atypical in 5-10 % and malignant in 3-5% with characteristic pathologic and imaging features (Black et al 2007). Most patients in whom the diagnosis is suggestive of meningiomas undergo a surgical resection to relieve neurological symptoms, and the diagnosis sometimes remains difficult despite appropriate histological studies. Metaplastic meningioma is a rare subtype of WHO grade I meningioma histologically characterized by the presence of mesenchymal components, including osseous, lipomatous, myxoid or xanthomatous and cartilaginous tissue. The presence of extensive cartilaginous differentiation in this entity of meningiomas is very uncommon. We discuss herein the diagnostic dilemma in this kind of meningioma.

CASE REPORT

A 52 year old woman, followed for diabetes type II on nutritional regime, had been admitted in our department for a 10 year history of isolated headaches for which she opted for self medication by analgesics. Due to persistence of the headaches ,despite analgesic therapy, she sought medical

help in our department to ascertain the probable underlying cause. On admission, neurological examination was normal (no deficit and no papilledema on ophthalmological exam). A brain CT scan was done , which revealed a left parietal spontaneously hyperdense and heterogeneous lesion with no significant modification following contrast injection and suggestive of dural and bone infiltrations(Fig.1). Cerebral MRI to refine the radiologic diagnosis complemented these data. Axial, sagittal and coronal contrast enhanced T1W MRI showed the same heterogeneous lesion not much modified by Gadolinium injection with probable dural and bone thickening and without brain edema or midline shift (Fig.2).Our initial diagnosis basing on the radiological appearances was parietal convexity meningioma or intracranial tuberculoma. She underwent a left craniotomy centred on the lesion that permitted an “en bloc” resection of this tumour together with the overlying dura (Simpson’s grade I). Intraoperatively, the lesion was yellowish, firm with a very good plain of cleavage, and a very loose dural attachment, leaving a cavity that was in conformity to the shape of the lesion and measuring 4.5 cm × 2.5 cm × 1.5 cm (Fig.3). Extemporaneous histopathological examination was in favour of a cartilaginous tumour. These histological data were accepted with difficulty by our team and we recommended extensive studies in order to properly confirm the diagnosis. Finally, the diagnosis of metaplastic meningioma with extensive cartilaginous transformation was

made after HES staining (Fig.4). Postoperative CT and MRI scans revealed no residual tumour (Fig.5). She was discharged from hospital without neurological signs 08 days after surgery and is symptom-free 12 months following surgery.

Figure 1

non contrasted CT scan image of the brain, showing the meningioma in the left prerolandic area(hyperdense lesion), with evidence of hyperostosis on the bone window.

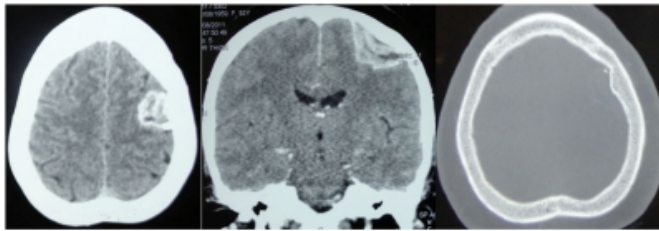


Figure 2

non contrasted T1WI MRI showing a hyperintense heterogenous lesion on axial ,sagittal and coronal planes respectively.

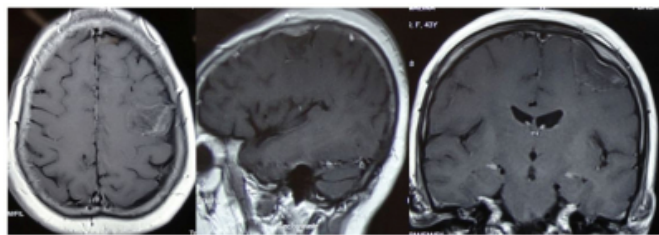


Figure 3

the operative view showing dimpling at the dural surface(a), parenchymal remodelling , conforming to the tumour shape(b), removed tumour specimen(c).

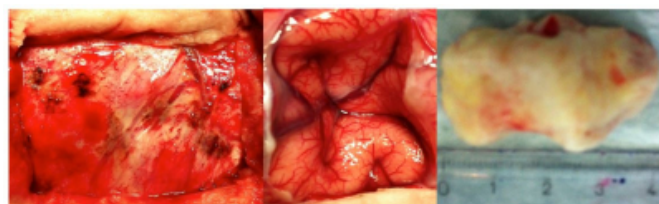


Figure 4

(a) HES X100, chondroid tissue sheltering (surrounding) arachnoid proliferation (see black arrow),(b) HES X400, arachnoid cells with pseudo inclusions wound in clusters(see black arrows), (c) regular chondroid tissue.

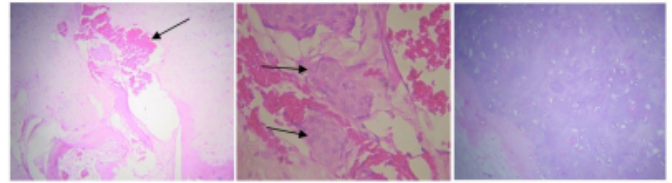
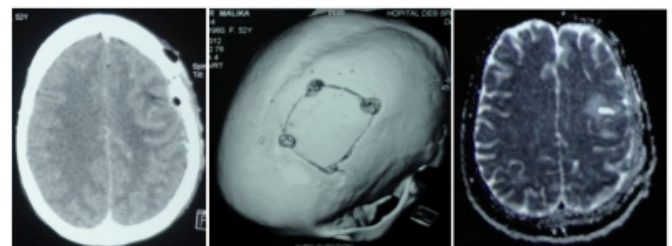


Figure 5

postoperative CT scan showing no residual tumour(a), bone-flap on bone window(b) and MRI to the extreme right(c)



DISCUSSION

Tumours derived from “meningeal cells” were described in the older medical literature under several names, depending on their source and published as psammoma, dural sarcoma, dural endothelioma, fibrosarcoma, angioendothelioma, endotheliosis of the meninges, meningeal fibroblastoma, meningoblastoma, mestothelioma of the meninges, and others (Cushing H, 1922; Cushing et al., 1938). But in 1922, Harvey Cushing (1869-1939) had been the first to propose the term “meningioma” to describe these tumours in order to end a series of appointments of names (Cushing H., 1922). Meningiomas are the most common primary extra-axial intracranial tumours and represent one-third of all such tumours (Wiemels J. et al., 2011). They exhibit a wide spectrum of microscopic appearances and capacity for mimicking the histological features of other neoplasms (Keppes JJ, 1986). They are almost predominantly benign, slow growing lesions and constitute 15%- 30 % of all intracranial tumours (Louis DN et al., 2007). They occur two to three times more commonly in women between 40 and 70 years old.Regarding their capability to express both mesenchymal and epithelial characteristics, the 1993 WHO classification of the tumours of the meninges recognized some histological variants of meningiomas from which the metaplastic meningioma was listed (Lopez MBS et al., 1993).

The current WHO histopathological classification determines 15 separate histopathological variants of meningiomas that correspond with 3 grades of malignancy: typical or benign meningiomas (grade I), atypical meningiomas (grade II) or malignant meningiomas (grade III and IV) (Mahmood A et al., 1993; Kleihues P et al., 2000). This subtype of meningiomas called “metaplastic meningiomas” and rated as WHO grade I meningioma, refer to a group of tumours marked histologically by the presence of focal or widespread mesenchymal differentiations or components, including osseous, cartilaginous, lipomatous, myxoid or xanthomatous tissue (Kleihues P et al., 2000 ; Tang H et al, 2013). These morphological and histological changes in meningiomas pose therapeutic challenges to neurosurgeons ,oncologists and pathologists; that is why it is useful to have a prompt diagnosis before therapy in this group in order to tailor treatment to the individual patient needs. Metaplastic meningioma with extensive cartilaginous transformation is very uncommon. According to our knowledge and basing on the literature review, no other case of convexity meningioma like ours has been published before. Ijiri R et al; 2000. Reported a case of spinal cartilaginous meningioma in a 13 year old child and also highlighted the rarity of this particular entity of meningiomas.

The mechanism of cartilaginous transformation in these meningiomas is still unclear and debated. However, some hypotheses about the pathogenesis of these metaplasias should be discussed. Willis RA in 1967 argued that meningiocytes are mesenchymal in origin. Multipotent mesenchymal cells have the ability to differentiate into fibrous, mucoid, adipose, synovial, meningeal, cartilaginous, osseous, hematopoietic, vascular, or reticuloendothelial tissues and may inappropriately respond to an unknown stimulus (precursor) to produce a metaplastic meningioma. Awadesh et al. in 2011 reported that metaplasia is a reversible change in which one adult cell type is replaced by another adult one. This may represent an adaptive substitution of cells. This implies that arachnoidal cap cells, from which meningiomas arise, may undergo gradual transformation into other cell types such as fat, bone, cartilage and myxoid tissue. But this variant differentiation has no prognostic significance (Roncaroli F, Scheithauer B W, Laeng R H et al. 2001).

Despite all these explanations, we are not able to confirm why these metaplastic changes occur in some meningiomas and not in others. Jing Xiang Hung et al. (2011) also

proposed that to date it is not known how these metaplastic changes occur. The clinical features found in our patient are similar to those in other patients bearing a meningioma in this location, but the radiological finding somewhat differed from that in the other typical meningiomas, thus the preoperative diagnostic difficulties it posed. This is why, the authors thought of other differential diagnoses before surgery. Our patient was successfully operated with gross total removal. These data are supported by Ulivieri S. et al. (2008) who argued that, the imaging data and a surgical strategy had to always be valued and used. Tang H et al; 2013 treated all their 15 patients harbouring metaplastic meningiomas surgically with complimentary radiotherapy in some of them.

Histologically in our case, there was essentially a pure and regular cartilaginous tumour proliferation with focal clusters of meningeal cells with rounded nuclei containing intranuclear inclusions and clear scanty cytoplasm.

Becker et al. (1999) also described a typical meningothelial meningioma from which numerous cartilaginous islands and some chondroid regions, obviously of intermediate (meningothelial / cartilaginous) differentiation could be seen.

However, Jing X H et al. (2011) described a case of an intracerebral metaplastic meningioma with prominent ossification and extensive calcification. Meningiomas with a pattern corresponding to at least two rare histological variants (secretory and lipomatous components or chordoma-like and chondroma-like structures) have been sporadically reported (Matyja E et al., 2005; Matyja E. et al., 2006). In our knowledge, our case is the only published cerebral convexity metaplastic meningioma to be of extensive cartilaginous differentiation.

These extensive cartilaginous metaplasias are very unusual but have similar prognostic behaviour to the other subtypes in-group I.

It is unfortunately true that “tumours from meningeal cells” now called meningiomas had been outlined since the sixteenth century; but they continue to be a challenging environment in the neurosurgeon’s daily activities ,especially with the constant changes in classification and the arrival of new histological subtypes. Metaplastic meningiomas just like the other subtypes in grade I, generally have a low or delayed rate of recurrence or aggressive growth. Tang et al 2013 had a recurrence in 2 of

their 15 patients treated for metaplastic meningioma and agrees that the prognosis of this histologic subtype is good. Research is still pending to answer the many questions that surround metaplastic meningiomas.

CONCLUSION

Metaplastic transformation in meningiomas may follow a long-standing tumour (meningioma) development, which denotes a change from arachnoid to mesenchymal components. How much time it takes for these metaplastic changes to commence, is unknown. After this transformation, it is not clearly known the state of events that follow. As was the case with our patient, it is possible that the lesion remained stable thereafter. These lesions pose a diagnostic dilemma on standard brain imaging techniques. Till presently, there is no clear-cut therapeutic protocol, but proponents for surgical strategy abound. Therefore, we do feel that future research is required to unravel the mystery that surrounds this particular type of metaplasia and whether it does harbour the possibility of evolving, toward malignancy or stability. For the moment, radical resection remains the rule.

Disclosure : The authors have no personal financial or institutional interest in any of the drugs, materials, or devices described in this article.

Acknowledgment : We would like to thank *MrsBarry Najah* for her support for this manuscript.

References

- 1) Awadhesh Kumar Jaiswal, AnantMehrotra ,Brijesh Kumar, SushilaJaiswa, MukulVij, Sanjay Behari , Lily Pal. Lipomatous meningioma: A study of five cases with brief review of the literature. Brief report Y 2011/ vol 59/issue/ page 87-91.
- 2) Becker C, KuchelmeisterK, Richter HP, Schachenmayr W. Metaplastic meningioma with cartilaginous differentiation. Pathologie 1999 nov ; 20(6): 335-9.
- 3) Cushing H. (1922).” The meningiomas (dural endotheliomas): their source, and favoured seats of origin”. Brain (45): 282-316.
- 4) Cushing, HL, Eisenhardt L: Meningiomas: Their Classification, Regional Behavior, Life History and Surgical End Results. Springfield IL, Charles C. Thomas, 1938.
- 5) Jing Xiang Huang, Fredrik Peterson , Intracerebral Metaplastic meningioma with prominent ossification and extensive calcification (rare tumours 2011; 3:e 20).
- 6) Kepes JJ. Presidential address: the histopathology of meningiomas. A reflection of origins and expected behavior ? JNeuropathol Exp Neurol 1986; 45: 95-107.
- 7) Kleihues P, Cavenee WK. World Health Organization. Classification of Tumours. Pathology & Genetics. Tumours of the Nervous System. IARC Press, Lyon 2000; 175-192.
- 8) Lopes MBS, VandenBerg SR, Scheithauer BW. The World Health Organization classification of nervous system tumours in experimental neuro-oncology. In A.J. Levine and H.H. Schmidek, eds. Molecular Genetics of Nervous System Tumors Wiley-Liss, New York, pp. 1-36, 1993.
- 9) Louis DN, Ohgaki H, Wiestler OD,Cavenee WK : WHO Classification of Tumours of the Central Nervous System. 4th Edition, International Agency for Research on Cancer, Lyon 2007.
- 10) Mahmood A, Caccamo DV, Tomecek FJ. Atypical and malignant meningiomas. A clinicopathological review. Neurosurgery 1993;33: 955-63.
- 11) Matyja E, Nagalska E, Zabek M, Jagielski J. Meningioma with the unique coexistence of secretory and lipomatous components: a case report with immunohistochemical and ultrastructural study. Clin Neuropathol 2005; 6: 257-261.
- 12) Matyja E, Grajkowska W, Lazarczyk M, Marchel A, Czernicki T. Chordoid meningiomas of a different histopathological pattern: a report of two cases. Folia Neuropathol. 2006;44 (1):34-41.
- 13) Roncaroli F, Scheithauer B W, Laeng R H, Cenacchi G, Aleff P A, Moschopoulos M. Lipomatous meningioma. A clinicopathologic study of 18 cases with special reference to the issue of metaplasia. The American Journal of Pathology 25(6): 769-775, 2001.
- 14) Tai HC, Chen CJ, Chen CM, Chen WL, Chen PY (2010) Ossified Metaplastic Meningioma with Intratumoral Hemorrhage. J Cytol Histol 1:102.doi: 10.4172/2157-7099.100010.
- 15) Olivieri Simone, Oliveri G. Lipidised faux meningioma: case report AJNS 2008 vol 27, No 1.
- 16) Uygur Er1, Doğa Gürkanlar2, Atilla Kazancı1, Serkan Şimşek1, Murad Baybek1. Lipomatous meningioma: Case report and diagnostic pitfall. Turkish Neurosurgery 2006, vol:16, No 1, 40-43.
- 17) Wiemels J, Wrensch M, Claus EB. Epidemiology and etiology of meningioma. J Neurooncol.2010 Sep;99(3):307-14. doi: 10.1007/s11060-010-0386-3. Epub 2010 Sep 7.
- 18) Willis RA: Pathology_of_Tumors ,ed 4.London :Butterworths, pp 658–662, 736–746,1967.
- 19) Ijiri R, Hara M ,Tanaka Y, Kato K, Sekido K: Spinal cartilaginous meningioma in a child: a case report; child's nerv syst: 2000 Feb; 16(2): 80-3.
- 20) Tang H, Sun H, Chen H, Gong Y, Mao Y, Xie Q, Xie L, Zheng M, Wang D, Zhu H, CheX, Zhong P, Zheng K, Lis S, Bao W, Zhu J, Wang X, Feng X, Chen X, Zhou L: clinicopathological analysis of metaplastic meningioma; report of 15 cases in Huashan Hospital: Chin J Cancer Res; 2013, Feb; 25(1): 112-8. Doi: 3978/j.issn. 1000-9604. 2013.01.10

Author Information

Justin Onen, M.D.

Department of Neurosurgery, Hôpital Des Spécialités, University of Mohammed V –Souisi
onenjustined@yahoo.co.uk

Oumar Coulibaly, M.D.

Department of Neurosurgery, Hôpital Des Spécialités, University of Mohammed V –Souisi

Said Derraz, M.D.

Department of Neurosurgery, Hôpital Des Spécialités, University of Mohammed V –Souisi

Amal Harmouch, M.D.

Department of Anatomic-Pathology, Hôpital Des Spécialités, University of Mohammed V –Souisi

Sanae Sefiani, M.D.

Department of Anatomic-Pathology, Hôpital Des Spécialités, University of Mohammed V –Souisi

Abdessamad El Ouahabi, M.D.

Department of Neurosurgery, Hôpital Des Spécialités, University of Mohammed V –Souisi

Abdellam El Khamlichi, M.D.

Department of Neurosurgery, Hôpital Des Spécialités, University of Mohammed V –Souisi