

Pneumomediastinum And Subcutaneous Emphysema In Acute Exacerbation Of Asthma: A Rare Presentation.

A Verma, K Singh, M Pannu, S Verma

Citation

A Verma, K Singh, M Pannu, S Verma. *Pneumomediastinum And Subcutaneous Emphysema In Acute Exacerbation Of Asthma: A Rare Presentation.* . The Internet Journal of Pediatrics and Neonatology. 2013 Volume 16 Number 1.

Abstract

INTRODUCTION

Mediastinal emphysema refers to presence of air within the mediastinum while subcutaneous emphysema refers to the presence of air in the subcutaneous tissue involving face, neck or trunk.^[1] The term pneumomediastinum, was introduced into medical literature by Hamman in 1939.^[2] Both the conditions are uncommon, but important complications of bronchial asthma. First such case was reported in a child in 1850, though Laennec in 1819 had recognised signs and symptoms of subcutaneous emphysema.^[3] We are presenting a case of pneumomediastinum and subcutaneous emphysema complicating an acute exacerbation of asthma in a child in order to sensitize pediatricians about the occurrence of this rare complication of bronchial asthma.

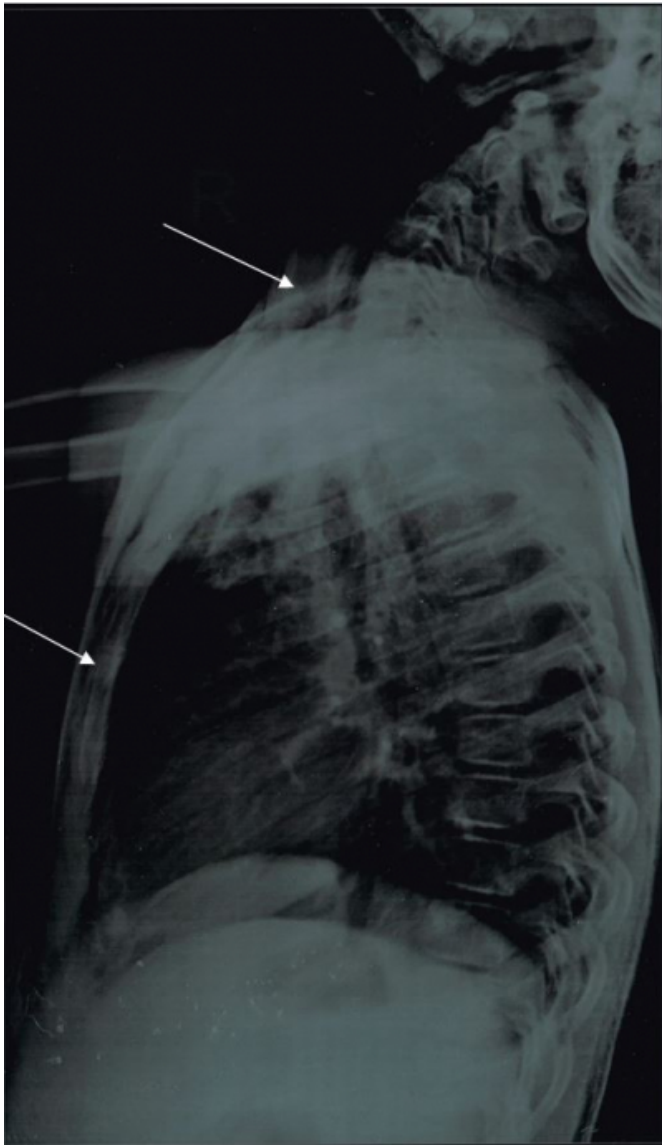CASE REPORT

A 9 years old known asthmatic female child presented to Emergency Department of Government Medical College, Amritsar with 2 days history of dyspnea, cough , cold and hoarseness. Patient had similar episodes of breathlessness since 2 years of age which responded to nebulisation with levosalbutamol. She was also noticed to have subcutaneous swelling and crepitus over the neck and upper anterior chest region, bilateral rhonchi with prolonged expiratory phase. She had a respiratory rate of 48/min, pulse rate of 118/min , BP 108/78 mm Hg and saturation on 100% O₂ was 98%. Other systems were normal. Her chest radiograph showed linear lucency in the region of left border of heart as well as areas of lucency in the subcutaneous tissue of the neck and anterior wall of chest. Laboratory findings showed haemoglobin 12 gm%, TLC 11,000/cumm and DLC 70% neutrophils, 22% lymphocytes , 6% eosinophils and 2% monocytes .

On the basis of history, examination and radiological findings a diagnosis of acute exacerbation of bronchial asthma with pneumomediastinum and subcutaneous emphysema was made. She was admitted in the ward and treated with oxygen by non rebreathing mask, nebulization with levosalbutamol and parenteral hydrocortisone. She made remarkable improvement with resolution of symptoms 2 days after admission. She was discharged after 7 days of hospitalisation in stable condition.

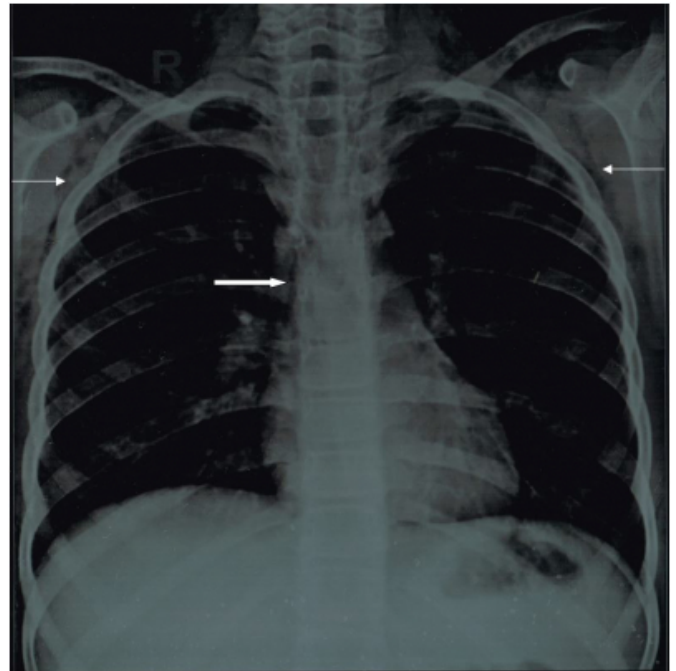
Figure 1

Thin Arrows Indicate Subcutaneous Emphysema



Asthmafig2

Thick Arrow Indicates Pneumomediastinum



DISCUSSION

Subcutaneous emphysema is a rare complication of acute severe asthma that may occur in association with spontaneous pneumomediastinum, pneumopericardium or pneumoperitoneum. Apart from asthma, extravasation of air in extrapulmonary tissues may also occur in perforation or rupture of oesophagus (Boerhaaves syndrome), rupture of trachea or main bronchi or other conditions producing raised intrathoracic pressure. Spontaneous pneumomediastinum may also be due to sudden rise in intralveolar pressure (cough, Valsalva manoeuvre, asthma, barotrauma, emesis) resulting in the rupture of marginal alveoli and subsequent tracking of air along bronchi, interstitial and vascular support tissue into the mediastinum. The itinerant molecules of oxygen may get to the pleural, pericardial and peritoneal spaces and the soft tissues of face, neck and upper trunk causing subcutaneous cervicofacialempysema. The escape of air out of alveoli results in ventilation perfusion mismatch and consequent abnormality of oxygenation of arterial blood. Other causes of extravasations of air into extra pulmonary structures include rapid ascent to the water surface after diving, dental extraction, adenoid tonsillectomies, bowel perforation, paraquat intoxication, arthroscopy and strangulation of the neck from hanging.^[4,5,6] Subcutaneous emphysema causes crepitus on palpation of affected body region but pneumomediastinum characteristically gives a positive Hamman's sign (crunching or clicking noise heard

synchronously with heart beat on auscultation) when it is clinically significant.^[2] Subcutaneous emphysema and pneumomediastinum may be associated with pneumorrhachis or air in epidural space. The air gone into the pulmonary perivascular interstitium may migrate along fascial planes from the posterior mediastinum(or retropharyngeal space), through the neural foramina, into the epidural space.^[7] In our case there were clinical and radiological evidence of subcutaneous emphysema but only a radiological evidence for the pneumomediastinum. Management of this condition is largely conservative. However administration of high concentration of oxygen may enhance faster absorption of air from extrapulmonary tissues while needle aspiration or surgical decompression may be useful if mediastinal structures are compressed.^[2,8]

CONCLUSION

Subcutaneous emphysema and pneumomediastinum constitute rare but very important complication of acute exacerbation of bronchial asthma and all amenable to conservative management. High index of suspicion is needed for making diagnosis and appropriate management in the

emergency department.

References

1. Maunder RJ, Pierson DJ, Hudson LD. Subcutaneous and mediastinal emphysema : pathophysiology, diagnosis and management. Arch Intern Med 1984;144:1447-53.
2. Hamman L. Spontaneous mediastinal emphysema. Bull John Hopkins Hosp 1939;64:1-21.
3. McGovern JP, Ozkaragoz K, Roett K, Haywood TH, Hensel Jnr AE. Mediastinal and subcutaneous emphysema complicating atopic asthma in infants and children; review of the literature and report of occurrence in an infant two years of age. Paediatrics 1961;27:951-60.
4. Inna K, Bartolome RC. Pneumomediastinum in a 63 year old woman with asthma exacerbation. Chest 2000;117:1778-881.
5. Shackelford D, Casani JA. Diffuse subcutaneous emphysema, pneumomediastinum and pneumothorax after dental extraction. Ann Emerg Med 1993;22:248-50.
6. Aghayev E, Yen K, Sonnenschein M et al. Pneumomediastinum and soft tissue emphysema of the neck in post-mortem CT and MRI ; a new vital sign in hanging? Forensic Sci. Int. 2005;153:181-8.
7. Manden PK, Siddiqui AH: Pneumorrhachis, pneumomediastinum, pneumopericardium and subcutaneous emphysema as complications of bronchial asthma. Ann Thorac Med 2009;4:143-5.
8. Corbridge TC, Hall JB. The assessment and management of adults with status asthmaticus. Am J Respir Crit Care Med 1995;151:1296-316.

Author Information

Anjali Verma, MBBS

Department of Pediatrics, GMC Amritsar

Karnail Singh, MBBS MD

Department of Pediatrics, GMC Amritsar

M. S. Pannu, MBBS MD

Department of Pediatrics, GMC Amritsar

Surender Verma, MBBS MS

Department of Surgery, PGIMS

Rohtak