

Bronchiectasis In Metaphyseal Acroscyphodysplasia With Cone-Shaped Epiphyses (Bellini Disease): A Five Years Follow Up

M Collura, F Pardo, F Ficili, A Ferlisi, F Serraino, A Costa, M Maggio

Citation

M Collura, F Pardo, F Ficili, A Ferlisi, F Serraino, A Costa, M Maggio. *Bronchiectasis In Metaphyseal Acroscyphodysplasia With Cone-Shaped Epiphyses (Bellini Disease): A Five Years Follow Up*. The Internet Journal of Pediatrics and Neonatology. 2013 Volume 16 Number 2.

Abstract

We present an adolescent with Metaphyseal acroscyphodysplasia (Bellini disease), characterized by severe short stature with accelerated bone maturation, micromelia predominating in the lower limbs, knee flexion, severe brachydactyly, very short hands and feet, metaphyseal changes and specific radiologic features, cup-shaped distal femoral metaphysis with cone-shaped epiphyses, short hands and feet, dental malocclusion. She presented chronic respiratory infections, with secondary bronchiectasis in the course of the follow up.

This is the first case reported in literature of a patient with this extremely rare metaphyseal dysplasia, the Bellini disease, associated with bronchiectasis.

INTRODUCTION

Skeletal dysplasias are a heterogeneous group of more than 200 disorders characterized by abnormalities of cartilage and bone growth, resulting in abnormal shape and size of the skeleton and disproportion of the long bones, spine, and head.

Many classifications have been suggested; classically they were based on pattern of involvement. Newer classifications are more often based on aetiology, i.e. genetic defects, abnormal proteins or enzymes.

Skeletal dysplasias are clinically expressed as a disproportionately short stature with:

1. short trunk
2. short limb:
 - a. rhizomelic – shortening of the root (proximal) portion
 - b. mesomelic – shortening of the middle portion
 - c. acromelic – shortening of distal portion
- ii. diastrophic – to grow twisted
- iii. camptomelic – bent limbs

Metaphyseal acroscyphodysplasia includes a category of metaphyseal dysplasias, characterized by specific radiologic features, associated with: mental retardation, severe short stature with accelerated bone maturation, micromelia predominating in the lower limbs, knee flexion, severe brachydactyly, very short hands and feet (1; 2).

Characteristic radiologic features include cup-shaped widening of the ends of the metaphysis; the lower femoral and the upper tibial epiphyses are embed in cone-shaped epiphyses involving the knees. Premature central epiphyse-metaphyseal fusion and gross deformation or coalescence of the femoral condyles occur. These metaphyseal chondrodysplasias are really uncommon.

We report a case of a female patient, presenting these specific metaphyseal and epiphyseal features, associated with short hands. She developed a chronic bronchopathy, with computed tomography scan of lungs showing bilateral bronchiectasis, a clinical presentation not previously reported in literature in association with Bellini disease.

CASE REPORT

We describe the case of an 11-years-old female, first child of healthy unrelated parents. She was born at term after a normal pregnancy. Her birth weight was 3,350 kg (50th percentile), her length was 50 cm (50th percentile) and

occipitofrontal circumference was 38 cm (> 90th percentile). No perinatal diseases were referred. During the following years she developed macrocrania with a slow height velocity. At the age of 3 years her stature was 83.7 cm (< -2 SDS) and her weight was 11.2 kg (< -2 SDS) (figure 1). She presented dysmorphic features, like reduced biparietal diameter, prominent frontal bossings, depressed nasal bridge, dental malocclusion and narrow chest. She also had short hands and feet. She showed micromelia of lower limbs and flexion deformity of knee joints (figure 1). She had no signs of ectodermal dysplasia. Lower limbs radiographs revealed cup-shaped distal femoral metaphysis with cone-shaped epiphysis and shortening of diaphysis (figure 2). Hands radiographic study showed cone-shaped epiphysis of the phalanges.

In course of follow-up she had an inadequate speech and psychomotor delay.

Furthermore the patient developed a chronic bronchopathy, with computed tomography scan of lungs showing bilateral bronchiectasis (figure 3 a). She had chronic cough and sputum production and she often presented fever. She needed a periodic pulmonary follow-up and she was treated with specific antibiotics, based on sputum specimens, antiinflammatory agents and airway clearance with PEP mask. She was vaccinated every year against influenza virus and, during the last five years of follow-up, she reduced bronchial infections.

A computed tomography scan of lungs after five years showed a failing progress of the bronchiectasis (figure 3 b).

Authors obtained a written consent from the patient parents for the use of the patient images and clinical data.

DISCUSSION

Our patient presented metaphyseal changes with specific radiologic features, characterized by cup-shaped distal femoral metaphysis with cone-shaped epiphysis, short hands and feet, dental malocclusion and chronic respiratory infections with bronchiectasis.

Metaphyseal acroscaphodysplasia was first described by Bellini and Bardare in 1966 (1). Only few cases have been reported with this type of metaphyseal dysplasia: the term acroscaphodysplasia describes the radiologic features (1-5). Furthermore a few cases of the disease associated with ectodermal dysplasia are described. These patients showed cone-shaped epiphyses involving the knee with metaphyseal

cupping of hand bones, cone-shaped epiphyses of phalanges, slender phalanges of normal length, advanced bone age and complete alopecia (5). Bellini et al. (2) described the syndrome in two siblings, suggesting the possibility of an autosomal recessive inheritance.

Recently three unrelated patients affected by metaphyseal chondrodysplasia with cone-shaped epiphyses, involving mainly lower limbs, without hands involvement, were described (4). A new case of a female patient was recently described: she presented dysmorphic features, like depressed nasal bridge, anteverted nares, dental malocclusion, narrow high arched palate, narrow chest, pigeon deformity and acromelic shortening. She showed disproportional short stature and radiologic features like cup-shaped distal femoral metaphysis with cone-shaped epiphysis, mild widening of the proximal metaphyseal end of the tibia and fibula and abnormalities of hand bones, including squat, shortened metacarpals and cone-shaped epiphysis of the phalanges, short vertebral peduncles and mild lumbar kyphosis. She had normal hair growth and distribution (3).

The association with bronchiectasis was not previously described in this rare syndrome. However a rare case of acromesomelic dysplasia with bilateral bronchiectasis and obstructive sleep apnoea was described by Farnaz et al. (6).

A possible link between the two conditions (skeletal dysplasia and bronchiectasis) could be found in the precocious onset of recurrent bronchial infections, documented in our patient.

In fact these patients show a progressive evolution of their thoracic deformities, secondary to vertebral malformations and kyphosis. These anomalies can trigger a secondary pulmonary dysventilation, with accumulation of bronchial secretions and difficulty to expectorate.

We described this case for the rarity of the disease and the unique association with bronchiectasis. Furthermore we stress the good clinical evolution of this patient who was followed with a good care (physiotherapy and strict monitoring of the respiratory involvement).

Figure 1

clinical features of the patient.

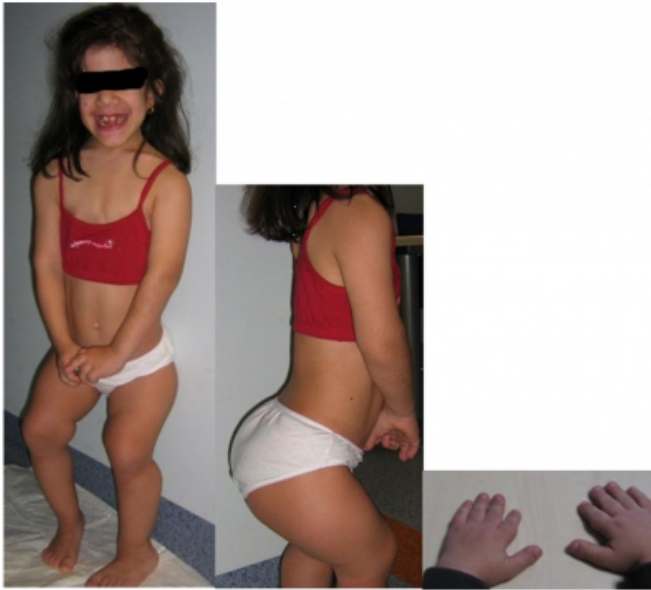

Figure 2

Total body X-ray image of the patient at the diagnosis.

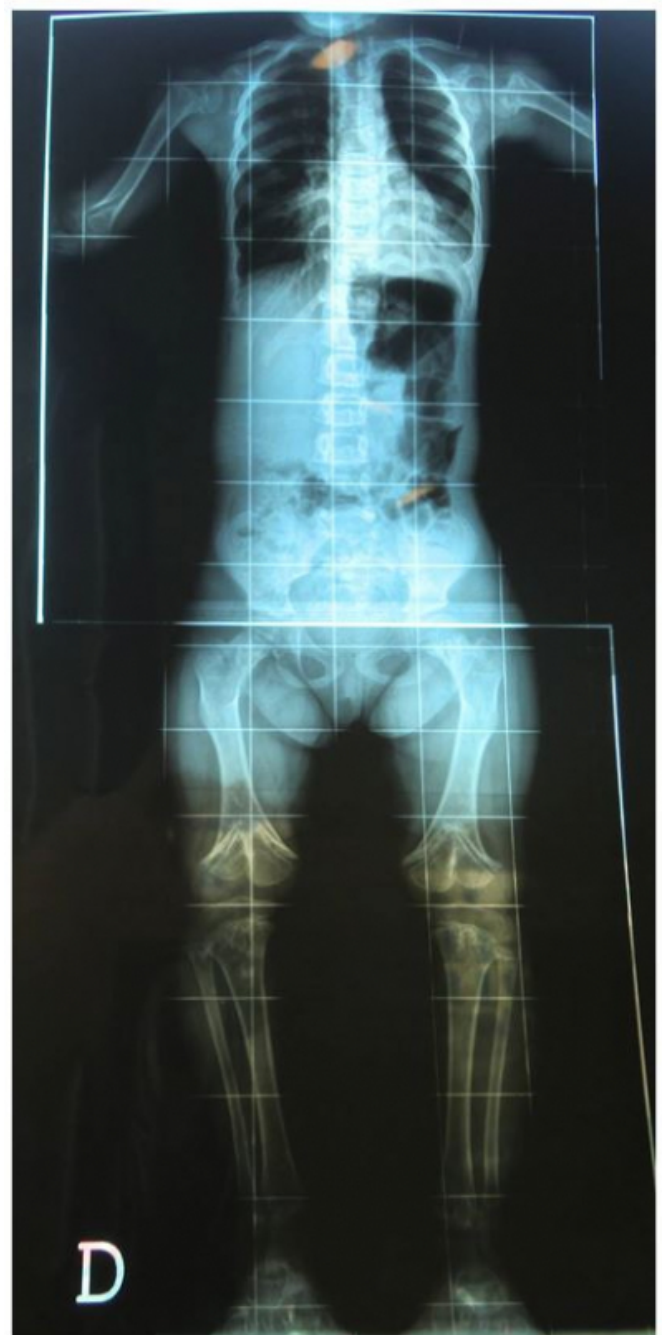
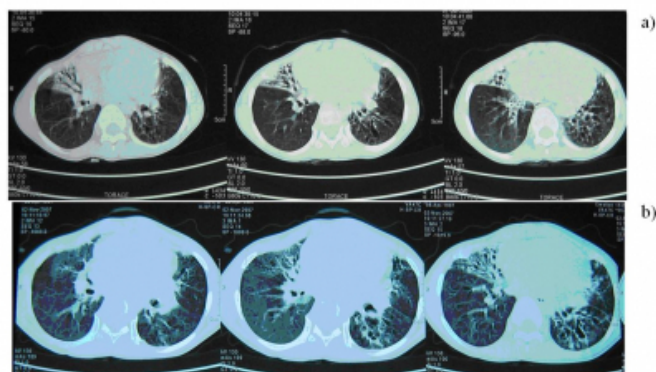


Figure 3

CT at the diagnosis of bronchiectasis (a) and after 5 years of follow-up (b).



References

1. Bellini F, Bardare M: Su un caso di disostosi periferica. [A case of peripheral dysostosis.] *Minerva Pediatr*; 1966; 18:106–110.
2. Bellini F, Chiumello G, Rimoldi R, Weber G : Wedge-shaped epiphysis of the knees in two siblings: a new recessive rare dysplasia? *Helv Paediatr Acta*; 1984; 39(4):365–372.
3. De Toni T, Baban A, Colombo E, Arnello A, Divizia M.T., Lerone M: Further case of acroscyphodysplasia with cone-shaped epiphyses (Bellini disease or metaphyseal dyschondroplasia). *Clinical Dismorphology*; 2008; 17: 275-278.
4. Dieux-Coeslier A, Moerman A, Holder M, Boute O, Maroteaux P, Manouvrier S, Le Merrer M: Metaphyseal chondrodysplasia with cone-shaped epiphyses: a specific form involving the lower limbs. *Am J Med Genet*; 2004; 124: 60–66.
5. Jequier S, Bellini F, Mackenzie DA: Metaphyseal Chondrodysplasia with Ectodermal Displasia. *Skeletal Radiol*; 1981; 7:107–112.
6. Farnaz S, Gothi D, Joshi JM: Acromesomelic dysplasia with bronchiectasis. *Indian J Chest Dis Allied Sci*; 2005; 47(2):131-4.

Author Information

M. Collura

Second Pediatric Unit - Regional Center for Cystic Fibrosis- Children Hospital "G. Di Cristina"-ARNAS
Palermo, Italy

F. Pardo

Second Pediatric Unit - Regional Center for Cystic Fibrosis- Children Hospital "G. Di Cristina"-ARNAS
Palermo, Italy

F. Ficili

Second Pediatric Unit - Regional Center for Cystic Fibrosis- Children Hospital "G. Di Cristina"-ARNAS
Palermo, Italy

A. Ferlisi

University Department "Materno-Infantile, di Andrologia e di Urologia", University of Palermo
Palermo, Italy

F. Serraino

University Department "Materno-Infantile, di Andrologia e di Urologia", University of Palermo
Palermo, Italy

A. Costa

University Department "Materno-Infantile, di Andrologia e di Urologia", University of Palermo
Palermo, Italy

M.C. Maggio

University Department "Materno-Infantile, di Andrologia e di Urologia", University of Palermo
Palermo, Italy