

A Case of Chronic Huge Scrotal Hematocele

T Klimis, I Alexandris, A Kyriakidis, K Athanassiou, M Pyrgioti, G Kyriazis

Citation

T Klimis, I Alexandris, A Kyriakidis, K Athanassiou, M Pyrgioti, G Kyriazis. *A Case of Chronic Huge Scrotal Hematocele*. The Internet Journal of Surgery. 2013 Volume 30 Number 4.

Abstract

An 86 year-old male consulted our department for examination of a huge left-sided scrotal mass which was focally painful. The patient had a history of trauma at the perineum 30 years previously.

Examination revealed marked swelling of the left side of the scrotum. The involved scrotal skin was focally inflamed (ulcerated). On investigation, we could not distinguish the left testis or epididymis from the mass by palpation. After admission, the serum levels of tumor markers (alpha-fetoprotein, carcinoembryonic antigen, β -human chorionic gonadotropin) were within normal limits.

U/S and MRI did not exclude a testicular tumor completely. As it was impossible to exclude a malignant tumor, especially testicular carcinoma, the tumor was resected by a left high orchiectomy. The histopathological diagnosis was an organized hematocele, and the left testis was located separately from the mass, having normal appearance. This entity should be considered in the differential diagnosis of scrotal masses, even in the absence of a clear history of trauma.

INTRODUCTION

Hematocele is an accumulation of blood within the tunica vaginalis sac. Chronic hematoceles are rare scrotal masses. Possible causes most often include direct trauma of the scrotum, torsion, tumor and surgery. Large hematoceles distort the adjacent testis, leading to increased suspicion of malignancy, both clinically and sonographically¹⁻⁴. Since correct preoperative diagnosis is problematic unnecessary orchiectomy is not uncommon.

We report a case of chronic hematocele resembling testicular tumor, in an elderly patient.

CASE REPORT

An 86-year-old man presented with a left-sided scrotal mass which extended in the internal femoral region. The patient refers that he had been kicked in the scrotal area by a horse while plowing his farm 30 years ago. This injury caused severe pain and swelling of the scrotal area, which the patient treated by remaining at bed rest for several days. He related that the swelling of the left side of the scrotum had been persistent ever since.

The mass was asymptomatic, except for a local discomfort caused by its size. Last month prior to admission, the involved scrotal skin was locally inflamed (ulcerated) with

some degree of pain.

Physical examination revealed that the left side of scrotum was occupied by a large, hard, nontender mass, gradually increasing in size, measuring more than 20 cm. in diameter (fig.1). The mass did not transmit light. The left testis and epididymis could not be detected. Blood markers for testicular tumors such as human chorionic gonadotropin (HCG), alpha-fetoprotein (AFP) and carcino-embryonic antigen (CEA) were found to be within normal levels. The right lower extremity had a motor neuron paralysis as a neurologic residual of poliomyelitis.

Ultrasonography of the scrotum yielded suspicion of a testicular neoplasm, but could not conclude the diagnosis. Magnetic resonance imaging (MRI) revealed a well-defined encapsulated left solid mass with areas of septations and loculations(fig.2).

Left high inguinal orchiectomy was performed,since it was difficult to exclude completely a testicular tumor. It surgery, a well-encapsulated mass which consisted of a normal testicle surrounded by a thick-walled sac was discovered.

Grossly, the resected mass measured 22X16X8 cm in diameter and 1200 gr in weight.

It consisted of a cavity having a thick capsule,filled with old

brownish clotted blood (fig.3).

Figure 1

Gross photograph of the left hemiscrotal mass.

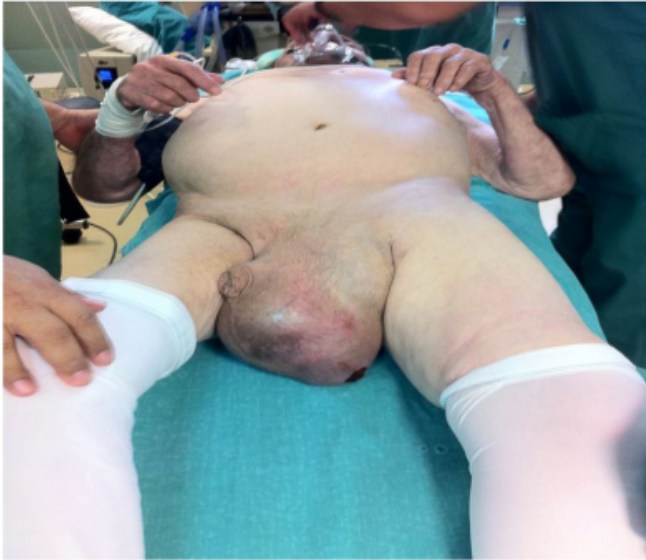

Figure 2

MRI revealed a well-defined encapsulated left solid mass with area of septations and loculations.

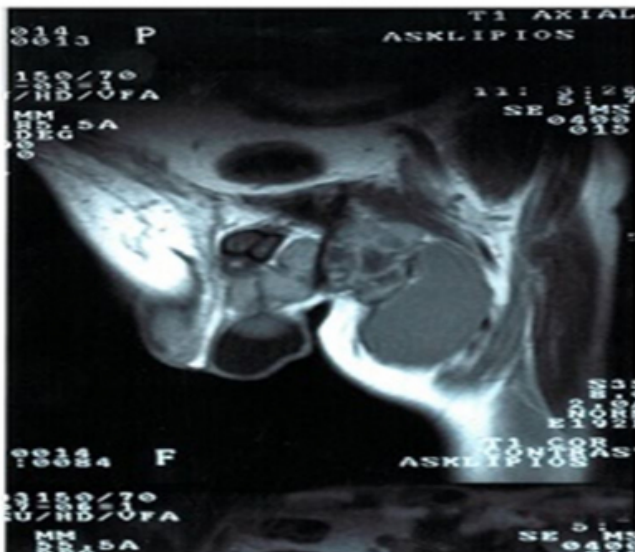
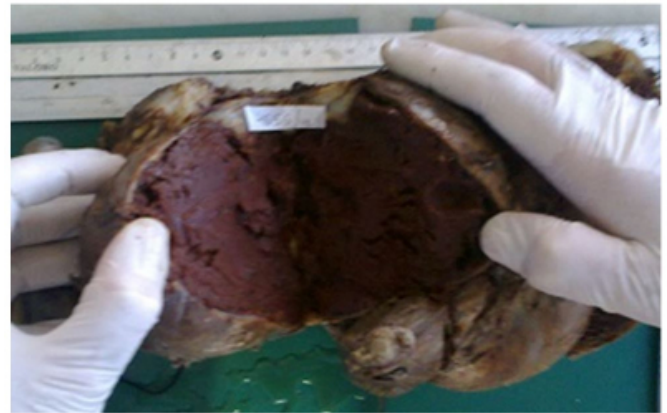


Figure 3

Gross photograph of the cut surface of the specimen showing a cavity that was filled with old clotted blood (hematocele).



Microscopically, a thickened hypocellular fibrous capsule that contained collections of amorphous eosinophilic material, cholesterol clefts and abundant macrophages, especially with hemosiderin pigment were seen. The testis showed extensive atrophy and was otherwise normal, without evidence of neoplasia. Varicocele was an associated finding. The pathological diagnosis was chronic organized hematocele. The postoperative course of the patient was uneventful.

DISCUSSION

Hematocele is defined as a collection of blood between the parietal and visceral layers of the tunica vaginalis that causes an increase in scrotal size.

Chronic hematoceles are rare scrotal masses. To our knowledge, less than 30 cases have been reported in the literature^{1,2,5,6,7,8,9,10}. The age of the patients was 38 to 77 years, with the mean age of 65 years¹⁰.

According to an etiological basis, hematoceles can be classified as idiopathic and secondary. Idiopathic or spontaneous hematoceles give a history of neither trauma to the testis, nor pain in the organ and seems to be more common in elderly patients^{1,9}. Hematoma is the result of blood leakage into the vaginal sac. Secondary hematoceles are usually associated with a history of a trauma to the scrotum, surgery in the surrounding area, or neoplasm. Non-traumatic secondary hematoceles can be produced by haematological alterations or vasculitis^{1, 5}. The etiology of hematocele in our case was a previous perineal trauma.

Hematocele is difficult to diagnose preoperatively because both clinically and sonographically may mimic testicular

neoplasms or cysts. This can happen in long-standing cases because of fibrous thickening with cholesterol granuloma formation in the tunica vaginalis. Testicle exploration shows a solid mass which grows slowly during many years. This gradual development of hematoceles is not unusual¹. In our case the hematocele enlarged slowly for more than 15 years. The dark brown color of the content showed that it had been present for a long time and thus corresponded to the history given by the patient. In the following years it reached gigantic size. The mechanism underlying the expansion of such hematomas is still unclear. Presumably minor trauma results in rupture of dilated microvessels beneath the fibrous capsule. In long-standing hematocele, like in our case, the tunica vaginalis becomes enormously thickened with dense fibrous tissue and hemosiderin-laden macrophages. At US, hematoceles appear as heterogeneous encapsulated extra testicular solid mass separated by septations and loculations^{3,4,11,12}. However, scrotal U/S often results in a false positive finding of malignant testicular neoplasms usually requiring orchiectomy³.

When U/S diagnosis is equivocal it is useful to perform MRI, which has a higher sensibility and allows clear demonstration of blood⁹. However, it cannot reliably differentiate benign from malignant pathology.

In our case, there was high suspicion of testicular neoplasm preoperatively because the testicle was compressed and pushed towards the periphery.

A differential diagnosis can also be made from malignant mesothelioma of the tunica vaginalis testis clinically and radiologically¹¹. The latter grows rapidly. Slow growth, as in our case, can be one finding for suspecting a benign lesion.

Since neither clinical symptoms nor sonographic findings were completely reliable in predicting the correct preoperative diagnosis, high inguinal orchiectomy was recommended. In the literature, only high inguinal orchiectomy was performed in patients with an intrascrotal cystic mass, as in our case, because it was difficult to exclude a testicular tumor preoperatively^{6,10,12}. Tumor resection

without orchiectomy has not been reported. The histopathologic examination contributed to the definitive diagnosis.

However, the presence of a clinical history of trauma in conjunction with a correct interpretation of U/S and MRI images before the initiation of surgical treatment, will obviate an orchiectomy, which is not always necessary. Surgical evacuation of the hematoma can prevent complications of a hematocele like compression of testis, abscess formation or necrosis, as unresolved hematocele can eventually be infected.

References

1. Leibovitch I, Ramon J, Ben Chaim, D. Nass & B. Goldwasser: Chronic hematocele complicating renal failure and hemodialysis. *J.Urol*; 1991; 146: 162-164.
2. Madan J, Madan U: Idiopathic chronic hematocele of the scrotum. *The Internet J.Surg*; 2007; 11(1):19
3. Garriga V, Serrano A, Marin A, Medrano S, Roson N & Pruna X: US of the tunica vaginalis testis: Anatomic relationships and pathologic conditions. *Radiographics*; 2009; 29: 2017-2032.
4. Dogra VS, Ronald H, Oka M, Rubens, Deborah J: Sonography of the Scrotum. *Radiology*; 2003; 227: 18-36.
5. Regueiro PD, Martinez Garcia de Jalon A, Boned TMA, Sancho Serrano C, Gracia Montolini S, Rioja Sanz LA: Idiopathic giant superinfected hematocele. *Actas Urol. Esp*; 2003; 27: 645-48.
6. Minagawa T, Hirabayashi N, Furuhashi M, Sato T, Okaneya T: Intrascrotal cystic mass mimicking a testicular tumor and review of the literature. *Acta Urol.Jpn*; 2006; 52: 311-314.
7. Aoki M, Ishikawa A, Ushijima T, Suzuki K, Fujita K: A case of chronic scrotal hematocele. *Acta Urol.Jpn*; 1995; 41: 817-19.
8. Jimenez Yanez R, Gallego Sanchez J A, Gonzalez Villanueva L, Torralbo G, Ardoy Ibanez F, Perez M: Chronic calcified hematocele. Case report. *Arch.Esp.Urol*; 2007; 60: 303-6.
9. Alvarez-Alvarez C, Luis A, Farina Perez, Celso R: Idiopathic chronic hematocele of the vaginal sac. *Int.Braz.J.Urol*; 2005; 31: 555-57.
10. Gohji K, Hasunuma Y, Takaqi S, Arakawa S, Matsumoto O, Kamidono S: A case of chronic hematocele and review of the literature. *Hinjokika Kyo*; 1992; 38:1413-1415.
11. Plas E, Riedl RC & Pfluger: Malignant mesothelioma of the tunica vaginalis testis: review of the literature and assessment of prognostic parameters. *Cancer*; 1998; 83: 2437-46.
12. Altarac S: Management of 53 cases of testicular trauma. *Eur. Urol*; 1994; 25: 119-123.

Author Information

T Klimis

Department of Pathology, General Prefectural Hospital "Polikliniki"
Athens , Greece

I. I. Alexandris

Department of General Surgery, General Prefectural Hospital
Amfissa , Greece

A.V Kyriakidis

Department of General Surgery, General Prefectural Hospital
Amfissa , Greece

K Athanassiou

Department of General Surgery, General Prefectural Hospital
Amfissa , Greece

M Pyrgioti

Department of Internal Medicine, Prefectural Hospital
Amfissa , Greece

G Kyriazis

Department of General Surgery, General Prefectural Hospital
Amfissa , Greece