

# Paget-Schroetter Syndrome

K Vagholkar, I Maurya, S Pandey

---

## Citation

K Vagholkar, I Maurya, S Pandey. *Paget-Schroetter Syndrome*. The Internet Journal of Emergency Medicine. 2013 Volume 8 Number 1.

## Abstract

Background: Paget Schroetter syndrome or venous thrombosis of the axillary subclavian axis is a rare condition often misdiagnosed as cellulitis by the primary care physician.

Case Report: A case of Paget Schroetter syndrome misdiagnosed as cellulitis by the primary care physician leading to delay in arriving at a definitive diagnosis and thereby commencement of treatment is presented.

Discussion: The anatomical and pathophysiological basis of Paget Schroetter syndrome along with various treatment options is discussed.

Conclusion: Awareness of this rare condition is essential for primary care physicians to avoid delay in diagnosis and treatment.

## INTRODUCTION

Deep vein thrombosis is commonly associated with the veins of lower limb. Thrombosis involving deep veins of upper extremity namely the axillary-subclavian axis or Paget Schroetter syndrome is quite uncommon. As there are ill defined predisposing factors and variable symptoms, diagnosis of venous thrombosis affecting the upper limb, always poses a dilemma leading to delay in commencing treatment. A case of Paget Schroetter syndrome (PSS) is presented along with a review of literature.

edema.

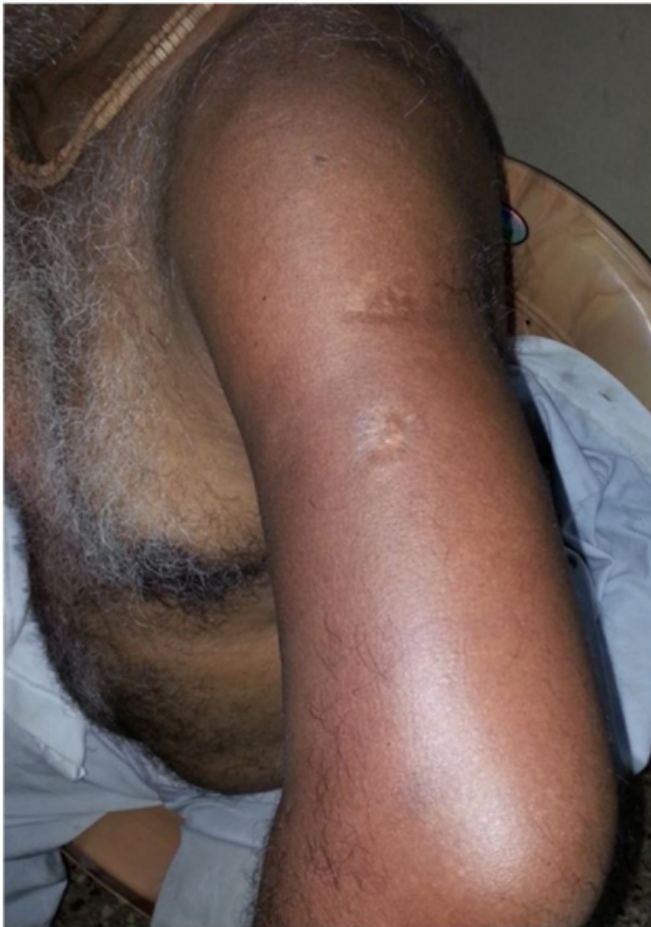## CASE REPORT

A 58 year old patient, a manual laborer by occupation was referred by his primary care physician with history of sudden onset of swelling of left arm and forearm accompanied by pain. Patient gave history of sudden onset of symptoms without any specific inciting cause. There was no history of fever. Patient was treated as a case of cellulitis by his primary care physician. The response to treatment was poor.

Physical examination revealed a grossly swollen and tender left upper extremity. (Figure 1) The swelling involved the left arm, forearm and hand. The movements of the shoulder, elbow and wrist joints were restricted due to edema and were extremely painful. There were no areas of softening or fluctuation anywhere over the affected extremity. There were no distal focal neurological deficits in left upper extremity. Peripheral pulses could not be appreciated due to

**Figure 1**

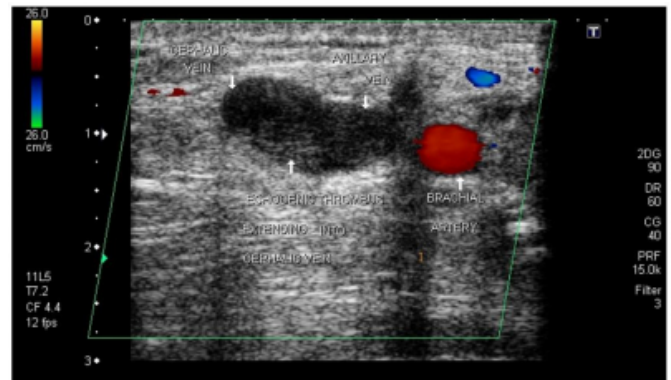
Extensive edema and redness of the left upper extremity.



A high index of suspicion for deep vein thrombosis was raised. A color Doppler was done which confirmed a non compressible echogenic thrombus involving the axillary vein and cephalic vein extending up to the venae comites of the brachial artery. (Figure 2) The arterial flow in the axillary artery was normal. (Figure 3) Anti-coagulant therapy was started immediately after confirmation of diagnosis. Heparin treatment was commenced and continued for period of 5 days during which there was significant regression of edema, redness, and pain. After 5 days of parenteral anticoagulant therapy patient was started on oral warfarin. There was complete regression of all symptoms within a span of two weeks. Anticoagulation therapy was continued for 6 months with no signs of recurrence.

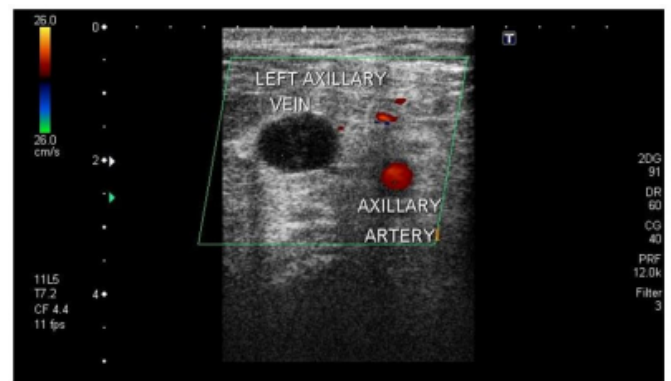
**Figure 2**

Color Doppler showing thrombosis of the axillary vein and cephalic vein.



**Figure 3**

Doppler showing normal flow in the axillary artery.



## DISCUSSION

Deep vein thrombosis in the upper extremity is quite rare as compared to the lower extremity. The condition can either be primary or secondary. [1] Primary deep venous thrombosis of the upper extremity is typically described as effort induced thrombosis. It is also called Paget Schroetter syndrome (PSS). Secondary causes are either following subclavian vein cannulation or due to malignancy. The traditional predisposing factors described for lower extremity venous thrombosis do not always hold true for the upper extremity. The typical post thrombotic syndrome is infrequently seen in the upper extremity. The morbidity associated with this condition is usually due to the associated co morbid conditions especially in the secondary type of disease.

Peculiar anatomical configuration of the veins draining the upper extremity as they enter the thoracic outlet predisposes them to develop deep venous thrombosis especially in Pager-Schroetter syndrome. [2] The subclavian vein passes over

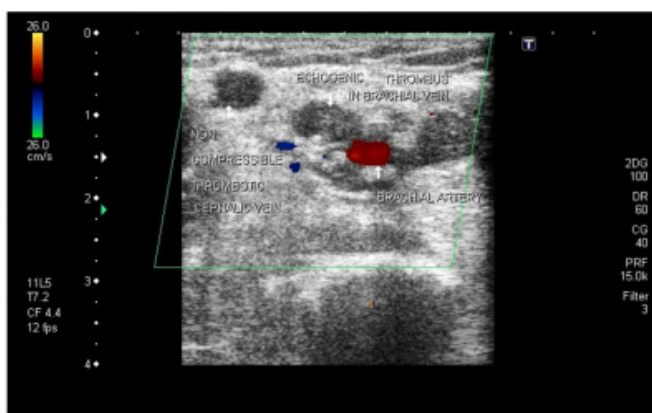
the first rib lying in the space between the first rib and clavicle. Unaccustomed exercise of the upper extremity in an elevated position causes repeated intimal damage to the vein predisposing to thrombosis. The process of thrombosis can then extend to the axillary vein and even the cephalic vein as in the case presented. Therefore prior history of unaccustomed use of the upper limb is a significant factor which can help in diagnosing PSS clinically. Symptoms and signs caused by compression of arterial and neural structures in addition to venous thrombosis may also be seen in a few cases typical of a thoracic outlet syndrome. [3]

Clinical features of PSS are typical with sudden onset of edema of the upper extremity accompanied by pain and congestion of the limb. Movements of the limb may be restricted due to edema and pain. Patient may also exhibit neurological symptoms and signs. Arterial compression is rare. In such a situation awareness of this condition should raise a strong index of suspicion for this condition. In majority of cases PSS is misdiagnosed and even treated as cellulitis by the primary care physician as was seen in the case presented. [4] This invariably leads to delay in the definitive diagnosis thereby increasing the morbidity associated with this condition.

Doppler ultrasonography is the investigation of choice for confirming the diagnosis of PSS. [5,6,7] As in the case presented doppler revealed thrombosis of the axillary vein and cephalic vein extending up to the venae comites of the brachial artery (Figure 4). The arterial circulation was normal.

#### **Figure 4**

Doppler showing the lower extent of the thrombus in the venae comites of the brachial artery.



Treatment of PSS continues to be a debatable topic. In any venous thrombosis commencement of anti-coagulation treatment continues to be the mainstay of treatment. [1] The

aim of anti-coagulation treatment is to prevent further propagation of the clot, thereby allowing collateral circulation to develop. A course of parenteral anticoagulants followed by oral anti coagulation is the standard form of treatment. [1, 8, 9]

Catheter directed thrombolysis of the clot has also been described as an efficacious modality of treatment in an acute setting. [10] However this requires an interventional radiology or an interventional cardiology facility to facilitate this treatment. Acute thrombolytic therapy has its own set of complications including rare complications such as renal failure which have been described in literature. Anecdotal case reports have described this as a successful modality of treatment. Since the number of cases are significantly less and in the absence of randomized prospective trials it is difficult to establish the superiority of any particular modality of treatment in order to authentically advocate it.

In a patient of PSS along with neurological symptoms, surgical intervention by way of transaxillary resection of first rib have been described.[11,12] It has been observed that in a patient treated conservatively, only temporary relief is obtained. Due to the persistent compressing effect on venous structures, recurrent episodes of thrombosis of veins may occur. This can only be treated permanently by resection of first rib.

The best therapeutic option for this condition is therefore a matter of debate with each institution having its own treatment protocol based on the availability of interventional facilities.[13,14] Early diagnosis followed by anti coagulation treatment in a case devoid of neurological symptom still continues to be a good option. However if neurological symptoms accompany vascular symptoms, then a more radical approach may have to be adapted to achieve a permanent cure to this condition. [15]

#### **CONCLUSION**

Paget Schroetter syndrome is a rare condition affecting the veins of upper extremities. Awareness of this condition is important for primary care physicians. A high index of clinical suspicion confirmed by Doppler ultrasonography is pivotal in diagnosis of this condition. Optimum choice of conservative treatment followed if necessary by surgical intervention can only provide a long lasting cure.

#### **ACKNOWLEDGEMENTS**

We would like to thank Dr.Shirish Patil, Dean of Dr.D.Y.Patil Medical College, Navi Mumbai, India for

allowing us to publish this case report.

We would like to thank Mr. Parth K. Vagholkar for his help in typesetting the manuscripts.

### References

1. Czihal M, Hoffmann U. Upper extremity deep vein thrombosis. *Vasc Med* 2011 Jun; 16(3): 191-202.
2. Urschel HC Jr. Anatomy of the thoracic outlet. *Thorac Surg Clin* 2007 Nov; 17(4):511-20.
3. Mitu F, Leon MM, Mitu M. Upper extremity deep vein thrombosis: current concepts in diagnosis and treatment. *Rev Med Chir Soc Med Nat* 2011 Apr-Jun; 115(2):316-24.
4. Gunderson CG, Chang JJ. Risk of deep vein thrombosis in patients with cellulites and erysipelas: A systematic review and meta-analysis. *Throm Res* 2013 Sep; 132(3): 336-40.
5. Illing KA, Doyle AJ. A comprehensive review of Paget Schroetter syndrome. *J Vasc Surg* 2010 Jun; 51(6): 1538-47.
6. Chin EE, Zimmerman PT, Grant EG. Sonographic evaluation of upper extremity deep venous thrombosis. *J Ultrasound Med* 2005 Jun; 24(6): 829-38.
7. Mustafa BO, Rathman SW, Whitsett TL, Raskob GE. Sensitivity and specificity of ultrasonography in the diagnosis of upper extremity deep vein thrombosis: a systematic review. *Arch Intern Med* 2002 Feb 25; 162(4): 401-4.
8. Alla VM, Natrajan N, Kaushik M, Warriar R, Nair CK. Paget-Schroetter syndrome: review of pathogenesis and treatment of effort thrombosis. *West J Emerg Med* 2010 Sep; 11(4): 358-62.
9. Urschel HC, Razzuk MA. Paget-Schroetter syndrome: what is the best management? *Ann Thorac Surg* 2000 Jun; 69(6): 63-8.
10. Monila JE, Hunter DW, Dietz CA. Paget-Schroetter syndrome treated with thrombolytics and immediate surgery. *J Vasc Surg* 2007 Feb; 45(2): 328-34.
11. Klitford L, Broholm R, Baekgaard N. Deep venous thrombosis of the upper extremity. A review. *Int Angiol* 2013 Oct; 32(5): 447-52.
12. Taylor JM, Telford RJ, Kinsella DC, Watkinson AF, Thompson JF. Long term clinical and functional outcome following treatment for Paget-Schroetter syndrome. *Br J Surg* 2013 Oct; 100(11): 1459-64.
13. Lee JT, Karwowski JK, Harris EJ, Haukoos JS, Olcott C. Long term thrombotic recurrence after non operative management of Paget Schroetter syndrome. *J Vasc Surg* 2006 Jun; 43(6): 1236-43.
14. Landry GJ, Liem TK. Endovascular management of Paget Schroetter syndrome. *Vascular* 2007 Sep-Oct; 15(5): 290-6.
15. Machleder HI. Effort thrombosis of the axillosubclavian vein: a disabling vascular disorder. *Compr Ther* 1991 May; 17(5): 18-24.

**Author Information**

**Ketan Vagholkar, MS, DNB, MRCS, FACS, Professor**

Department of Surgery, Dr.D.Y.Patil Medical College

**Inder Maurya, MBBS Resident**

Department of Emergency Medicine, Dr.D.Y.Patil Medical College

**Shashiprakash Pandey, MBBS Resident**

Department of Surgery, Dr.D.Y.Patil Medical College