

# Mycosis Fungoides With Unusual Granulomatous Pulmonary Manifestations

S S Ballal, J M Jaworski, J S Hou

## Citation

S S Ballal, J M Jaworski, J S Hou. *Mycosis Fungoides With Unusual Granulomatous Pulmonary Manifestations*. The Internet Journal of Hematology. 2013 Volume 9 Number 1.

## Abstract

Mycosis fungoides is the most common form of cutaneous T-cell lymphoma, with the lungs being the most common site of extranodal involvement. Our patient is a 65 year old woman who was diagnosed with mycosis fungoides and presented with lung parenchymal infiltrates shortly thereafter. Histological examination of the lung lesion revealed an atypical small lymphocytic infiltration along with prominent granulomas and focal angiocentric lesions. Flow cytometry studies confirmed pulmonary involvement by mycosis fungoides. Granulomatous inflammation has been described earlier within the cutaneous infiltrates of mycosis fungoides. However, the presence of granulomas in the lungs involved by mycosis fungoides has only been described in one previous case report. We are reporting the second case of pulmonary involvement by mycosis fungoides with very unusual histologic features including the formation of epithelioid granulomas and angiocentric lesions, supported by flow cytometry studies.

## INTRODUCTION

Mycosis fungoides (MF) is the most common form of cutaneous T-cell lymphoma, characterized by the proliferation of small cerebriform lymphocytes that express a mature peripheral T-helper cell phenotype(1). MF most frequently affects adults in the fifth to sixth decades and is more common in men and in blacks. The incidence has been estimated to be 0.36/100,000 person years in the United States (2). The majority of patients show an indolent clinical course over years or decades. However, in advanced stages, MF can spread to extracutaneous visceral organs such as lymph nodes, lungs, spleen, and liver, portending a poor prognosis (3). The lungs are the most frequent site of extranodal involvement, although the diagnosis is usually made at autopsy (4, 5, 6, 7, 8). Granulomatous inflammation has been described within the cutaneous infiltrates of mycosis fungoides in earlier case reports and series (9, 10, 11, 12, 13). However the presence of granulomas in the lungs involved by MF has only been described in one previous case report (14). In addition, the granulomatous inflammation can obscure the pathological lymphoid infiltrate rendering the diagnosis of MF difficult (15, 16, 17). We are reporting the second case of pulmonary involvement by disseminated MF with unusual histologic features including the formation of epithelioid granulomas and angiocentric lesions in a 65 year-old woman.

## CASE REPORT

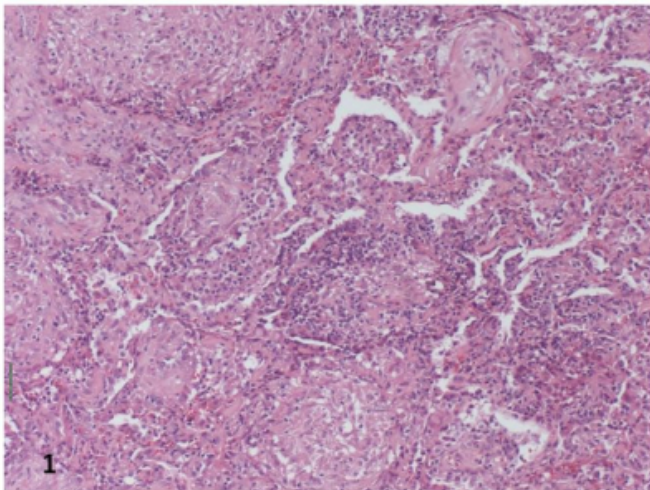
The patient is a 65 year-old Caucasian woman referred to our hospital in 2002 with a diagnosis of mycosis fungoides (MF) with lymph node involvement. The patient initially developed some skin lesions on her flank and on the hip in 1998 which showed histopathological features suggestive of morphea. She was diagnosed with scleroderma and then with mixed connective tissue disease at an outside hospital. The patient was subsequently placed on oral steroids, methoxsalen ultraviolet A photochemotherapy (PUVA), plaquenil, topical steroids, and vitamin D from October 1998 to October 1999. She finally responded to D-pencillamine and received this treatment from October 1999 to February 2001. Soon after, an erythema multiforme-like eruption developed on the torso and lower extremities and an acral lichenoid eruption. A skin biopsy specimen from the antecubital fossa was diagnosed as MF in July 2002. She then developed thrombocytopenia and underwent a bone marrow biopsy which was negative for lymphoma. She received five cycles of combination chemotherapy (CHOP). Subsequently, she was treated with PUVA in October 2002, approximately three times a week in addition to Targretin 150 mg per day with an excellent clinical cutaneous response. Her blood studies remained negative during this period. Her past history is also significant for idiopathic thrombocytopenic purpura treated with splenectomy. Her

platelet counts rose and remained in the normal range after the splenectomy.

A CT scan performed in October 2002 detected patchy parenchymal densities in the left and right upper lobes. A repeat CT scan in December 2002 showed more prominent parenchymal densities along with prominent axillary, mediastinal, and hilar adenopathy. A PET scan showed an increased uptake in the left paratracheal, base of the left lung, bilateral axillary regions and right hilar regions. A lymph node biopsy done earlier was positive for MF, representing progression of the patient's cutaneous disease. The diagnosis of MF in the skin and lymph node biopsies were reviewed and confirmed at an outside referral hospital. Based on the CT and subsequent PET scan findings, the patient underwent a left lung wedge resection in March 2003. Microscopic examination of the lung parenchyma revealed an interstitial and perivascular atypical small lymphocytic infiltration (Figures 1 and 2). The majority of the lymphocytes were small with irregular nuclear membranes and hyperchromatic nuclei. A focal angiocentric infiltrating pattern was present (Figure 3). In addition, a prominent histologic feature was the presence of multiple confluent non-necrotizing granulomas with areas of fibrosis and consolidation (Figure 4).

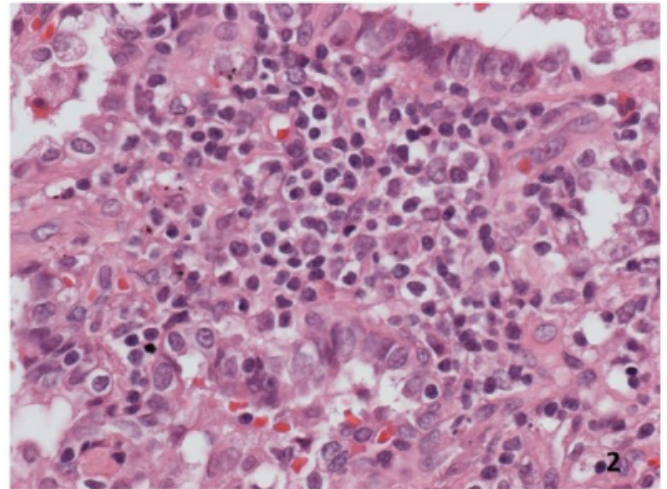
**Figure 1**

Low power view showing the granulomas and the interstitial infiltrate composed of small atypical lymphocytes (x 100, H&E)



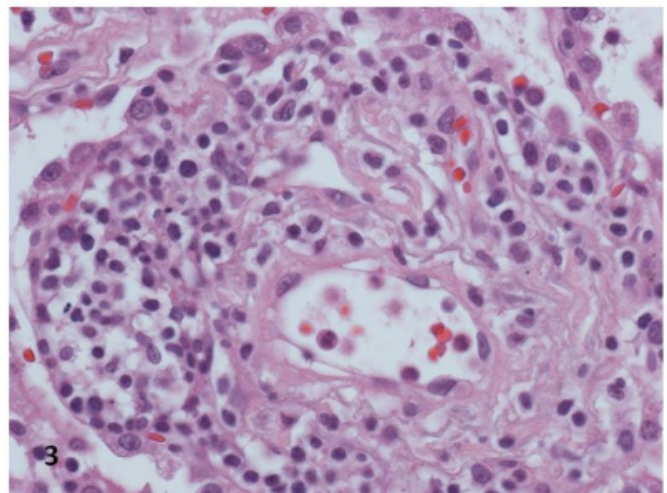
**Figure 2**

High power view showing the interstitial infiltrate of small atypical lymphocytes (x 400, H&E)



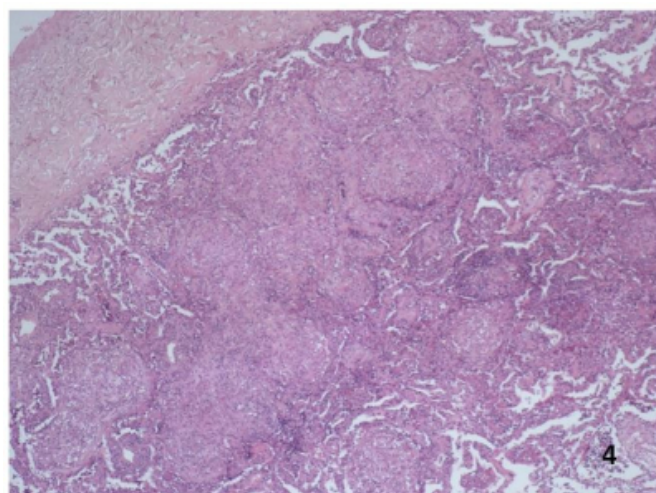
**Figure 3**

High power view showing the pulmonary vessel infiltrated by atypical small lymphocytes (x 400, H&E)



**Figure 4**

Low power view showing multiple confluent non necrotizing granulomas (x 400, H&E)



Immunohistochemical study revealed that the vast majority of lymphocytes were positive for CD3 and CD4, while CD8 and CD20 were negative. Special stains for acid fast bacilli and fungal organisms were negative. Flow cytometric study of the lung tissue revealed almost all lymphocytes positive for CD3 and CD4, while CD8 was negative. The CD4: CD8 ratio was 9.1:1. Approximately 25% of the T cells showed absent CD7 expression. The DNA-PCR based molecular analysis showed negative TCR-gamma rearrangement. These findings were consistent with pulmonary involvement by MF.

Flow cytometric analysis of the peripheral blood performed in April 2003 revealed 49% CD4 positive, CD8 negative Sezary cells, consistent with blood involvement by MF. A bone marrow biopsy done in October 2003 revealed a hypercellular marrow with multiple atypical lymphoid infiltrates consistent with marrow involvement by MF. Cytogenetic study of the bone marrow revealed a normal female karyotype. She subsequently underwent an autologous bone marrow transplant in October 2003.

Flow cytometry study of the peripheral blood in May 2004 revealed 12% of T lymphocytes with CD45, CD4, CD5 and CD7 expression consistent with involvement by MF. In addition, negative CD3 expression was noted, suggestive of tumor progression. The patient's hospital course was prolonged and complicated by pneumonia and other infections. She was eventually discharged to a rehabilitation facility in June 2004 and expired in October 2004.

## DISCUSSION

The extracutaneous spread of MF has been reported by a number of studies (4,5,6). The largest series by Rappaport studied 45 autopsy cases of mycosis fungoides and 32 (71%) of these cases showed extracutaneous involvement. Pulmonary involvement was seen in 21 of these 32 patients (66%), representing the most common visceral site of involvement in this study (6). Lymph node involvement was seen in 24 of the 32 patients (75%) in the study (6). Our case also had lymph node involvement.

The radiographic manifestations of disseminated pulmonary MF include bilateral ill-defined nodules of variable size, patchy areas of consolidation, bilateral reticulonodular infiltrates, hilar, and mediastinal lymphadenopathy, and pleural effusion (4,5,8). In keeping with these findings, our case on CT scan had patchy parenchymal densities and hilar, mediastinal and axillary lymphadenopathy.

The histological appearance of MF involving the lung has been described as an interstitial and/or intra-alveolar infiltrate of neoplastic lymphoid cells similar to those seen in the skin (6). Pulmonary involvement by MF in the form of angiocentric infiltration of tumor cells have been described in earlier published case reports (14, 18). Gomez De La Fuente et al described a case of granulomatous MF progressing to pulmonary and thyroid involvement (19). In this case, fine needle aspiration biopsy of the thyroid showed granulomas with necrosis and atypical lymphocytes (19). However the transbronchial biopsy of the lung revealed alveolar infiltration by atypical T lymphocytes without granulomas (19). The presence of both epithelioid granulomas and angiocentric lesions in the lungs as seen in our case have only been described previously in one published case by Kitching (14). Our case additionally had peripheral blood involvement which was not seen in the case described by Kitching (14). Our case, like the one described by Kitching (14), had lymph node involvement. Rappaport's study showed that lymph node involvement was always associated with visceral involvement (20). In addition, the present case also had flow cytometry results to support the diagnosis.

Granulomatous variant of cutaneous MF is an unusual subtype of MF, characterized by the histological presence of a granulomatous reaction (21). The first description was given by Ackerman and Flaxman (9). The prognostic and clinical significance of a granulomatous reaction in MF remains uncertain (21). The prolonged course of some cases



lead to the assumption of a more favorable prognosis for this variant (9,10). However, later studies demonstrated evidence that granulomatous MF may have an aggressive course with rapid extracutaneous spread and death (12, 19, 22). A review of the literature by Chen et al revealed that 11 of the 24 reported patients with granulomatous MF died of the disease, and like their case, seven died within 5 years of the onset of the skin lesions (23). In the study by Dabski of four cases of MF with granulomatous reactions, one had pulmonary dissemination. However, there is no mention about the presence of granulomas in the lung lesions (12). Analogously, in our case, there was no mention of the presence of granulomas in the skin biopsy.

Granulomatous slack skin (GSS) should be considered in the differential diagnosis of granulomatous MF. This is a rare lymphoproliferative cutaneous disorder which shares many histologic similarities with granulomatous MF, but GSS presents as progressive development of pendulous skin folds (17, 19), a clinical feature absent in our case.

The pathogenetic mechanisms of granuloma formation in lymphoid neoplasms are poorly understood (24). Granulomatous reactions has been regarded by some authors as a local tissue response to the infiltrating malignant cells or their antigens (25). However this has been criticized by others since granulomas also occur in histologically proven lymphoma free tissues (26). The exact cause of granuloma formation in MF is not clear but may be related to the treatment with interferon-alpha in some instances (21).

Most granulomas in the lung are caused by mycobacterial or fungal infection (27). However, the special stains in our case were negative for mycobacteria and fungal organisms. In the United States, sarcoidosis is the most common noninfectious cause of lung granulomas (28). In the current case, the patient had no clinical history or signs of sarcoidosis.

The lungs may also be involved by other lymphoproliferative lesions, such as lymphomatoid granulomatosis and pulmonary lymphomas. Lymphomatoid granulomatosis is a rare lymphoproliferative disease predominantly involving the lung with a high mortality rate (29). This was first described by Liebow et al (30). The histologic features include a mixed mononuclear cell infiltrate containing CD20-positive large B lymphocytes and numerous CD3-positive small lymphocytes, vascular infiltration, necrosis, and evidence of EBV infection (29). Vascular infiltration can be seen in both inflammatory

conditions like sarcoidosis and infections as well as neoplastic conditions like lymphomas reflecting the infiltrative nature of the process (29). Our case had focal angiocentric infiltration by tumor cells; however, the history, morphology, immunohistochemistry, and flow cytometry results support the diagnosis of pulmonary involvement by MF.

Hodgkin lymphoma (HL) can show a prominent histiocytic component and may involve the lung (14). A sarcoid-like granulomatous reaction to HL is frequently found in lymph nodes, spleen, liver, and bone marrow, regardless of actual neoplastic involvement at these sites (31, 32). Daly et al have reported a patient with sarcoid-like, granulomatous lung disease which presented shortly before extrapulmonary HL was diagnosed (33). In a study of 30 cases of pulmonary lymphomas which showed features of angiocentricity, vascular invasion, and polymorphous infiltrate there is no mention of the presence of distinct granulomas. The cases studied included HL and non-HL (NHL), primary and secondary (34). However, in another study of 69 primary pulmonary NHL which included both low and high grade lymphomas, granulomas were noted in 20% of the low grade cases (35). These granulomas were adjacent to the vascular and lymphatic channels (35).

To conclude, the histological appearance of granulomas and focal angiocentric involvement by the tumor cells in our case represents an unusual presentation of MF involving the lungs. To the best of our knowledge, this is only the second case to report the presence of granulomas and angiocentric lesions in a case of pulmonary involvement by MF. These unusual histologic features can present potential pitfalls in rendering an accurate diagnosis. In addition, our case also demonstrated flow cytometric results to support the diagnosis of mycosis fungoides in the lungs.

### **References**

1. Morales Suarez-Varela MM, Llopis Gonzalez A, Marquina Vila A, et al. Mycosis fungoides: review of epidemiological observations. *Dermatology*; 2000; 201: 21–28.
2. Weinstock MA, Gardstein B. Twenty-year trends in the reported incidence of mycosis fungoides and associated mortality. *Am J Public Health*; 1999; 89: 1240–1244.
3. Tamai K, Koyama T, Kondo T, Takaori A, Mizumoto C, Manabe T, Togashi K. High-resolution Computed Tomography Findings of Diffuse Pulmonary Involvement by Mycosis Fungoides. *J Thorac Imaging*; 2007; 22: 366–368.
4. Rubin DL, Blank N. Rapid pulmonary dissemination in mycosis fungoides simulating pneumonia. A case report and review of the literature. *Cancer*; 1985; 56: 649–651.
5. Wolfe JD, Trevor ED, Kjeldsberg CR. Pulmonary manifestations of mycosis fungoides. *Cancer*; 1980; 46:

2648–2653.

6. Rappaport H, Thomas LB. Mycosis fungoides: the pathology of extracutaneous involvement. *Cancer*; 1974; 34: 1198–1229
7. Merlo JC, Hoppe RT, Abel E, Cox RS. Extracutaneous mycosis fungoides. *Cancer*; 1987; 60:397–402.
8. Marglin SI, Soulen RL, Blank N, et al. Mycosis fungoides. Radiographic manifestations of extracutaneous intrathoracic involvement. *Radiology*; 1979; 130: 35–37.
9. Ackerman AB, Flaxman BA. Granulomatous mycosis fungoides. *Br. J. Derm*; 1970; 82: 397–401.
10. Flaxman BA, Koumans JAD, Ackerman AB. Granulomatous mycosis fungoides. A 14 year follow up of a case. *The American Journal of Dermatopathology*; 1983; 5(2): 145–151.
11. Buechner SA, Winkelman RK, Sezary syndrome: a clinicopathologic study of 39 cases. *Arch Dermatol*; 1983; 119: 979–986.
12. Dabski K, Stoll HL. Granulomatous reactions in mycosis fungoides. *J Surg Oncol*; 1987; 34: 217–229.
13. Schwartz RA, Burgess GH, Holterman O et al. Mycosis fungoides associated with florid sarcoid reactions. *J Surg Oncol*; 1980; 14: 347–357.
14. Kitching PA, Gibbs AR. Pulmonary involvement by mycosis fungoides. A case showing angiocentric lesions and granulomas. *Path Res Prac*; 1993; 189: 594–596
15. Randle HW, Banks PM, Winkelmann RK. Cutaneous granulomas in malignant lymphoma. *Arch Dermatol*; 1980; 116: 441–443.
16. Argyeri ZB, Goeken JA, Piette WW, Madison KC. Granulomatous mycosis fungoides. Clinicopathologic study of two cases. *Am J Dermatopathol*; 1992; 14: 200–210
17. LeBoit PE, Zackheim HS, White CR. Granulomatous variants of cutaneous T cell lymphoma. *Am J Surg Pathol*; 1988; 12: 83–95
18. Ueda T, Hosoki N, Isobe K et al. Diffuse involvement by mycosis fungoides: High resolution computed tomography and pathologic findings. *Journal of Thoracic imaging*; 2002; 17: 157–159.
19. Gomez-De La Fuente E, Ortiz PL, Vanaclocha F et al. Aggressive granulomatous mycosis fungoides with clinical pulmonary and thyroid involvement. *Br J Dermatol*; 2000; 142: 1026–1029.
20. Rappaport H. The pathology of the extracutaneous manifestations of mycosis fungoides. *Bulletin Du Cancer*; 1977; 64: 275–278.
21. Kazakov DV, Burg G, Kempf W. Clinicopathologic spectrum of mycosis fungoides. *European Academy of Dermatology and Venereology JEADV*; 2004; 18: 397–415.
22. Fischer M, Wohlrab J, Audring TH et al. Granulomatous mycosis fungoides. Report of two cases and review of the literature. *J Eur Acad Dermatol Venereol*; 2000; 14: 196–202.
23. Chen KR, Tanaka M, Miyakawa S. Granulomatous mycosis fungoides with small intestinal involvement and a fatal outcome. *Br J Dermatol*; 1998; 138: 522–525.
24. Kempf W, Ostheeren-Michaelis S, Paulli M, Lucioi M et al. Granulomatous mycosis fungoides and Granulomatous Slack Skin. *Arch Dermatol*; 2008; 144(12):1609–1617
25. Kahn LB, Gordon W, Camp R. Florid sarcoid reaction associated with lymphoma of the skin. *Cancer*; 1974; 33(4): 1117–1122
26. Anderson R, Geraint James D, Peters PM, Thomson AD. Local sarcoid - tissue reactions. *Lancet*; 1962; 1(7241):1211–1213.
27. Mukhopadhyay S, Gal AA. Granulomatous lung disease. An approach to the differential diagnosis. *Arch Pathol Lab Med*; 2010; 134: 667–690.
28. Woodard BH, Rosenberg SI, Farnham R, Adams DO. Incidence and nature of primary granulomatous inflammation in surgically removed material. *Am J Surg Pathol*; 1982; 6(2): 119–129.
29. Katzenstein A-LA, Doxtader E, Narendra S. Lymphomatoid granulomatosis. Insights gained over 4 decades. *Am J Surg Pathol*; 2010; 34(12): e35–e48.
30. Liebow AA, Carrington CRB, Friedman PJ. Lymphomatoid granulomatosis. *Hum Pathol*; 1972; 3: 457–558.
31. Kadin ME, Donaldson SS, Dorfman RF. Isolated granulomas in Hodgkin's disease. *N Engl J Med*; 1970; 283: 859–61.
32. Brincker H. Sarcoid reactions and sarcoidosis in Hodgkin's disease and other malignant lymphomata. *Br J Cancer*; 1972; 26: 120–128.
33. Daly PA, O'Brian DS, Robinson I, Guckian M, Prichard JS. Hodgkin's disease with a granulomatous pulmonary presentation mimicking sarcoidosis. *Thorax*; 1988; 43: 407–409.
34. Colby TV, Carrington CB. Pulmonary lymphomas simulating lymphomatoid granulomatosis. *Am J Surg Pathol*; 1982; 6(1): 19–32.
35. Fiche M, Capron F, Berger F, Galateau F, Cordier J-F, Loire R and Diebold J. Primary pulmonary non-Hodgkin's lymphomas. *Histopathology*; 1995; 26: 529–537.

**Author Information**

**Shefali S. Ballal, M.D.**

Department of Pathology and Laboratory Medicine, Drexel University College of Medicine  
Philadelphia, PA

**Joseph M. Jaworski, M.D.**

Department of Pathology and Laboratory Medicine, Mercy Fitzgerald Hospital  
Darby, Pennsylvania

**J. Steve Hou, M.D.**

Department of Pathology and Laboratory Medicine, Drexel University College of Medicine  
Philadelphia, PA