

Pulmonary Aspiration In A Patient With “Thoracic Stomach”

Q Hao, T M Schieble

Citation

Q Hao, T M Schieble. *Pulmonary Aspiration In A Patient With “Thoracic Stomach”*. The Internet Journal of Anesthesiology. 2013 Volume 32 Number 1.

Abstract

Pulmonary aspiration of gastric contents in the perioperative period is a rare, but potentially catastrophic complication. Anesthesiologists routinely identify risk factors for aspiration, and take measures to reduce the incidence and severity of this complication. Pharmacological prophylaxis, NPO (nil per os, or nothing by mouth) guidelines and cricoid pressure (Selleck's Maneuver) during induction have been utilized, although their application and efficacy are controversial. We report a case of pulmonary aspiration during the peri-operative period in a patient with severe hiatal hernia.

INTRODUCTION

Pulmonary aspiration of gastric contents in the perioperative period is a rare, but potentially catastrophic complication. Anesthesiologists routinely identify risk factors for aspiration, and take measures to reduce the incidence and severity of this complication. Pharmacological prophylaxis, NPO (nil per os, or nothing by mouth) guidelines and cricoid pressure (Selleck's Maneuver) during induction have been utilized, although their application and efficacy are controversial. We report a case of pulmonary aspiration during the peri-operative period in a patient with severe hiatal hernia.

CASE REPORT

The patient is a 54 year-old woman (weight 110 kg, height 162 cm), with a past medical history significant for gastro-esophageal reflux disease (GERD), obesity, obstructive sleep apnea on night time CPAP and type II diabetes mellitus. Her past surgical history included Nissen fundoplication in 1998, cholecystectomy in 1999 and appendectomy in 1964. She takes omeprazole and metoclopramide daily for her GERD symptoms.

The patient was scheduled for an open reduction and internal fixation of a right ankle fracture which resulted from a fall during a syncopal episode. She was admitted to hospital on the day before surgery and underwent syncope work-up, which included a thoracic computed tomography (CT) examination (Fig 1).

The patient was NPO for 24 hours prior to surgery. Her airway examination was normal. She was intubated easily during previous anesthetics. No preoperative medication was given in the holding room. During rapid sequence induction with cricoid pressure, a large amount of coffee-ground emesis was noticed in her mouth. The patient's head was turned to the side and oral suction was performed immediately, followed by intubation without difficulty. Endotracheal tube suctioning was performed, yielding less than 10 cc of coffee-ground material prior to the institution of positive pressure ventilation. A nasogastric tube was inserted and maintained on continuous suction. About 300 ml of coffee-ground stomach contents were drained from the stomach. The patient received 1 gram of cefazolin for routine antibiotic prophylaxis. Metoclopramide 10 mg, ranitidine 50 mg and dexamethasone 10 mg were administered after intubation.

The patient remained intubated postoperatively in the Intensive Care Unit. She was extubated fifteen hours postoperatively without difficulty and continued to do well until seven hours later when she vomited and aspirated again. She was then reintubated due to hypoxia and required ventilator support. An esophagogastroduodenoscopy (EGD) was performed which identified a severe paraesophageal hiatal hernia and esophagitis, but no active bleeding. The patient was extubated successfully on postoperative day 4 and discharged one week later to a rehabilitation facility.

Figure 1

Thoracic CT shows a herniated stomach into the chest compressing the right lung.

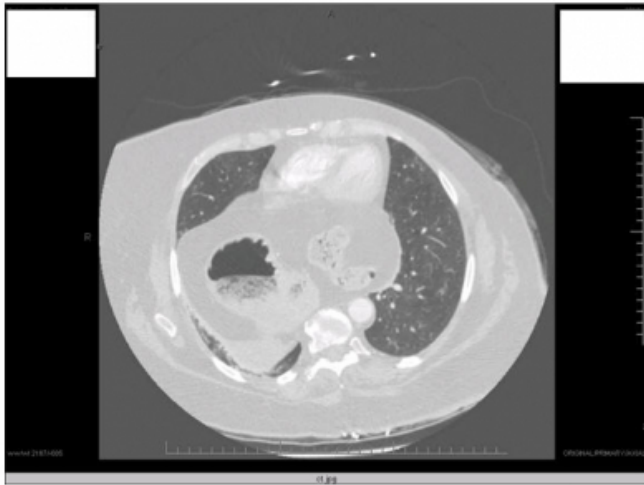
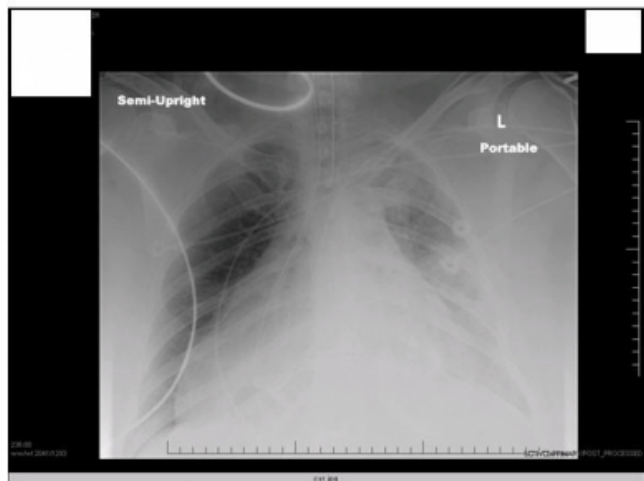


Figure 2

Postoperative chest X-ray shows suspected infiltrate in the left lung and gastric tube located in the right chest area.



DISCUSSION

The incidence of pulmonary aspiration in the perioperative period is relatively low. Warner et al from the Mayo Clinic reviewed 215,488 general anesthetics (1). Pulmonary aspiration was diagnosed in 67 patients by visualizing particulate matter in the tracheobronchial tree or by radiographic confirmation. Of the 66 patients who survived the surgery, 42 (63%) did not develop symptoms and were discharged the same day. Of the 24 (36%) who did develop symptoms, 13 required mechanical ventilatory support for more than six hours. Three of these patients died. Complications developed in equal percentages among those who received and did not receive pharmacological acid

neutralization prophylaxis. The same study from the Mayo Clinic suggested that the incidence of aspiration was similar in adults (3.1 per 10,000) and children (3.8 per 10,000), although another study (2) suggested that the incidence of aspiration in children was higher (10.2 per 10,000).

Gastric contents with pH less than 2.5 and volume more than 25 ml are considered to increase the risk for aspiration pneumonitis (3). This patient in our report presented with about 300 ml of coffee-ground contents in her stomach prior to surgery even after fasting for 24 hours. This case illustrates that “fasting” in trauma or an acute disease process does not reliably assure stomach emptying.

Thoracic displacement of the stomach rendered this patient susceptible to pulmonary aspiration (4), favoring aspiration of gastric contents despite rapid sequence induction and the application of cricoid pressure. We did not appreciate the patient’s significant hiatal hernia (“thoracic stomach”) until the thoracic CT became available after surgery. Gastric decompression prior to induction may have changed the outcome in this case. Awake fiberoptic intubation with preservation of pharyngeal reflexes might have offered additional protection from aspiration.

In addition to her hiatal hernia (“thoracic stomach”), this patient had other risk factors for pulmonary aspiration, including morbid obesity and recent trauma (4). Although she was receiving anti-reflux medications including metoclopramide and omeprazole, these medications appeared to have limited efficacy in her case. Recommendations from the American Society of Anesthesiology (ASA) on drug prophylaxis for aspiration are presented in table 1. Pharmacologic gastric acid prophylaxis in healthy patients with minimal aspiration risk are not recommended routinely. Selected medications should be given to patients with high risk for pulmonary aspiration.

Table 1

Summary of Pharmacologic Recommendations to Reduce the Risk of Pulmonary Aspiration

<u>Medication Type and Common Examples</u>	<u>Recommendation</u>
<i>Gastrointestinal stimulants</i>	No routine use
metoclopramide	
<i>Gastric acid secretion blockers</i>	No routine use
cimetidine	
famotidine	
ranitidine	
omeprazole	
lansoprazole	
<i>Antacids</i>	No routine use
sodium citrate	
sodium bicarbonate	
magnesium trisilicate	
<i>Antiemetics</i>	No routine use
droperidol	
ondansetron	
<i>Anticholinergics</i>	No use
atropine	
scopolamine	
glycopyrrolate	
<i>Combinations of the medications above</i>	No routine use

Reduction in tone of the lower esophageal sphincter (LOS) is an important physiological mechanism for reflux of gastric contents. An important factor that inhibits regurgitation is the barrier pressure, i.e. the difference between gastric pressure and LOS pressure. During anesthesia, it has been shown that LOS pressure and also barrier pressure are decreased by induction agents, inhalation agents, opioids, and anticholinergic drugs (5).

Although there is no convincing evidence to suggest that

cricoid pressure has reduced the incidence of aspiration or mortality, cricoid pressure for rapid sequence induction may be beneficial as long as it is performed properly and does not impede effective airway management (6).

Treatment for the management of aspiration depends on the severity of the aspiration, type of aspirant, and rapidity of symptom development. Patients with evidence of particulate aspiration may benefit from bronchopulmonary lavage. Those with nonparticulate acid aspiration do not benefit from lavage or instillation of acid neutralizing solutions. Symptomatic chemical pneumonitis may require mechanical ventilation support. Steroids yield little real improvement in long-term outcome, and antibiotics may be appropriate when there is evidence of infection (7).

References

1. Warner MA, Warner ME, Weber JG: Clinical significance of pulmonary aspiration during the perioperative period. *Anesthesiology* 1993; 78:56-62
2. Warner MA, Warner ME, Warner DO, Warner LO, Warner EJ: Perioperative pulmonary aspiration in infants and children. *Anesthesiology* 1999;90:66-71
3. Strunin L. Editorial I: How long should patients fast before surgery? Time for new guidelines. *Br. J. Anesth.* 1993; 70 (1): 1-4
4. Asai T. Editorial II: Who is at increased risk of pulmonary aspiration? *Br. J. Anesth.* 2004; 93 (4): 497-500
5. Ng A, Smith G: Gastroesophageal reflux and aspiration in anesthetic practice. *Anesth Analg* 2001;93:494-513
6. Nagelhout J: Aspiration prophylaxis: Is it time for changes in our practice? *AANA Journal* 2003 August; 71(4):299-303
7. Mecca RS: Postoperative recovery. In: Barash PG, Cullen B, Stoelting RK: *Clinical anesthesia*. Fourth Edition. Lippincott Williams & Wilkins. Page 1391-1392

Author Information

Qingzhong Hao, MD

Thomas M Schieble, MD