

Nasal Hemangiopericytoma –A Pathological Illusion

B Kumar, B Pant, D Isser

Citation

B Kumar, B Pant, D Isser. *Nasal Hemangiopericytoma –A Pathological Illusion*. The Internet Journal of Pathology. 2013 Volume 13 Number 3.

Abstract

Objective: We report a case of rare nasal mass whose histopathological diagnosis was lobular capillary hemangioma but immunohistochemistry reported it to be hemangiopericytoma.

Case report: Lobular capillary hemangioma and hemangiopericytoma are very rare vascular tumours arising from the nasal cavity. Here we report a case of rare nasal mass, which presented with nasal obstruction and epistaxis. Frozen section biopsy reported benign vascular tumour. Final biopsy report of excised mass was sent to different pathologists at different places. Both of them confirmed to the diagnosis of lobular capillary hemangioma. Due to atypical clinical picture which was not correlating with the histopathological diagnosis, tissue was sent for immunohistochemistry, which altered the final diagnosis to hemangiopericytoma.

Conclusions: Every nasal mass should be looked with suspicion especially in older age group and patient should be kept under close observation. The facility of immunohistochemistry should be utilized in cases where there is lack of clinicopathological correlation.

INTRODUCTION

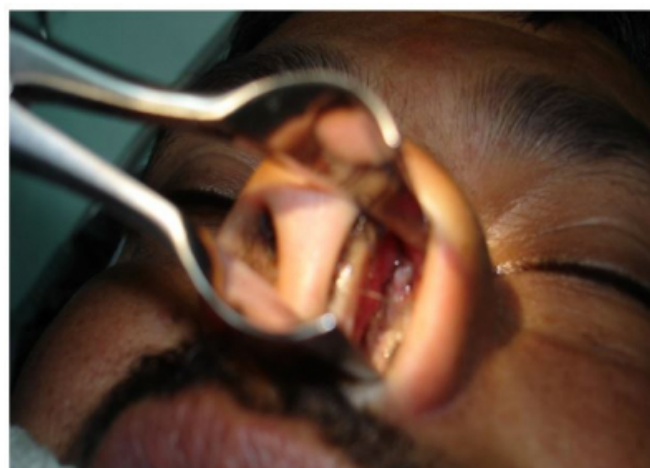
Among common benign nasal masses lobular capillary hemangioma and hemangiopericytoma are very rare vascular tumours arising from the nasal cavity. The clinical picture, course and treatment of both these tumours is entirely different. Histopathological picture of both these tumours is sometimes very confusing which creates dilemma for the treating surgeon to suggest the patient about prognosis of the disease and final outcome of the treatment. Here comes the role of immunohistochemistry, which can differentiate between different tumours by using different stains.

CASE REPORT

A 43 year old male patient presented to our OPD with chief complaints of epistaxis, nasal obstruction and headache from last two months. Epistaxis was episodic, relieved spontaneously and never required hospitalization. There was no history of hypertension, trauma or any other major systemic illness. On examination of nose there was no external deformity. On anterior rhinoscopy left side of nasal cavity was filled with a mass (Fig.1) which was dirty white in colour, non tender, friable, firm to soft in consistency and there was no bleeding in probing the mass.

Figure 1

Showing mass in nasal cavity on anterior rhinoscopy

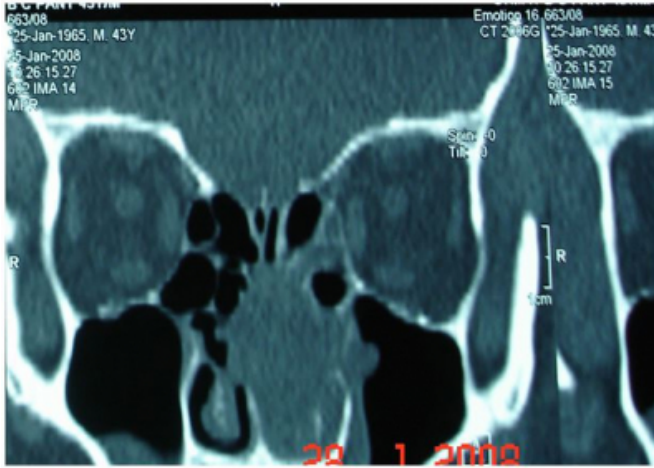


Probe test suggested that the mass was arising from the lateral wall of nasal cavity. The inferior turbinate was not visible on left side due to mass. The septum was deviated to the right side. There was no mass on right side. Nasopharynx was clear bilaterally on nasopharyngoscopy. The patient was admitted for routine investigation. CECT nose and paranasal sinuses revealed an expansile soft tissue mass lesion arising from left lateral wall of nasal cavity extending from pyriform aperture to left frontal sinus and

ethmoidal cells obliterating left osteomeatal complex (Fig.2).

Figure 2

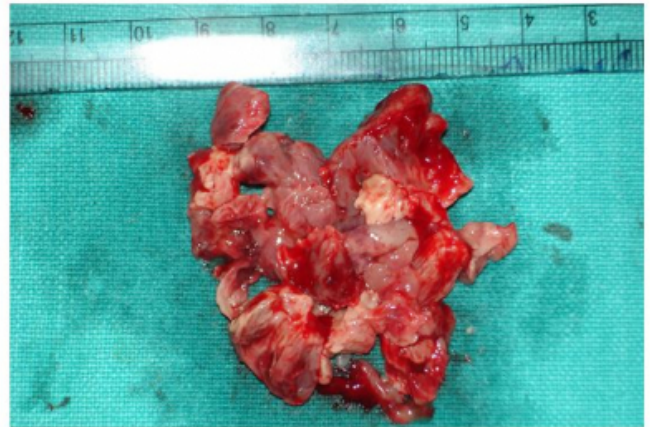
CECT Scan (coronal view) showing mass occupying nasal cavity and septum deviation to the right.



There was deviation of nasal septum to right side by the mass. Left maxillary sinus showed minimal mucosal thickening. Patient was posted for transnasal endoscopic excision of mass under general anesthesia. Mass was dirty white to grayish red at some places, firm in consistency and at some places fleshy in nature, friable and arising from lateral wall of nasal cavity just below middle meatus. Inferior turbinate was not involved. Septum was pushed to right side by the mass. Intraoperative frozen section biopsy from peripheral part of tumour suggested that mass was benign and vascular in nature and could be angiofibroma. There was no severe bleeding on removing the mass which was controlled by anterior nasal packing. The mass was excised in Toto Fig. (3) and sent for histopathological examination.

Figure 3

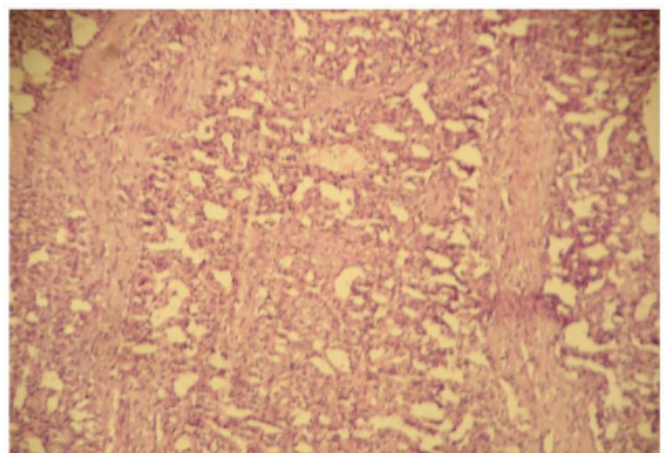
Showing excised nasal mass in toto



Left maxillary antrum was clearly visible. Right side of nasal cavity was clear except deviated nasal septum. Postoperative period was uneventful and patient was discharged on 3rd day after removal of nasal packing. Six months follow up showed no signs of recurrence. Histopathological examination of excised mass was diagnosed as lobular capillary hemangioma. But due to atypical presentation of nasal mass and lack of clinicopathological correlation with the histopathological diagnosis, tissue was sent for second opinion which also came out to be lobular capillary hemangioma. Deeper tissue cuts studied which revealed that mass could be hemangiopericytoma Fig. (4).

Figure 4

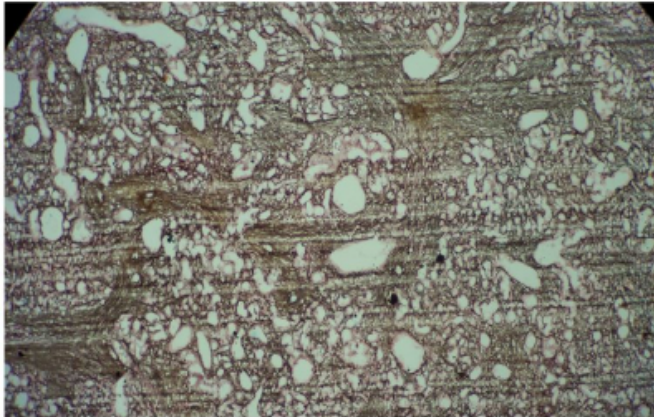
Microphotograph showing numerous vascular channels of variable sizes with occasional antlar- like arrangement and proliferated pericytes, diffuse pattern of tumor cells displaying oval to spindle nuclei showing focal myogenic differentiation. (H & E 10 X)



Reticulin stain was done which showed the pattern of reticulin fibres suggestive of hemangiopericytoma Fig. (5).

Figure 5

Showing pericellular reticulin fibres (Reticulin stain 10X)



So immunohistochemical examination with panel of markers: Vimentin, SMA, CD31, CD34 which changed the final diagnosis to hemangiopericytoma because of reactive for vimentin (Fig.6) and absence of CD 31 expression (Fig.7).

Figure 6

Non immunoreactive for CD 31(40X)

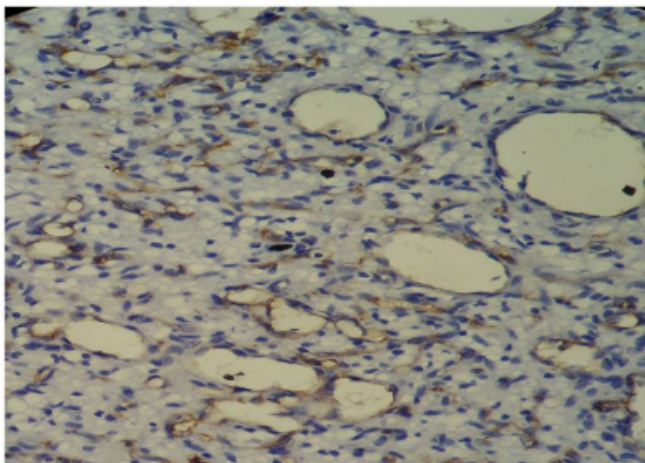
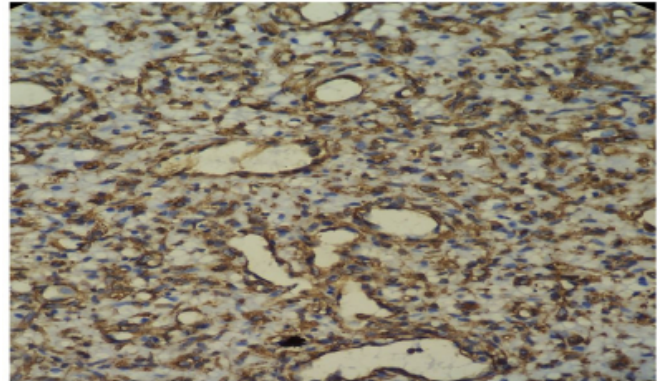


Figure 7

Immunoreactive for Vimentin(40X)



DISCUSSION

Hemangiopericytoma is a relatively rare tumor in ENT domain. It typically presents as soft to firm, tan, gray, or white, polypoidal mass which is often confused with ordinary nasal polyp. Although there is no site specification but most of them arise from lateral wall of nasal cavity¹. Nasal obstruction

and epistaxis are the most common symptoms. There is brisk hemorrhage during biopsy which was absent in this case. All hemangiopericytomas regardless of site of origin and histology behave in a malignant fashion. Lesion can be confused with angiofibroma and lobular capillary hemangioma. Angiofibroma was not thought in this case as the patient was middle aged and mass did not bleed on probing although there was history of spontaneous epistaxis in the past. Lobular capillary hemangioma predominately arises from the septum, patients are typically young mostly <18 years of age and females are more involved than males. It is commonly seen in pregnant ladies and regresses after delivery. Bleeding is the most common symptom. Sometimes there is history of antecedent trauma. Due to absence of these features in the present case, in spite of histopathological diagnosis being lobular capillary hemangioma, tissue was sent for immunohistochemistry which changed the final diagnosis. Hemangiopericytoma is an uncommon tumour, first reported by Stout and Murray. It is thought to be arising from the pericytes of Zimmermann, a cell that lies external to the reticulin sheath of capillaries and serves to change their lumen². Hemangiopericytomas have been accepted as soft tissue tumors with distinct clinicopathologic features. They are characterized as benign or malignant, round to spindle cell tumors with numerous “staghorn” branching vascular channels³. Another characteristic is the difficulty encountered in predicting their

clinical behavior as they commonly lack the electron microscopic differentiation properties of pericytes. Mc Master et al identified three grades of this tumour as benign, borderline and malignant [4]. The reticulin pattern is distinctive of hemangiopericytoma and shows the proliferating pericytes to be outside reticulin framework of contained vessel. Histopathology in this case was also confusing as histological picture of lobular capillary hemangioma shows lobular arrangement of capillaries which often surround a large central vessel along which a second population of spindle, pericytic cells exhibiting positivity for smooth muscle cell actin which is also present in hemangiopericytoma. Sinonasal hemangiopericytomas are subdivided into soft tissue-type hemangiopericytomas and true hemangiopericytomas. [5] Soft tissue-type hemangiopericytomas are frequently highly aggressive, whereas true hemangiopericytomas show localized benign behavior. Sino nasal true hemangiopericytomas should be strictly differentiated from soft tissue-type hemangiopericytomas. Treatment consists in wide surgical excision. [6] The majority of sinonasal-type hemangiopericytomas have excellent long-term prognosis (88% raw 5-year survival) following surgery alone. Lobular capillary hemangioma, has entirely different course and management while hemangiopericytoma has some chances of behaving in a malignant manner. This type of controversy can only be solved by advanced diagnostic methods like immunohistochemistry and use of Vimentin, CD34, Smooth muscle actin and CD31. Hemangiopericytoma shows 98% sensitivity for vimentin while CD 31 is positive in lobular capillary hemangioma [8] as it happened in this case.

SUMMARY AND CONCLUSION

Thus it is clear that nasal mass whether benign or malignant can present with an array of different clinical pictures. In our case the presenting signs and symptoms were suggestive of hemangiopericytoma but biopsy report from two different

places revealed same diagnosis i. e. Lobular capillary hemangioma but due to clinical suspicion immunohistochemistry was done which altered the final diagnosis to hemangiopericytoma. This is also important from patient point of view as both these tumours behave in an entirely different fashion. So immunohistochemistry plays an important role in cases where biopsy report is misleading whereby differentiating between various masses by means of different stains. One must remember that this facility is not present at every centre as well as every patient can not afford it so it is very important for the treating surgeon to look at every nasal mass with suspicion especially in middle aged and elderly patient and keep a close look on the follow up.

References

1. Stacey E, Mills. Nose, Paranasal sinuses, and Nasopharynx, Sternberg' Diagnostic surgical pathology: vol.2, 2nd edition: 987-990.
2. Barnes. Tumours and Tumour- like lesions of the soft tissues, Surgical pathology of Ear, nose and throat, 2nd Ed., vol.2 2001: 984-989.
3. Stout AP, Murray MR. Hemangiopericytoma: a vascular tumor featuring Zimmermann's pericytes. Ann Surg 1942; 116:26-33.
4. Mc Master MJ, Soule EH, Irins JC, Hemangiopericytoma: a Clinicopathologic study & longterm follow up of 60 patients. Cancer 1975; 36: 2232-2244.
5. Kazuo Watanabe, MD; Atsuko Saito, MD; Masahiro Suzuki, MD; Shu Yamanobe, MD; Toshimitsu Suzuki, MD. True Hemangiopericytoma of the Nasal Cavity, Immunohistochemical and Electron Microscopic Study of 2 Cases and a Review of the Literature on Sinonasal Hemangiopericytomas,. Archives of Pathology and Laboratory Medicine: Vol. 125, No. 5, pp. 686-690.
6. Zagólski O, Kulisiewicz J, Keku J, Czajewski K Pol Merkur Lekarski. Sinonasal hemangiopericytoma of the nasal septum removed under endoscopic guidance. PMID 16886573 2006. Apr; 20 (118): 445-7.
7. NASAL GLIOMA- A DIAGNOSTIC CHALLENGE J.P.Dabholkar¹, N.U. Sathe², A.D.Patole³ Am J Surg Pathol. 1990 Sep; 14(9):856-66.
8. Lewis JE, Hughes KV III, Kasperbauer JL. Hemangiopericytoma: light microscopic and immunohistochemical features, Am J Clin Pathol 1982; 98: 348.

Author Information

Binay Kumar, M.B.B.S, MD Associate Professor

Pathology Dept, Govt.Medical College

Uttarakhand, India

binaypgi@yahoo.co.in

Bhawana Pant, M.B.B.S, M.S Assistant Professor

ENT Dept., Govt.Medical College

Uttarakhand, India

D.K. Isser, M.B.B.S, DLO, D.O.M S, M.S Professor &Head of the Department

Ear, Nose and Throat, Govt.Medical College

Uttarakhand, India