

Case Report: A Rare Case Of Bipolar Segmental Clavicle Fracture Associated With Multiple Rib Fractures

M Zertalis, B Madhavan, R Botchu

Citation

M Zertalis, B Madhavan, R Botchu. *Case Report: A Rare Case Of Bipolar Segmental Clavicle Fracture Associated With Multiple Rib Fractures*. The Internet Journal of Orthopedic Surgery. 2013 Volume 21 Number 2.

Abstract

Bipolar segmental clavicle fractures defined as combined ipsilateral fractures of the medial and lateral third of the clavicle are uncommon injuries with only four cases published to date. In 22% of patients presenting to the Emergency Department with a segmental injury, fracture of the medial third of the clavicle is not visualised on plain radiographs. We present a case of bipolar segmental clavicle fracture with associated rib fractures and describe the importance of the mechanism of injury for detecting a segmental fracture and its associated complications. We believe this to be the first reported case of bipolar segmental fracture with multiple rib fractures in literature.

CASE REPORT

A 50-year-old male presented to the Emergency Department with pain localised over the left clavicle following a fall while mountain biking. On examination there was an obvious deformity of the left clavicle with tenderness over the medial and lateral thirds of the clavicle. Plain radiographs revealed minimally displaced transverse fractures of the medial and lateral thirds of the left clavicle as well as fractures of the 2nd, 3rd, and 7th ribs (Figure 1). Acromioclavicular and sternoclavicular joints were intact. There was no evidence of pneumothorax and the patient was managed in a broad arm sling and referred to fracture clinic. Fractures of the medial clavicle and 2nd, 3rd, and 7th ribs were not detected until the patient attended fracture clinic.

The patient was further investigated with a computed tomography (CT) scan that revealed a Craig Type IIIa minimally displaced extra-articular medial third fracture and a Craig Type IIa minimally displaced extra-articular lateral third fracture (Figure 2). The patient was treated conservatively with immobilisation in a broad arm sling for 4 weeks and subsequent gentle mobilisation without any complication.

DISCUSSION

The three most common causes for clavicle fractures include fall, sports and road-traffic accidents with an annual incidence of 29 per 100,000 population¹. These are 2.5 times more common in males comprising up to 10% of all adult fractures¹⁻⁴. For males there is a peak incidence between 13

and 20 years of age with the lowest incidence noted in the sixth and seventh decade. In females there is a bimodal distribution of clavicle fractures with the highest incidence noted under the age of 20 and over 80 years of age. In the young population the commonest cause is sports whereas in the elderly, clavicle fractures are attributed to low-energy falls⁵. The middle third is most frequently fractured with the medial third attributing to just 2% of clavicle fractures⁴. Combined fractures of the middle and lateral third or the middle and medial third defined as segmental fractures are which even less common comprising less than 1% of clavicle fractures⁵. Combined fractures of the medial and lateral third classified as bipolar segmental injuries are rare with only four case reports published to date.

The first classification system for clavicle fractures was described by Allman in 1967 dividing the clavicle anatomically to medial, middle and lateral thirds⁶. Neer introduced a classification system focusing on lateral third fractures reinforced by Craig in 1990 (Table 1)^{7, 8}. Medial, mid-shaft and undisplaced lateral third fractures have a good prognosis when treated conservatively with operative management focusing on displaced lateral third fractures, in particular those medial to the trapezoid ligament as non-union rate following conservative management can be as high as 56%⁹. The evidence for the management of segmental clavicle fractures remains controversial. With regards to the four cases of bipolar segmental injuries published to date, two cases were managed operatively and

two cases were managed conservatively10-13. In three cases the decisive factor for choice of treatment, which also applies to our case, was the degree of displacement10-12. In one of the two cases managed with open reduction and internal fixation, both the medial and lateral fragments were displaced and in the second case the lateral fragment was displaced medial to the trapezoid ligament10, 11. In the third case there was minimal displacement and the patient responded well to conservative management12. In the fourth case the degree of displacement was not stated13.

The most widely recognised mechanism for clavicle fractures is a direct force to the adducted shoulder following a fall14. Medial third fractures result from a high energy impact and it has been suggested that a segmental fracture is the result of multiple, direct, high energy blows to the clavicle which applies to our case10, 12.

In a review of 55 patients with medial clavicle fractures 22% of medial clavicle fractures were not identified on plain radiographs with 90% of patients suffering additional injuries the most common being rib fracture (40%), pulmonary contusion, respiratory failure or ARDS (30%) and upper extremity injury (25%). Other complications included lower extremity injury, head injury, cervical spine injury, facial fracture and visceral injuries5. Concomitant injuries associated with segmental clavicle fractures including isolated rib fracture, pneumothorax, head injury and otorrhagia have been described in previous case reports. We believe this to be the first reported case of bipolar segmental fracture with multiple rib fractures in literature15, 16.

CONCLUSION

Bipolar segmental clavicle injuries are rare. The management of segmental injuries remains controversial, however the complications associated with a segmental injury can be detrimental to a patient’s outcome. Despite the fact that medial clavicle injuries maybe difficult to visualise on plain radiographs the diagnosis of a segmental injury should be suspected in a patient with a history of high energy force to the clavicle. Although a CT scan to identify a medial third injury may not be appropriate during the first attendance of the patient at the Emergency Department, the aforementioned complications should be sought based on the history and excluded by carrying a comprehensive secondary survey, requesting a chest radiograph and obtaining an arterial blood gas.

Table 1
Craig Classification of Clavicle Fractures

Type I	Fracture of the middle third
Type II	Fracture of the lateral third
a.	Minimally displaced
b.	Displaced secondary to fracture line medial to the coracoclavicular ligaments
1.	conoid and trapezoid attached
2.	conoid torn, trapezoid attached
c.	Intra-articular
d.	Periosteal sleeve fracture (children)
e.	Comminuted
Type III	Fracture of the medial
a.	Minimally displaced
b.	Displaced
c.	Intra-articular
d.	Epiphyseal separation (children)
e.	Comminuted

Figure 1
Plain radiographs showing: A) lateral third clavicle fracture and B) medial third clavicle fracture (white arrow) as well as 2nd rib fracture (white arrowhead).

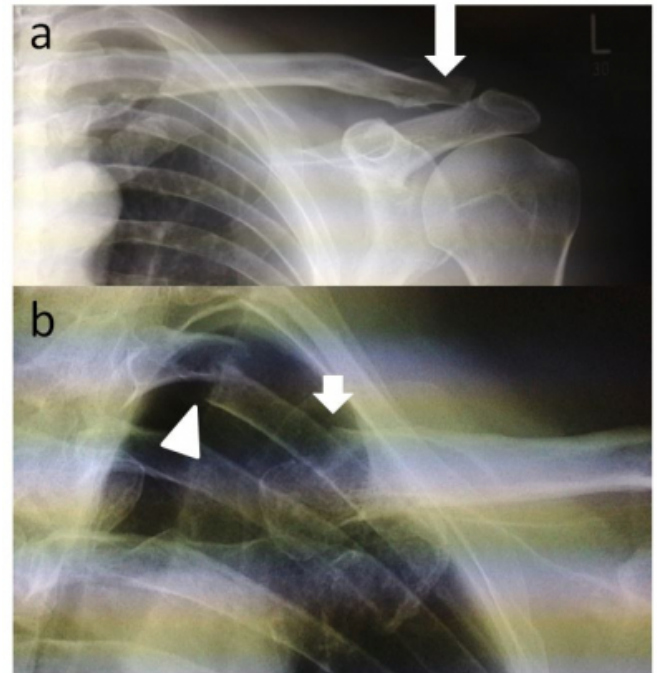
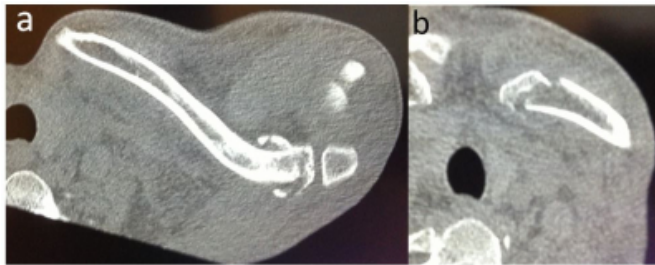

Figure 2

CT images showing: A) Craig Type IIa minimally displaced extra-articular lateral third fracture and B) Craig Type IIIa minimally displaced extra-articular medial third fracture.



References

1. Robinson CM. Fractures of the clavicle in the adult, epidemiology and classification. *J Bone Joint Surg Br.* 1998; 80:476–84.
2. Khan K, Bradnock TJ, Scott C, Robinson CM. Current concepts review. Fractures of the clavicle. *J Bone Joint Surg Am.* 2009; 91:447–60.
3. Nordqvist A, Petersson C. The incidence of fractures of the clavicle. *Clin Orthop Relat Res.*1994; 300:127–32.
4. Postacchini F, Gumina S, De Santis P, Albo F. Epidemiology of clavicle fractures. *J Shoulder Elbow Surg.* 2002; 11:452–6.
5. Throckmorton T, Kuhn JE. Fractures of the medial end of the clavicle. *J Shoulder Elbow Surg Am.*2007; 16:49–54.
6. Allman FL Jr. Fractures and ligamentous injuries of the clavicle and its articulation. *J Bone Joint Surg Am.* 1967;49(4):774-84
7. Neer CS II. Fractures of the distal thirds of the clavicle. *Clin Orthop.* 1968;58:43-50
8. Craig EV, Rockwood CA, Jr, Matsen FA., 3rd. The shoulder. Philadelphia: WB Saunders; 1990. Fractures of the clavicle; pp. 367–412.
9. Rokito AS. A comparison of operative and non-operative treatment of Type II distal clavicle fractures. *Bull Hosp Jt Dis.* 2002-2003; 61(1-2):32-9.
10. Heywood R, Clasper J. An unusual case of segmental clavicle fracture. *J R Army Med Corps.*2005; 151:93–4.
11. Miller D, Smith KD, McClelland D. Case Report: bipolar segmental clavicle fracture. *Eur J Orthop Surg Traumatol.* 2009; 19:337–9.
12. Sethi K, Newman D.S S, Bhattacharya R. An unusual case of bipolar segmental clavicle fracture. *Orthop Rev (Pavia).* 2012 Sep 4; 4(3):e26.
13. Pang KP, Yung SW, Lee TS, Pang CE. Bipolar clavicular injury. *Med J Malaysia.* 2003;58:621–4
14. Rockwood & Green's Fractures in Adults. Lippincot Williams and Wilkins 2006; (6):1212-1252
15. Osman N, Sinopidis C, Gibson L. Unusual segmental fracture of the clavicle associated with rib fractures and pneumothorax. *The Internet Journal of Orthopaedic Surgery.* 2009; 15 (2)
16. Grossi EA. Segmental Clavicle Fracture. *Rev Bras Ortop.* 2001;46(6):733-735

Author Information

Marios Zertalis, BMedSci (Hons); MBBS (Hons) Senior House Officer

Department of Trauma & Orthopaedics Kettering General Hospital

Kettering Northamptonshire

Marios.zertalis@doctors.org.uk

Baiju Madhavan, MBBS, FRCS (Ortho) Consultant Trauma & Orthopaedics

Department of Trauma & Orthopaedics Kettering General Hospital

Kettering Northamptonshire

Rajesh Botchu, MBBS, MS (Orth), MRCSEd, MRCSI, FRCR Consultant Radiologist

Department of Radiology Kettering General Hospital

dr Rajesh Botchu@gmail.com