

# A Technique To Retrieve A Broken Probe During Shoulder Arthroscopy: A Technical Tip

A Yewlett, A Bhattacharjee, H Mehta, R Kulkarni

## Citation

A Yewlett, A Bhattacharjee, H Mehta, R Kulkarni. *A Technique To Retrieve A Broken Probe During Shoulder Arthroscopy: A Technical Tip*. The Internet Journal of Orthopedic Surgery. 2014 Volume 22 Number 1.

## Abstract

Instrument breakage is an extremely rare complication and as a result many surgeons may not be familiar with dealing with it. We describe a simple technique that other arthroscopic surgeons may find helpful in the event of instrument breakage in their day to day practise.

## INTRODUCTION

Arthroscopy is a valuable technique used by the majority of practising orthopaedic surgeons. It is a predominantly safe and reliable technique but as with all surgical interventions it has inherent risks. The commonest complications of arthroscopy include haemarthrosis, articular injury, stiffness or adhesions and nerve injury.<sup>7</sup> Instrument failure by comparison is very rare.

The incidence of complications is also governed by the site of surgery and the rate of complications in shoulder arthroscopy is small of the order of 0.7% in some studies<sup>7</sup>. There are a number of case reports describing instrument breakage in both open and arthroscopic surgery. (1-2) To the best of our knowledge there have not been any other reported cases of broken instruments from shoulder arthroscopy. In this article we describe the failure of an arthroscopic probe used during shoulder arthroscopy and the techniques utilised to aid its extraction.

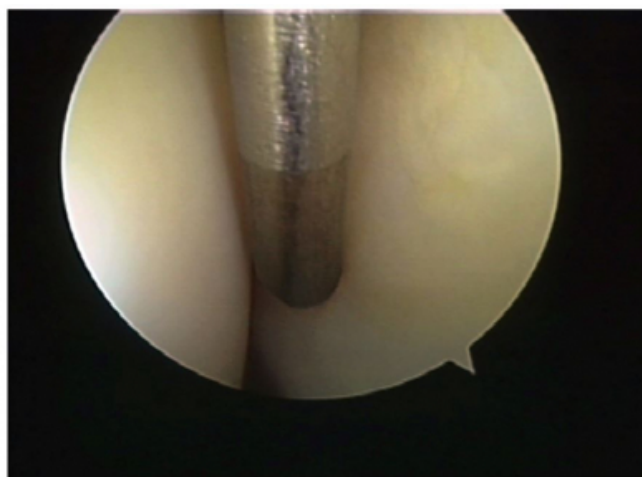
## SURGICAL TECHNIQUE

A fit forty seven year old right hand dominant man underwent shoulder arthroscopy for a subacromial decompression and removal of a calcific deposit from his right shoulder for impingement. The patient was in the beachchair position and draped in a conventional manner. Under general anaesthesia a posterior and lateral portal was placed and routine bursoscopy and glenohumeral arthroscopy had been performed uneventfully.

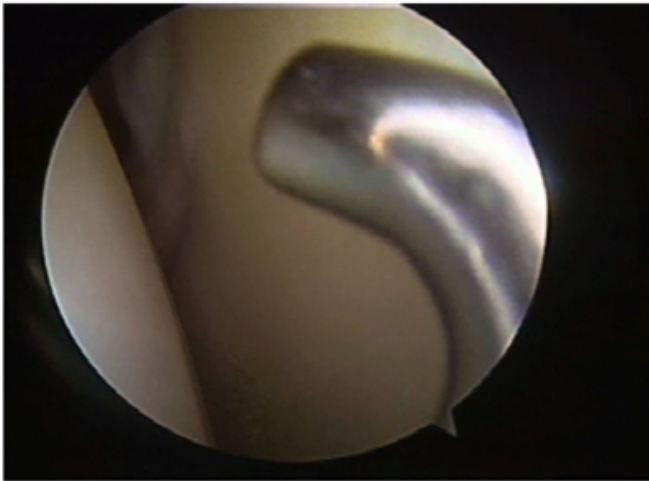
A Wolf Hook probe© was used to probe the calcific deposit. Whilst probing the deposit, the end of the probe

broke. The broken end of the probe then fell through a small tear in the rotator cuff into the glenohumeral joint below and settled in the axillary pouch. (See figures 1 and 2.)

Figure 1

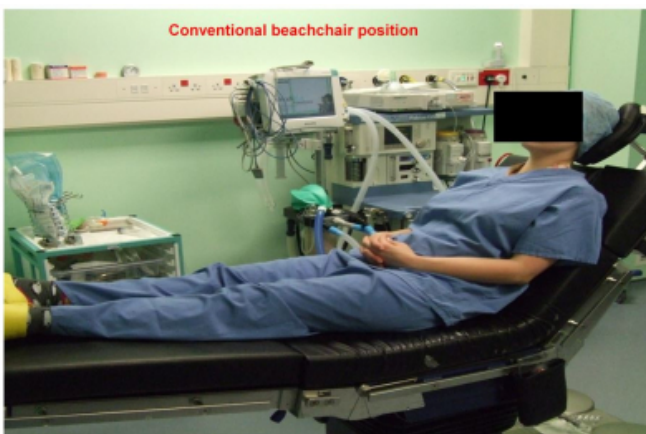

**Figure 2**

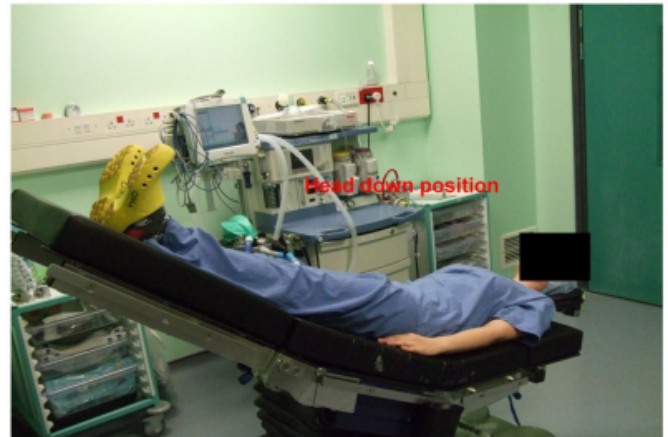

In order to extract the broken end, we tried a number of techniques that took around twenty minutes. Removal was hindered by the 5mm size of the broken fragment, the shape of the broken end as it was circular in shape and the fact that arthroscopic grabbing instruments have teeth that aid grasping of soft tissue but cannot easily grasp round metal objects. Finally we changed the patient's position from a head up to a head down tilt. This manoeuvre displaced the broken end of the probe enough to allow it to be grasped with conventional arthroscopic graspers with difficulty. See figures 3 and 4.

**Figure 3**



**Figure 4**



By the time the broken piece had been extracted the shoulder had become too swollen to complete the operation. At that stage the operation was abandoned and the wounds closed. A full disclosure was made to the patient of what had happened after he had recovered. He initially had some significant discomfort and restriction of movement in his shoulder post operatively, and his initial symptoms were unsurprisingly unchanged.

Repeat surgery was scheduled for six weeks later to complete the original operation. This went uneventfully. The patient has now had resolution of his symptoms and an excellent functional outcome.

## **DISCUSSION**

Instrument breakage is a rare complication of arthroscopic procedures<sup>4</sup>. Shoulder arthroscopy in general has fewer complications than knee arthroscopy.<sup>8</sup> Different studies have reported an instrument failure rate of between 0.18%<sup>5</sup> and 0.35%.<sup>4</sup> Although there have been a number of case reports highlighting the issues of difficulties in retrieving broken instruments from the knee joint, this is the first report of such a problem in the shoulder joint to the best of our knowledge. In our case we believe that the probe broke as it was levered against the humeral head.

In the event that arthroscopic instrument breakage occurs, it is advised<sup>3</sup> that the operating surgeon does the following: stop the operation, stay calm, perform a systematic arthroscopic examination of the joint to localise the broken fragment. It has also been recommended that a magnetic retriever and X-ray control be made available for this purpose<sup>3</sup>.

Broken pieces of hand-held arthroscopic tools usually migrate to the most dependent part of the joint. The reason

for this migration could be due to the positive inflow pressure in the joint and momentary panic, which may result in unwanted movement of instruments. In addition the patients positioning will govern which part of the joint is the most dependent. In our case the patient was in the beach chair position, consequently the axillary pouch was the dependent position.

The difficulty in our case was that the patient was having a subacromial decompression done for impingement, and had an otherwise very stable shoulder.

In this instance we were unable to reach the probe using conventional arthroscopic instruments whilst it was in the axillary pouch due to the cumulative effect of the swelling of the shoulder from the inflow supply and also from the inherent tightness of his glenohumeral joint.

Surgical options for removing retained pieces include arthroscopic techniques, open techniques and the use of magnetic retrievers. Due to the close proximity of important neurovascular structures an open approach was not desirable in this case. A magnetic retriever is not available at our institution which clearly precluded this.

Arthroscopic techniques that were tried in this instance included turning off the fluid inflow as the pressure of the inflow was felt to be pushing the retained fragment away from the operator. However once the inflow was turned off, the pressure in the joint was no longer high enough to keep the soft tissues distended enough to allow adequate visualisation. We also tried direct axillary pressure to displace the retained fragment but without success.

In order to move the fragment into a position that was accessible we liaised with our anaesthetic colleagues and placed the patient into the head down position from the beach chair position. This then moved the broken fragment sufficiently that it could be grabbed and removed.

In all cases of retained fragments from broken instruments every effort should be made to remove the broken pieces but on occasion they can still not be removed. When this occurs, some authors recommend that the broken pieces be left in the joint, as it has been shown that retained fragments even as large as 2cm- long can remain asymptomatic for a long period. Although there have not been any documented case reports about this to the best of our knowledge, personal communication with other shoulder arthroscopists have shown a consensus that there are several parts of the shoulder where it is believed that it is unlikely that a metal

fragment would become a problem. One location is the subscapularis recess where it is unlikely to be found or to be symptomatic. The other location is the axillary pouch where the fragment would settle and probably stay.

Although we did manage to retrieve the broken instrument in this case, the associated soft tissue swelling which made it impossible to complete the original operation secondary to our efforts to do so could have possibly been avoided had we tried this technique earlier. Clearly aborting the original operation and rescheduling it for another time has its own inherent risks, but this must be weighed up against the risks of unsatisfactory surgery due to inadequate visualisation secondary to soft tissue swelling.

Due to a lack of empirical evidence, it is impossible to recommend what is best to do in these extremely unusual circumstances for other surgeons, and we feel that the operating surgeon must take a view based on the individual case at the time of surgery.

We do not routinely consent patients for instrument failure preoperatively as the incidence is extremely low. We do advise that if an instrument breaks during an orthopaedic procedure, accurate documentation of the event in the surgical record is mandatory along with a full disclosure to the patient.

Proper patient positioning is critical to all orthopaedic techniques and it is vital that the operating surgeon be prepared to change a patient's position intraoperatively if necessary in the event of unexpected complications, with the help of the anaesthetic team to secure a better surgical result. In our case it was this change of positioning that allowed the retained fragment to be removed.

### **References**

1. Bisbinas I, Ho YM, Learmonth DJ. Reamer breakage in the femoral medulla during total knee arthroplasty: should reamers have a finite life? *J Arthroplasty*. 2004; 19: 510-3
2. Gambardella RA, Tibone JE. Knife blade in the knee joint: a complication of arthroscopic surgery. A case report. *Am J Sports Med* 1983; 11:267-8
3. Oztekin HH. An unusual complication of knee arthroscopy: an extra-articular migrated asymptomatic broken probe from the knee joint. *Arch Orthop Trauma Surg* (2005) 125: 285-287
4. Pichler W, Mazzurana P, Clement, H, Grechenig S, Mauschitz R, Grechenig W frequency of instrument breakage during orthopaedic procedures and its effects on patients. 90 (12) 2008 2652-2654 *JBJS (Am)*
5. Price MV, Molloy S, Solan MC, Sutton A, Ricketts DM. The rate of instrument breakage during orthopaedic procedures. *Int Orthop* . 2002; 26: 185-7
6. Sherman OH, Fox JM, Snyder SJ, Del Pizzo W, Friedman MJ, Ferkel RD et al Arthroscopy – 'no problem surgery': an

analysis of complications in two thousand six hundred and forty cases. J Bone Joint Surg Am 68:256-265

7.Small NC Complications in arthroscopic surgery of the knee and shoulder arthroscopy Orthopedics 1993 Sep;16(9):985-8

**Author Information**

**Alun Yewlett, MB BS MRCS (Eng) BSc (Hons)**

Royal Gwent Hospital

Newport, Wales

**Atanu Bhattacharjee, MBBS MRCS**

Royal Gwent Hospital

Newport, Wales

**Hemang Mehta, FRCS (Tr & Orth)**

Royal Gwent Hospital

Newport, Wales

**Rohit Kulkarni, FRCS (Tr & Orth)**

Royal Gwent Hospital

Newport, Wales