

# Umbilical Hernia in Cirrhotic Patients: When to Operate? Case Presentation and Literature Review

A A Mohamed, O Shareefi, K M Hussin, F S Alnehmi

## Citation

A A Mohamed, O Shareefi, K M Hussin, F S Alnehmi. *Umbilical Hernia in Cirrhotic Patients: When to Operate? Case Presentation and Literature Review*. The Internet Journal of Surgery. 2014 Volume 31 Number 1.

## Abstract

Patients with both cirrhosis and ascites have a 20% risk of developing umbilical hernia. Umbilical rupture and hernia strangulation are the most life-threatening complications of umbilical hernia with ascites and they demand urgent surgical intervention. We report a case of strangulated umbilical hernia in a male patient with Child's C post hepatitis C liver cirrhosis with massive ascites. We also review the literature for the optimal time for repair of umbilical hernias in patients with liver cirrhosis and ascites.

## INTRODUCTION

Historically, patients with liver cirrhosis and umbilical hernia are often managed conservatively because of high postoperative mortality and morbidity with high postoperative recurrence rates. The optimal management of patients with uncomplicated umbilical hernias and liver cirrhosis with ascites is not clear yet; however, many recent studies showed that conservative management of those patients is associated with a high incidence of morbidity and mortality, and that elective surgery is safe and effective in most patients.

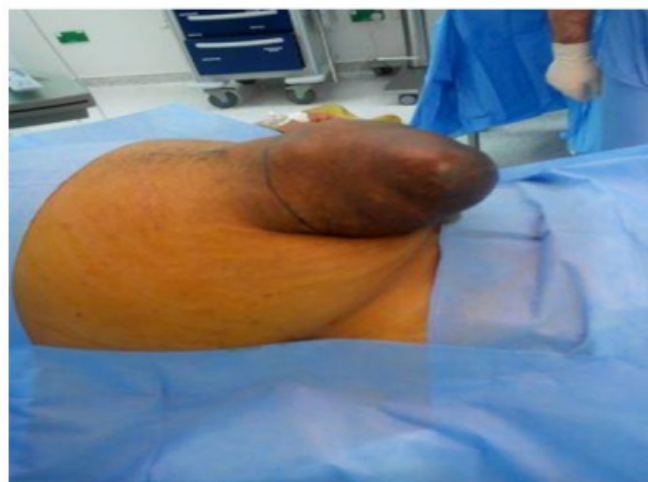## CASE REPORT

A 60-year-old man with Child's C hepatitis C induced liver cirrhosis complicated by massive ascites and huge umbilical hernia presented to our emergency department with lower abdominal pain and vomiting of 12 hours duration. He vomited once and he was not constipated. He was a known case of diabetes mellitus, hypertension and chronic renal failure on medical treatment. As his ascites was resistant to medical treatment he used to have frequent paracentesis for symptomatic relief.

On examination he was poorly nourished, dehydrated, not anemic or jaundiced, with a pulse rate of 88/minute and a blood pressure of 150/80mm of Hg. Abdominal examination revealed a fluid-distended abdomen with tenderness over the lower abdomen and absent bowel sounds. The hernia was irreducible but not tense or tender and there were no skin signs of strangulation (figure 1).

## Figure 1

showing the hernia.

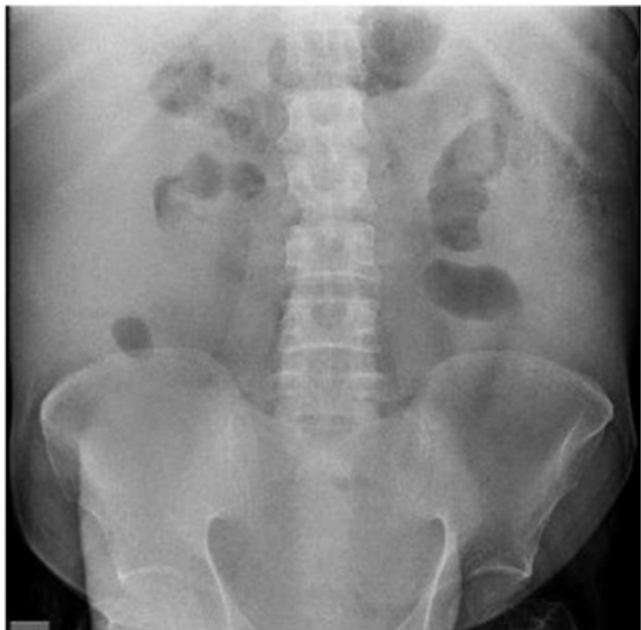

Laboratory investigations showed hemoglobin of 9.6 gram%, WBCC of  $4.4 \times 10^3$ , Urea of 18.6 mmol/L and creatinine of 280  $\mu\text{mol/L}$ . Liver function test showed bilirubin of 48mmol/L and albumin of 23gram/L with markedly deranged liver enzymes. INR was 1.1 and platelet count was  $150 \times 10^3$ .

The plain X-rays of the abdomen showed dilatation of a proximal loop of small bowel and absence of air within the colon (figure 2).

**Figure 2**

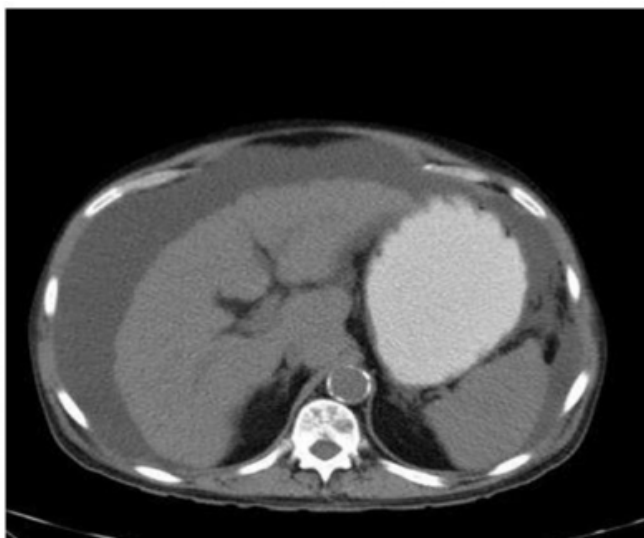Plain X-ray of the abdomen showing dilatation of a proximal loop of small bowel and absence of air within the colon



The CT with oral contrast demonstrates the liver cirrhosis, the massive ascites and a loop of small bowel within the hernia sac with failure of the oral dye to enter in it. There was no significant proximal small-bowel dilatation. The viability of the bowel was difficult to assess as no intravascular contrast was administered due to the poor renal function (Figure 3, 4 and 5).

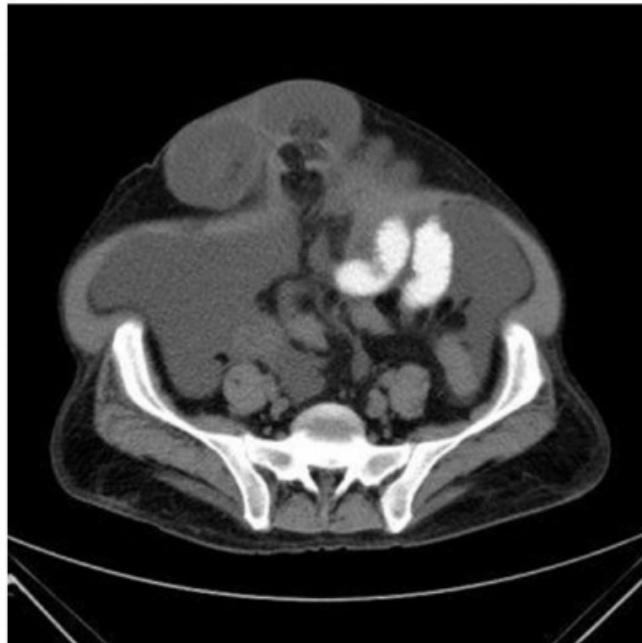
**Figure 3**

The CT with oral contrast demonstrating the liver cirrhosis and the massive ascites.



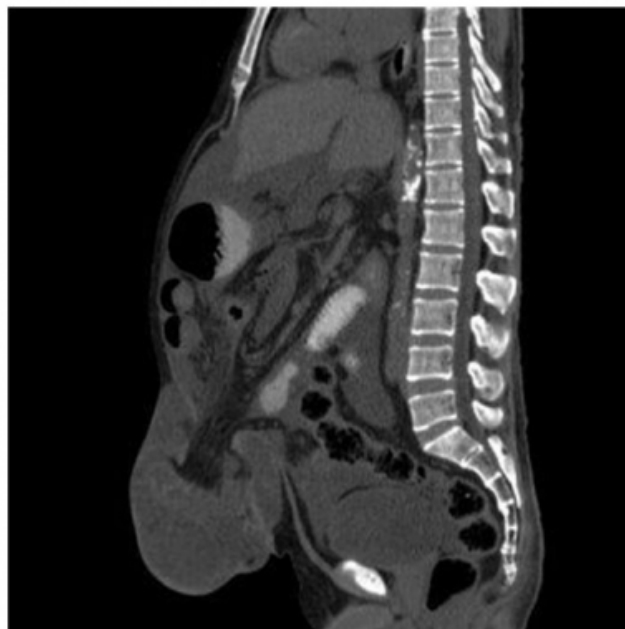**Figure 4**

The CT with oral contrast showing failure of the dye to enter the loop of the bowel within the hernia sac.



**Figure 5**

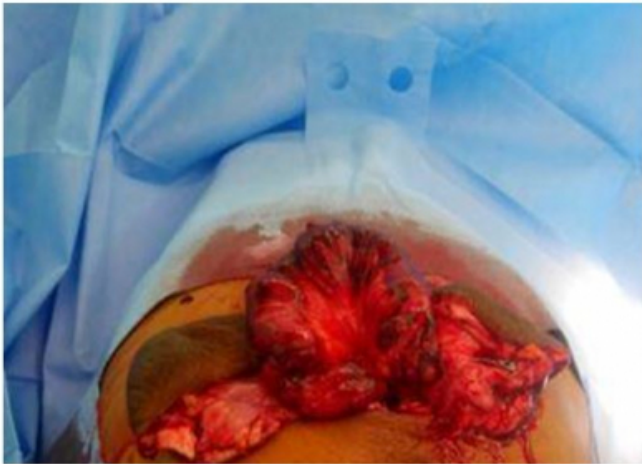The CT with oral contrast (sagittal view) showing the same finding as in figure 4.



After an initial period of fluid resuscitation the hernia was explored under general anesthesia. A loop of small bowel was found within the hernia sac which looked ischemic but not gangrenous (figure 6).

**Figure 6**

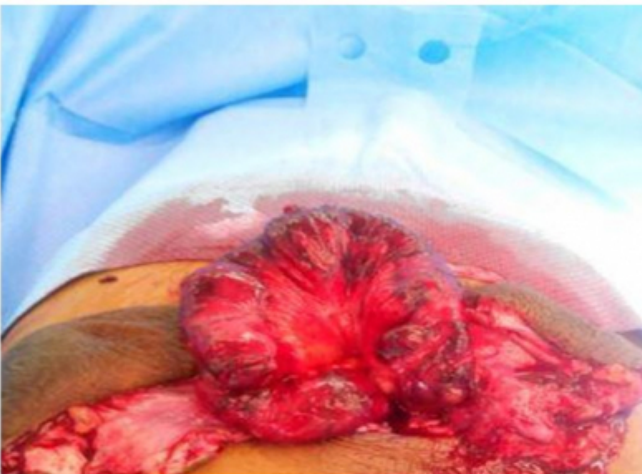showing the loop of small bowel that was in the hernia sac.



The bowel was revascularised after widening the neck of the sac and releasing of the constricting fascia. There was no need for bowel resection (figures 7&8). There was significant loss of ascitic fluid during surgery and a suction drain was placed in the pelvis to control the ascites postoperatively.

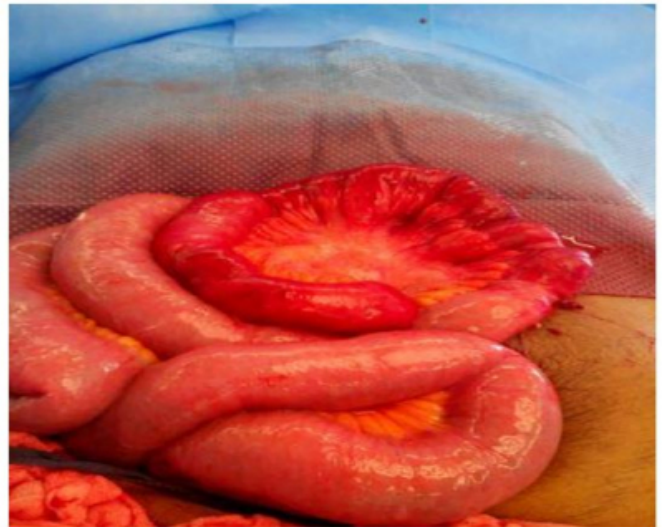**Figure 7**

showing the bowel starting to revascularise after widening the hernia defect.



**Figure 8**

showing complete revascularization of the bowel.



The hernia defect was closed in two layers and reinforced by a prosthetic mesh of polypropylene (figure 9).

**Figure 9**

showing hernia repair with prosthetic mesh of polypropylene.



The postoperative period was complicated with pneumonia but he made a good recovery.

## **DISCUSSION**

Patients with both cirrhosis and ascites have a 20% risk of developing an umbilical hernia (1). The important contributory factors in the development of the hernias in cirrhotic patients include weakness of the fascia and abdominal muscles due to bad nutritional state, enlargement of the pre-existing opening in the supraumbilical fascia promoted by dilatation of the umbilical vein in patients with portal hypertension and, especially, increasing of abdominal pressure as the result of the ascites formation (2).

Ascites plays a key role in the development of umbilical hernia as well as development of complications in cirrhotic patients. Both tense ascites and rapid evacuation of ascitic fluid may cause an umbilical hernia to complicate as the tense ascites stands behind the enormous increase in intra-abdominal pressure while rapid uncontrolled evacuation may precipitate an incarcerated hernia. (3, 4)

Untreated umbilical hernias in the presence of tension on the abdominal wall due to ascites result in loss of vascularization of the skin over the hernia together with the risk of scarification, necrosis and rupture. This type of complication is common and can cause bacterial peritonitis with high mortality (5). Strangulation, although rare especially in patients with ascites, is also a serious complication of these hernias and accounts for about 10% to 20% of herniorrhaphies (6).

Elective abdominal procedures in cirrhotic patients, like surgical repair of umbilical hernias, have been traditionally discouraged because of the high morbidity and mortality as a complication of cirrhosis. They include thrombocytopenia, coagulopathy, ascites, portal hypertension and renal failure, among others. Moreover, it is possible to observe an increased risk of postoperative liver decompensation and possible impairment of wound healing due to frequent bad nutritional state of the patients (7, 8).

In a retrospective analysis (from 1992 to 1999) of 40 patients with cirrhosis who underwent non-hepatic surgical procedures, the presence of tense ascites, low albumin value, deranged prothrombin time, activated partial thromboplastin time, together with the emergency of the operation, was significantly correlated with a mortality of 7.1% in Child's class A, of 23% in class B, and of 84% in class C (9).

Garrison et al. (10) noted that the post-operative mortality, both in elective and in urgency procedures, increased with the severity of the patient, stratified by Child criteria (death of 10%, 31% and 76% in Child groups A, B and C, respectively).

In the series reported by the French Association of Surgery, which included 81 patients who underwent surgical treatment for umbilical hernia, overall mortality was 5%: 11% after emergency surgery for ruptured or strangulated umbilical hernia and 2% after elective surgery (11, 12).

Optimal management in patients with umbilical hernias and liver cirrhosis with ascites is still under debate (13). Minimization or elimination of ascites is the mainstay of

success of surgical repair. Most often, shunting was recommended either before or at the time of surgical repair (3, 14). Studies showed that use of shunt, either by temporary peritoneal dialysis catheter or transjugular intrahepatic portosystemic shunting, significantly reduces the incidence of recurrence and wound dehiscence (15,16 and 17). The advent of liver transplantation gave liver transplant candidates the option of umbilical hernia repair during the transplant operation. This was a strong indication for conservative management while awaiting liver transplantation (18).

Umbilical rupture and hernia strangulation are the most life-threatening complications of umbilical hernia with ascites and they demand urgent surgical intervention (19).

Decision to operate in patients with uncomplicated umbilical hernias and liver cirrhosis with ascites is difficult and requires careful weighing of the expected benefit against the probable postoperative morbidity and mortality.

Historically, patients with liver cirrhosis and umbilical hernia were often managed conservatively because of high postoperative mortality and morbidity with high postoperative recurrence (20).

Marsman et al. (13) compared elective repair with conservative management for umbilical hernia in patients with ascites during the era of liver transplantation. Thirty-four patients were studied: 17 had elective hernia repair, 13 were managed conservatively, and 4 underwent hernia repair during liver transplantation. Elective hernia repair was successful without complications and recurrence in 12 out of 17 patients. Complications occurred in 3 of these 17 patients, consisting of wound-related problems and recurrence in 4 out of 17. Success rate of the initial conservative management was only 23%; hospital admittance for incarcerations occurred in 10 of 13 patients, of which 6 required hernia repair in an emergency setting. Two patients of the initially conservative managed group died from complications of the umbilical hernia. In the 4 patients that underwent hernia correction during liver transplantation, no complications occurred and 1 patient had a recurrence. They concluded that conservative management of patients with umbilical hernia is associated with a high incidence of morbidity and mortality, and that elective operation is effective in most patients.

McKay et al (5) performed an extensive review of the literature since 1980 together with a survey to obtain expert

consensus to supplement any available conclusions from the literature. Nineteen surgeons (45%) responded to the survey. For asymptomatic hernias, all would consider hernia repair in Child's A cirrhosis, but not in more advanced disease, whereas the vast majority would consider the repair of complicated hernias. However, they observed that the recent literature demonstrates much lower morbidity and mortality of elective repair than in the past. They concluded that the early repair of umbilical hernias in patients with cirrhosis and ascites is safer than it was in the past and can be considered for selected patients. This may avoid increased morbidity and mortality associated with urgent repair later on. The control of ascites is critical to a successful outcome. Urgent repair of umbilical hernia in cirrhotic patients is indicated when complications develop.

Similarly Silva et al (7) performed a literature review in 2012 with the key-words "abdominal wall hernia" and "cirrhotic patients" using the PubMed database and reviewing twenty-eight articles. Although they reported that elective surgery has achieved a major position in managing this condition in order to reduce morbidity and mortality and improve the quality of life, they concluded that only few studies with large samples have been conducted so far and there is no consensus on which conduct is the most suitable taking into consideration rates of morbidity and mortality.

Eker et al. (1) assessed the safety and efficacy of elective umbilical hernia repair in patients with liver cirrhosis and ascites. They prospectively studied 30 patients (25 males and 5 females) who underwent elective repair at a mean age of 58 years. Six patients were classified as CPT grade A (20%), 19 patients (63%) as grade B, and 5 patients (17%) as grade C. The median duration of hospital stay was 3 days. None of the patients were admitted to the intensive care unit. There were no postoperative complications apart from that one patient developed postoperative pneumonia and one patient developed decompensation of cirrhosis. After a median follow-up period of 25 months two patients suffered recurrence. They concluded that elective umbilical hernia repair is safe and the preferred approach in cirrhotic patients with ascites.

Choi et al. (21) compared the outcome of emergency versus elective umbilical hernia repair in 33 cirrhotic patients. The overall morbidity and mortality rates following herniorrhaphy were 42% and 6.5%. They observed significantly higher postoperative complications in the emergency operation group. The operative time and postoperative hospital stay were significantly shorter in the

elective operation group than in emergency operation group. They concluded that early, elective repair of umbilical hernias in cirrhotic patients should be advocated considering the hepatic reserve and patient's condition.

From evidence available in the present literature many authors concluded that optimal management of patients with liver cirrhosis and umbilical hernia yet remained uncertain. Complicated umbilical hernia in patients with liver cirrhosis and ascites demands urgent surgical intervention regardless of estimated morbidity and mortality as surgical intervention is considered as life saving in those patients. In patients who are candidates for liver transplantation, a more conservative approach while awaiting definitive surgical repair concurrent with liver transplantation is appropriate (13). In others, a more aggressive approach involving preoperative TIPS and optimization of nutrition followed by semi-urgent surgical repair (20, and 22) or concomitant treatment of both ascites and hernia by placement of a peritoneo-venous shunt at the time of the parietal repair (19) has been shown to have a lower than expected. A conservative approach of operating only in patients with complications from the umbilical hernia has a significantly poorer outcome (13).

### **SUMMARY**

Patients with both cirrhosis and ascites have a 20% risk of developing umbilical hernia. Complicated hernias in those patients demand urgent surgical intervention, regardless of estimated morbidity and mortality, as surgical intervention is considered as life saving. Optimal management of patients with uncomplicated umbilical hernias and liver cirrhosis with ascites is still debatable. Many recent studies showed that conservative management of those patients is associated with a high incidence of morbidity and mortality, and that elective operation is effective in most patients.

### **References**

1. Eker HH, van Ramshorst GH, de Goede B, Tilanus HW, Metselaar HJ, de Man RA, Lange JF, Kazemier G: A prospective study on elective umbilical hernia repair in patients with liver cirrhosis and ascites. *Surgery*; 2011 Sep; 150(3): 542-6.
2. Shlomovitz E, Quan D, Etemad-Rezai R, McAlister VC: Association of recanalization of the left umbilical vein with umbilical hernia in patients with liver disease. *Liver Transplantation*; 2005; 11: 1298-1299.
3. Belghiti J, Durand F: Abdominal wall hernias in the setting of cirrhosis. *Semin Liver Dis*; 1997; 17: 219-26.
4. Lemmer JH, Strodel WE, Knol JA, Eckhauser FE: Management of spontaneous umbilical hernia disruption in the cirrhotic patient. *Ann Surg*; 1983; 198: 30-4.

5. McKay A, Dixon E, Bathe O, Sutherland F: Umbilical hernia repair in the presence of cirrhosis and ascites: results of a survey and review of the literature. *Hernia*; 2009; 13: 461-8.
6. Runyon BA, Juler GL: Natural history of repaired umbilical hernias in patients with and without ascites. *Am J Gastroenterol*; 1985; 80: 38-9.
7. Silva FD, Andraus W, Pinheiro RS, Arantes-Junior RM, Lemes MP, Ducatti Lde S, D'albuquerque LA: Abdominal and inguinal hernia in cirrhotic patients: what's the best approach? *Arq Bras Cir Dig*; 2012; 25: 52-5.
8. Lawson EH, Benjamin E, Busuttil RW, Hiatt JR: Groin herniorrhaphy in patients with cirrhosis and after liver transplantation. *Am Surg*; 2009; 75: 962-5.
9. Franzetta M, Raimondo D, Giammanco M, Di Trapani B, Passariello P, Sammartano A, Di Gesù G: Prognostic factors of cirrhotic patients in extra-hepatic surgery. *Minerva Chir*; 2003; 58: 541-544.
10. Garrison RN, Cryer HM, Howard DA, Polk HC, Jr.: Clarification of risk factors for abdominal operations in patients with hepatic cirrhosis. *Ann Surg*; 1984; 199: 648-55.
11. Bhangui P, Laurent A, Amathieu R, Azoulay D: Assessment of risk for non-hepatic surgery in cirrhotic patients. *J Hepatol*; 2012; 57: 874-84.
12. Gillet M: Chirurgie de la paroi chez le cirrhotique. In: Belghiti J, Gillet M, editors. *La chirurgie digestive chez le cirrhotique*. Paris: Monographies de l'AFC; 1993: 53-60.
13. Marsman HA, Heisterkamp J, Halm JA, Tilanus HW, Metselaar HJ, Kazemier G: Management in patients with liver cirrhosis and an umbilical hernia. *Surgery*; 2007; 142: 372-5.
14. Leonetti JP, Aranha GV, Wilkinson WA, Stanley M, Greenlee HB: Umbilical herniorrhaphy in cirrhotic patients. *Arch Surg*; 1984; 119: 442-445.
15. Slakey DP, Benz CC, Joshi S, Regenstein FG, Florman SS: Umbilical hernia repair in cirrhotic patients: utility of temporary peritoneal dialysis catheter. *Am Surg*; 2005; 71: 58-61.
16. Fagan SP, Awad SS, Berger DH: Management of complicated umbilical hernias in patients with end-stage liver disease and refractory ascites. *Surgery*; 2004; 135: 679-682.
17. Elsebae MM, Nafeh AI, Abbas M, Farouk Y, Sevam M, Raouf EA: New approach in surgical management of complicated umbilical hernia in the cirrhotic patient with ascites. *J Egypt Soc Parasitol*; 2006; 36(suppl): 11-20.
18. Perkins JD: Another patient with an umbilical hernia and massive ascites: what to do? *Liver Transpl*; 2008; 14: 110-1.
19. Loriau J, Manaouil D, Mauvais F: [Management of umbilical hernia in cirrhotic patients]. *J Chir (Paris)*. 2002; 139: 135-40.
20. O'Hara ET, Oliai A, Patek AJ Jr, Nabseth DC: Management of umbilical hernias associated with hepatic cirrhosis and ascites. *Annals of Surgery*; 1975; 181: 85-87.
21. Choi SB, Hong KD, Lee JS, Han HJ, Kim WB, Song TJ, Suh SO, Kim YC, Choi SY: Management of umbilical hernia complicated with liver cirrhosis: an advocate of early and elective herniorrhaphy. *Dig Liver Dis*; 2011; 43: 991-5.
22. Davidson CS, Yonemoto RH: Herniorrhaphy in cirrhosis of the liver with ascites. *New Engl J Med*; 1956; 255, 733-739.



**Author Information**

**Abbas AR Mohamed, MBBS, FRCSI, FICS, FACS, Consultant General and Laparoscopic Surgeon**

Department of Surgical Specialties, NGH

Madinah KSA

abbas\_ar@hotmail.com

**Osama Shareefi, MBBS, FRCS (Glasgow), Consultant Plastic Surgeon, Head of the Department**

Department of Surgical Specialties, NGH

**Khaled M. A. Hussin, M.B.Ch.B, Arab Board, Assistant Consultant General Surgery**

Department of Surgical Specialties, NGH

**Fawwaz S. A. Alnehmi, MBBS, Arab Board, Assistant Consultant Radiology**

Department of Surgical Specialties, NGH