

An In-Vivo Comparison Of The Efficacy Between Direct And Indirect Bonding Methods

P Premanand, A J Shankar

Citation

P Premanand, A J Shankar. *An In-Vivo Comparison Of The Efficacy Between Direct And Indirect Bonding Methods*. The Internet Journal of Dental Science. 2014 Volume 13 Number 1.

Abstract

Background and Aim: To compare and analyze the direct and indirect bonding techniques so as to determine whether one has any clinical significant advantage over other.

Materials and Methods: 20 patients [10 male & 10 female] in the age group 21 ± 3 yrs were chosen with the selection criteria being, no visible cracks on enamel, normal morphology of teeth and non extraction treatment plan. On each patient alternate tooth were bonded using direct or indirect bonding techniques, thereby the same patient served as both control and experimental group. Those teeth that were intended to be bonded by indirect technique were bonded [Transbond XT] first following which the other teeth were bonded by direct technique [Transbond XT] for ease of transfer tray placement.

Results: The patients were observed over 6 month's period for any bracket failure at each thrice weekly appointment. The number of bond failures in indirect bonding group was 20 while in the direct bonding group was 28.

Conclusion: There were no significant differences between the direct and indirect bonding techniques as regards bond failures.

INTRODUCTION

In recent years, the orthodontic specialty has almost totally switched to the bonded appliance in which brackets are placed on acid etched enamel. The placement of orthodontic bonded brackets may be accomplished by either a direct or indirect technique. Although most orthodontists place brackets directly, some clinicians prefer the indirect method and believe that it contributes to greater precision in bracket positioning and to a reduction in patient chair time.

Considering this, it is important; to compare and analyze these techniques to determine whether one has any clinically significant advantages over other.

MATERIALS AND METHODS

The study consisted of 20 patients [10 male & 10 female] chosen from the Dept of Dentistry in Chennai medical college hospital & research centre with the selection criteria being.

Age group – 21 ± 3 yrs

Non extraction treatment plan

Patients with no visible cracks on enamel.

Patients with normal morphology of teeth

The following materials were used for the present study.

Light cure adhesive system (Transbond XT, 3 M Unitek)
Pre adjusted edgewise appliance (American orthodontics – 0.018" slot)
Boones gauge
Graphite Marker
Acetate sheets
LED/Curing unit

BONDING METHOD

Brackets were bonded on the teeth either by direct or indirect bonding technique. On each patient alternate tooth were bonded using direct or indirect bonding techniques, enabling the same patient to serve as both control and experimental group. Those teeth that were intended to be bonded by the indirect technique were bonded first following which the other teeth were bonded by direct technique for ease of transfer tray placement. Bonding on the teeth was done according to the following procedure.

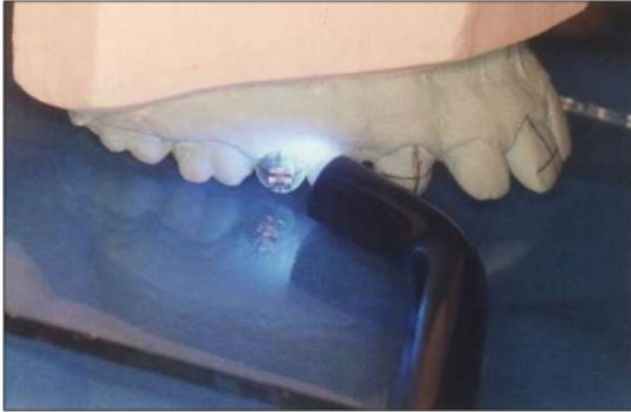INDIRECT BONDING

On the teeth that were chosen for indirect bonding technique, horizontal and vertical reference lines were drawn with the

help of a graphite marker using a Boone's gauge. The brackets were coated with the light cured adhesive and precisely positioned on the cast and cured with the light / LED curing unit for 20 seconds on mesial and distal aspects (Figures 1, 2&3). Care was taken that the plaster model was dry.


Figure 1

Photograph showing bracket positioned on cast and light cured



Figures 2 and 3


Photographs showing brackets in position on alternate tooth with reference lines as guide



Following bonding, the acetate sheets were taken and cut in the center to facilitate better adaptation on the cast. The prepared model was placed on the vacuum former and the heated acetate sheet was then pressed over it to form a transfer tray similar to the night guard appliance (Figure 4).

Figure 4

Photograph showing heated acetate sheet pressed over the cast on vacuum former



The tray after removal from the cast was trimmed so that it extended up to the cervical margin of the teeth (Figure 5). Following this, the adhesive on the bracket base was slightly roughened using a stone. The tray is now ready for bonding. The teeth to be bonded was etched with 37% phosphoric acid for 30 seconds, later it was rinsed with water and dried with a oil and water free air syringe (Figure 6). The primer was then applied on the etched surface and on the bracket base a small amount of adhesive was also placed on the bracket base. The tray was then positioned in the mouth (Figure 7) and cured for 20 seconds on both the mesial and distal aspects. Following this the tray was carefully peeled off, from the lingual side (Figure 8).

Figure 5

Photograph showing trimmed tray after removed from the cast

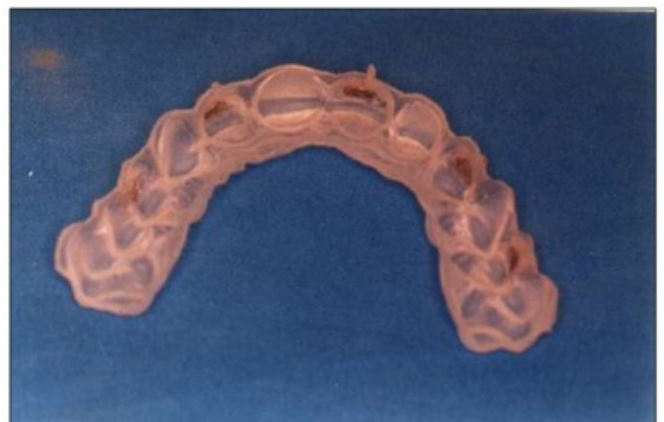


Figure 6

Photograph showing etched and dried alternate tooth for indirect bonding

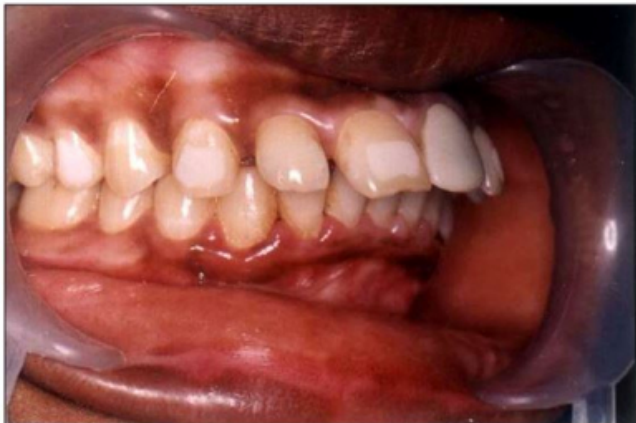

Figure 7

Photograph showing tray positioned in mouth for indirect bonding

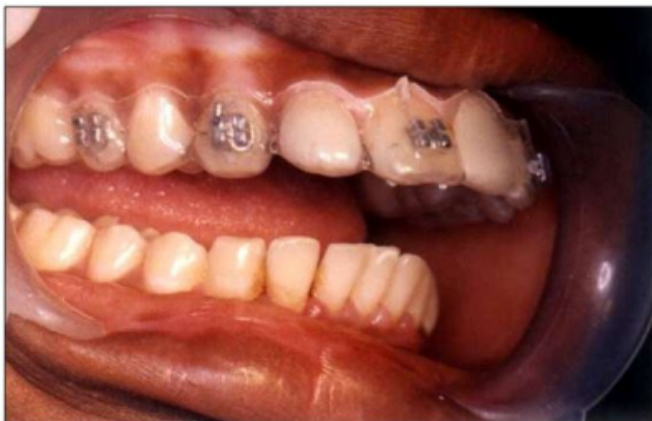
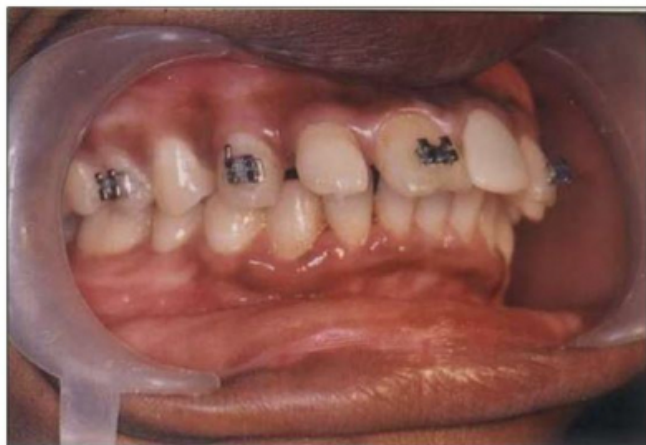
Figure 8

Photograph showing after indirect bonding the alternate tooth



DIRECT BONDING

In the direct bonding group, following etching of the enamel with 37% phosphoric acid and rinsing with water, the teeth were dried with an oil and water free air syringe. The surface was then scribed with a graphite marker using a Boone's gauge to locate the position of the bracket (Figure 9). Following this the adhesive was placed on the bracket base and positioned on the tooth according to the reference lines and cured for 20 seconds on both mesial and distal aspects of teeth (Figure 10). Patients were instructed with proper oral hygiene maintenance and care of the appliance.

Figure 9

Photograph showing graphite marking on alternate tooth for direct bonding

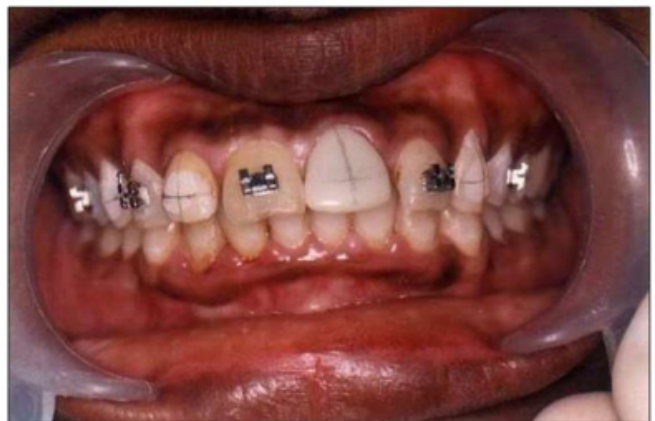
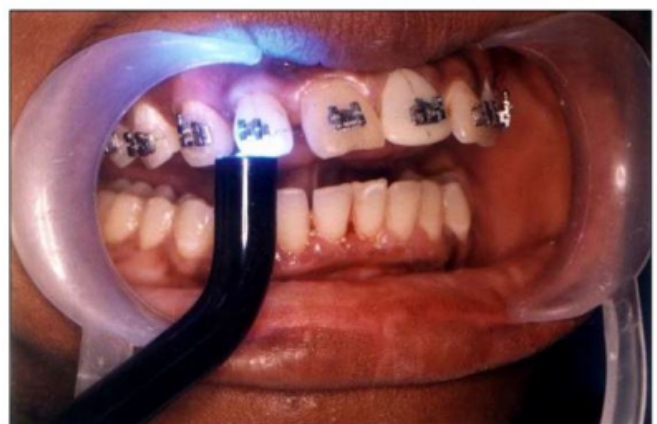
Figure 10

Photograph showing direct bonding the alternate tooth with light curing unit



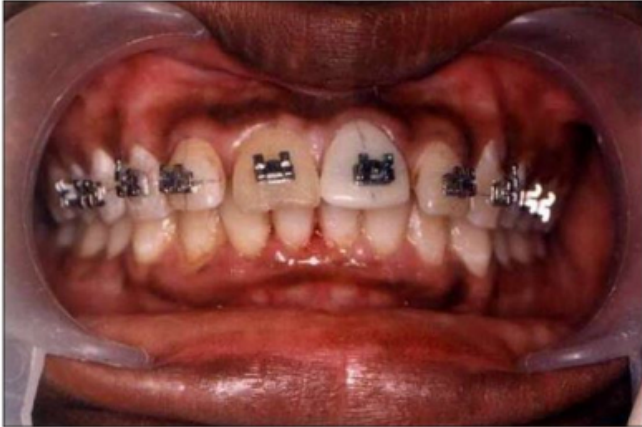RESULTS

The patients were observed over a six months period for any bracket failure at each thrice weekly appointment. The number of bond failures in each group were recorded and subjected to statistical analysis and tabulated as below

(Table 1).

Figure 11

Photograph showing after completion of direct and indirect bonding



When the samples were subjected to student's 't' – test the groups were found to be statistically insignificant.

DISCUSSION

At the near completion of treatment all teeth need to be brought to the final correct functional position to achieve a successful treatment of malocclusion. For this to be achieved a perfect alignment of the marginal ridges, contact points, and roots of the teeth, is necessary. Factors such as error in bracket placement and variation in tooth structure make it difficult to achieve there goals accurately with the pre adjusted edgewise appliance.

These factors can be best achieved by means of the indirect bonding technique. This was proved in a study by Nasib Balut et al way back in 1992 who had demonstrated laser angular and linear discrepancy in the placement of brackets by the indirect bonding technique(1).

In this study of indirect bonding technique used was the one advocated by Royce G.Thomas (1979) owing to its simplicity in the tray construction and transfer (2). All though he had advocated the use of chemically cured adhesive, we have substituted it with the light cure adhesive. Some of the steps in this procedure were modified which included the absence of indirect bonding agent which was applied on to the etched enamel and to the bracket base, instead a small amount of light cure adhesive was placed. This reduces the inventory of the materials that are required

and at the same time did not affect the clinical bond strength as demonstrated by the fever bracket debonding observed by this technique.

In the present study there was no statistically significant difference in the bracket failure recorded within the 6 months of study and results obtained are similar to that of Micheal Aguirre et al (1982), of the 100 brackets bonded in each group 14% failure was observed in the brackets bonded with the direct bonding technique and a 10% failure with the indirect bonding (3).

The results of our study were in accordance to the studies by Jim Milne et al, Aguirre et al, etc. In that no significant differences were found as regards bond failures between the direct and indirect bonding techniques (3, 4).

When the amount of time required to complete the two techniques were taken into consideration the time needed to complete the indirect bonding procedure including the laboratory time, was larger than the time needed to complete the direct bonding procedure. When only the clinical time to complete the procedure is taken into consideration the indirect technique is definitely of a lesser duration than the direct technique, this is also is accordance with the study of Aguirre et al.(3).

CONCLUSION

Although it is difficult to draw any definitive conclusion in a study of this nature, we can safely say that the indirect bonding technique is definitely a better option in a busy practice, and could provide efficient bracket placement in significantly less chair side time which overweighs the cost involved in the laboratory procedure.

References

1. Nasib Balut, Lewis Klapper, James Sandrik, Douglas Bowman. Variations in bracket placement in pre adjusted orthodontic appliance – American journal of orthodontics & dentofacial orthopedics 1992 July.
2. Royce G. Thomas. Indirect bonding – simplicity in action- journal of clinical orthodontics 1979 February (93-106).
3. Michael Aguirre, Gregory J.King, Joseph M.Waldron. Assessment of bracket placement and bond strength when comparing direct bonding to indirect bonding techniques - American journal of orthodontics & dentofacial orthopedics 1982 October.
4. Milne, Andreasen, Jakobsen. Bond strength comparison – A simplified indirect technique versus direct placement of brackets - American journal of orthodontics & dentofacial orthopedics 1989 July.

Author Information

P. Premanand, MDS, DHM, Associate Professor & Head

Department of Dentistry, Chennai Medical college Hospital & Research centre (SRM Group)

Trichy, Tamilnadu, India

drpremotho@gmail.com

A. Jegadesh Shankar, MDS, Assistant Professor

Department of Dentistry, Chennai Medical college Hospital & Research centre (SRM Group)

Trichy, Tamilnadu, India