

Sub-Facetal C2 Body Screw In Posterior Fixation (Goel-Harm's Technique) Of The Atlanto-Axial Joint Avoiding The Vertebral Artery

S V Patkar

Citation

S V Patkar. *Sub-Facetal C2 Body Screw In Posterior Fixation (Goel-Harm's Technique) Of The Atlanto-Axial Joint Avoiding The Vertebral Artery*. The Internet Journal of Neurosurgery. 2014 Volume 10 Number 1.

Abstract

Since the first description by Goel 1994 and later by Harm's 2001, the posterior C1 lateral mass and C2 pars/ pedicle, poly axial screw rod fixation has evolved to become the treatment of choice in addressing instability of the atlanto-axial joint requiring stabilization. The anatomy of the C2 pedicle and the course of the vertebral artery before it enters the C2 foramen transversarium is variable resulting in an inability to pass the C2 pedicle/pars screw in significant number of cases. There is a definite risk of injury to the vertebral artery. Thin slice CT scans (computerized axial tomography), CT angiography and intraoperative neuronavigation have been used to reduce the chances of arterial trauma.

A new trajectory, just below the atlanto-axial joint directed medially and downwards into the C2 body offers similar if not better fixation when used along with the C1 lateral mass screw without any chance of injury to the vertebral artery.

MATERIAL & METHODS

The technique has been used in reducible atlanto-axial instability due to trauma, rheumatoid arthritis and infection (tuberculosis). Since Feb 2007 till Dec 2013, 54 patients (108 screws) have been operated by this technique. Dynamic lateral X-Rays of cranio-vertebral junction (CVJ), 3 D CT scan of the cranio-vertebral region along with dynamic study and the SPGR (spoiled gradient recovery) sequence of the MRI (Magnetic resonance imaging) to study the course of the vertebral artery. The axial CT images of the C1 lateral mass and C2 facet and body thickness were also used to study the length of the screws to be used for fixation.

TECHNIQUE

Operative Technique:

Following general anesthesia and careful fibre-optic endoscope assisted intubation, all patients were positioned prone on a neurosurgical operation table (Mizhuo-Japan) with the head in the "U" rest taking care to protect pressure points and the eyes. Skull Tongs (Gardner- Wells) were applied for intra-operative manipulation of the atlanto-axial joints and reduction of the dislocation before final tightening of the screw rod assembly.

Following the usual midline incision and sub-periosteal separation of the paraspinal muscles the craniovertebral region and upper cervical spine were exposed. The C2 (axis) lamina was traced to reach atlanto-axial joint and the C2 root ganglion was sharply divided 1cm from lateral edge of dura. Bleeding from the venous plexus was controlled with bipolar coagulation and using surgical (Johnson inc USA).

The atlanto-axial joint surface cartilages on the opposing surfaces were shaved off using a microdrill and mini (2mm) curettes till there was some bleeding from the opposing joint surfaces. Cortico-cancellous bone harvested from the spinous processes (C3/C4) along with artificial bone substitute (Surgiwear India) was packed into the joint. Procedure was repeated on other side also.

1: The C1 lateral mass below the posterior arch of the atlas was cleared of all soft tissues and the centre of this exposed surface was drilled with a 3mm microdrill for 10mm - 12mm depth in a upward (10 degrees approx.) and medial (20 degrees approx.) direction. This was done as the lateral masses of the atlas are oriented in a medio-lateral plane. A 3.5 mm -4mm diameter poly axial screw with a length of 18mm - 24mm (selection calculated from the pre-operative CT scan measurement) were passed usually without tapping.

Sub-Facetal C2 Body Screw In Posterior Fixation (Goel-Harm's Technique) Of The Atlanto-Axial Joint Avoiding The Vertebral Artery

2 : New Entry Point for C2 Screw (Fig 1 &2)

The mid-point of the upper surface of the C2 (axis) superior facet was identified , and , 3mm-4mm below the mid-point an entry point for the axis screw was made using a 3mm microdrill in incremental manner in a downward (10 degrees approx.) and medially (20 degrees approx.) for about 10m to 15 mm in 2mm-3mm incremental manner . Poly axial screws of the selected length were passed usually without tapping, which ensured secure hold for the screw, usually at the first attempt. The screw length varied from 18mm to 24mm depending upon the pre-operative CT scan measurements.

4 mm titanium rods of appropriate length were secured into the poly screw heads, with the head held in extension using the skull tongs to ensure reduction of the atlanto-axial dislocation.

All patients underwent post-operative dynamic X rays (Fig- 3) and CTscans (Fig- 4)of the CVJ before discharge from the hospital on the 5th day. Post-operative rigid collar which held the CVJ in neutral was used in all cases for 6 weeks.

RESULTS AND COMPLICATIONS

No case of intra - operative vertebral artery injury. No patient required per operative blood transfusion.

Figure 1

Pedicle and pars entry points and trajectory.

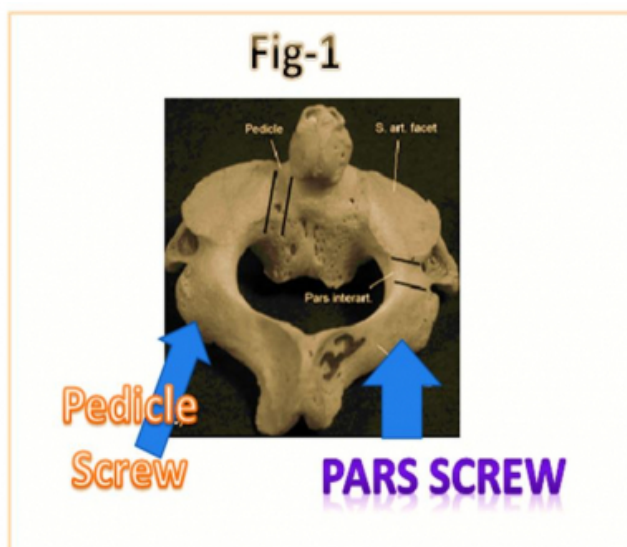


Figure 2

New Sub-facetal Axis screw entry point and trajectory.

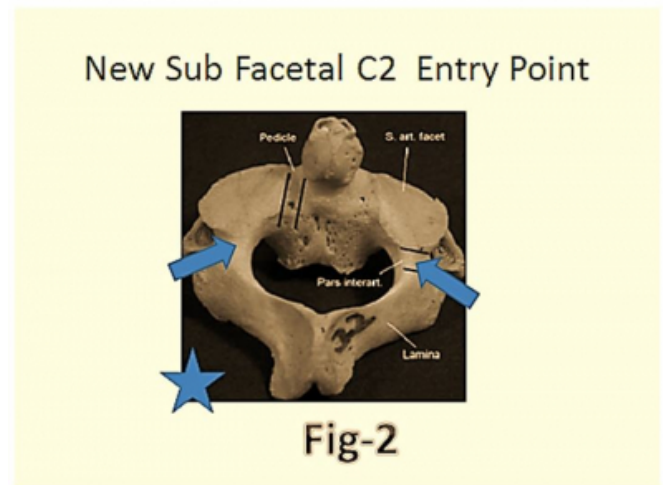


Figure 3

Post-operative X-ray showing axis screw bypassing the pars/pedicle

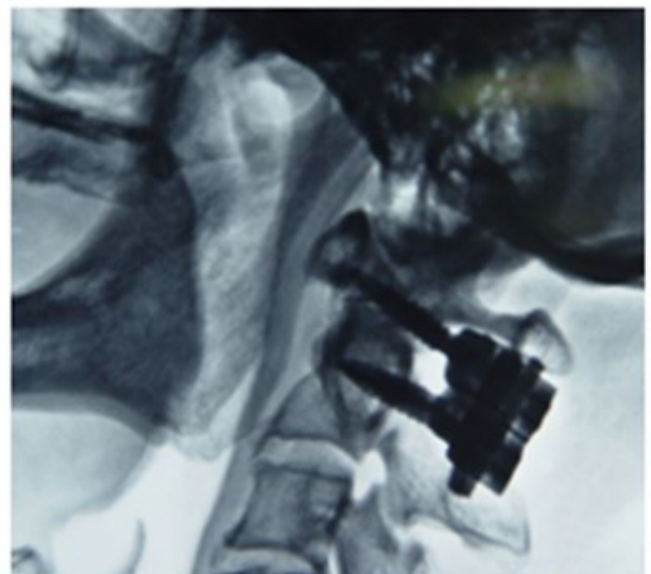
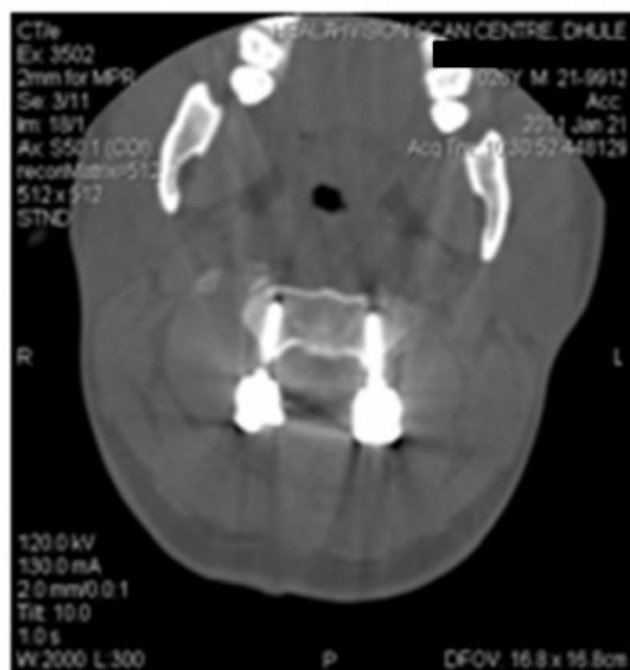

Figure 4

Post-operative CT scan axial image showing C2 screw trajectory



DISCUSSION

Rotation is the predominant movement at the atlanto-axial joint (1). Successful fixation of the atlantoaxial joint should stop rotation and cause bony fusion across the joint .Posterior wiring and clamps failed to restrict rotation and thus had unsuccessful results (2). Also, bone grafting in the posterior wiring / clamp techniques was not along the line of weight transmission which passes through the joint.

Magerls (3)description of posterior transarticular C2-C1 screws resulted in a paradigm shift in atlanto-axial fixation techniques and produced almost 100% rigid fixation along with fusion . However the variable anatomy of the C2 pedicle and the course of the vertebral artery resulted in significant morbidity and the operation failed to become universally acceptable (4 & 5).

Goel's (6)description and later Harm's (7)technique considerably reduced the chances of vertebral artery injury . Pre-operative thin slice CT scans and intraoperative use of neuronavigation (has been recommended to avoid injury to the vertebral artery (8 & 9).

In the axis vertebra , pars is the bone between the upper and lower facet and , the pedicle is the bone which connects the posterior elements (facets, laminae and spinous process)to

the body of the vertebra .

The entry for the pars screw is inferio-medial to that of the pedicle screw and the risk of injury to the vertebral artery exists in both the trajectories and depends upon the course of the artery and the thickness of the C2 pedicle. Technically, the pars screw carries a higher risk of vertebral artery injury as compared to the pedicle screw.

An alternative trajectory 2mm-3mm below the mid-point of the C2 facet surface , directed , downwards and medially into the C2 body , bypasses the pedicle and vertebral artery altogether , and still offers adequate bone stock for rigid fixation of the C2 vertebra . Also divergent screws (Bridge Vs Tension Band construct) as in the present technique offer a greater resistance to pull out forces as compared to the Goel/Harm's method with parallel C1 lateral mass and C2 pars/pedicle screws (10).

This new technique avoids the vertebral artery and does not require expensive technology for passing the C2 screw.

References

- 1 Milan KS, Steffen T, Beckman L, Tsantrizos A, Reindl R, Aebi M (2005) Atlantoaxial fusion using anterior transarticular screw fixation of C1–C2: Technical innovation and biomechanical study. *Eur Spine J* 14:512–518
- 2 Praveen V Mummaneni1, Regis W Haid2 Atlantoaxial fixation: Overview of all techniques
a. REVIEW ARTICLE *Neurology India* 2005 | 53 | : 4 | 408-415
- 3 Magerl F, Seemann PS: Stable posterior fusion of the atlas and axis by transarticular screw fixation. In *Cervical spine I*. Volume 1. Edited by Kehr P, Weidner A. New York: Springer; 1987:322-327
- 4 Madawi AA, Solanki G, Casey ATH, Crockard HA (1997) Variation of the groove in the Axis vertebra for the vertebral artery—implications for instrumentation. *JBJS* 79-B:820–823
- 5 Lall R, Patel NJ, Resnick DK : A review of complications associated with craniocervical fusion surgery. *Neurosurgery*. 2010 Nov;67(5):1396-402; discussion 1402-3.
- 6 Goel A, Laheri V (1994) Plate and screw fixation for atlanto-axial subluxation. *Acta Neurochir* 129:47–53
- 7 .Harms J, Melcher RP (2001) Posterior C1–C2 fusion with polyaxial screw and rod fixation. *Spine* 26:2467–2471
- 8 Yamazaki M et al . Anomalous vertebral arteries in the extra- and intraosseous regions of the craniovertebral junction visualized by 3-dimensional computed tomographic angiography: analysis of 100 consecutive surgical cases and review of the literature. *Spine (Phila Pa 1976)* 2012 Oct.15; 37(22): E1389-97
- 9 Dwarkanath S et al Transarticular screw fixation using neuronavigation: Technique, *Indian J Orthop*. 2007 Oct-Dec; 41(4); 318-321
- 10 Giannitsios D, Richards C, Ouellet J Comparison of Pedicle Screw Spinal Fixation for Fractures: Bridge vs.Tension Band Construct , *European Cells and Materials* Vol. 10 Suppl. 3, 2005 (page 55)

Author Information

Sushil Vasant Patkar, M.Ch (Neurosurgery)

Bhartividyapeeth Medical College & Hospital