

# Effect Of Subconjunctival Bevacizumab (Avastin) For Resistant Neovascular Corneal Ulceration In An Egyptian Infant

M Sayed Saif, A Sayed Saif, P Sayed Saif

## Citation

M Sayed Saif, A Sayed Saif, P Sayed Saif. *Effect Of Subconjunctival Bevacizumab (Avastin) For Resistant Neovascular Corneal Ulceration In An Egyptian Infant*. The Internet Journal of Ophthalmology and Visual Science. 2014 Volume 11 Number 1.

## Abstract

This retrospective interventional case study include one eye of a male infant with resistant progressive neovascularized corneal ulcer not responding to medical treatment. Patient received a subconjunctival injection of 1.25 mg (0.05 ml) bevacizumab under the feeding vascularized vessels. Morphologic changes were investigated by corneal photography. Corneal NV was dramatically regressed a 2 week after injection with complete healing of the resistant ulcer. No infection or inflammation was observed. No relapse was seen within the follow-up of 36 months. Subconjunctival injection of bevacizumab may offer an additional strategy for the treatment of resistant vascularized corneal ulcer

## INTRODUCTION

During corneal NV, an up-regulation of angiogenic factors must be present, most likely in association with a down-regulation of anti-angiogenic molecules<sup>1</sup>. Vascular endothelial growth factor (VEGF) is a secreted growth factor peptide generated by alternative splicing in five isoforms (VEGF115, VEGF121, VEGF 165, VEGF 189, and VEGF 206) [4]. It plays a major angiogenic role in several ocular pathologies characterized by NV [6]. It was recently shown that VEGF was upregulated in inflamed and vascularized corneas in humans and animal models [2, 6]. Interestingly, requirement of VEGF in corneal NV was shown by the inhibition of NV after stromal implantation of an anti-VEGF blocking antibody in a rat model [2]. VEGF promotes several steps of angiogenesis, including proteolytic activities, endothelial cell proliferation, migration, and capillary tube formation [4].

Bevacizumab, a recombinant humanized monoclonal antibody developed against VEGF, binds to soluble VEGF, preventing receptor binding and inhibiting endothelial cell proliferation and vessel formation [7].

## CASE REPORT

This retrospective study adhered to the tenets of the Declaration of Helsinki and institutional review board

approval was obtained to review the patient data. Patient's father opted to have the injection after receiving detailed information about other therapeutic options and signed informed consent. The standard protocol for subconjunctival injections includes general anesthesia, disinfection, and lid speculum. Approximately 1.25 mg (0.05 ml) of commercially available bevacizumab solution (Avastin; Genentech, South San Francisco, CA) was injected into the subconjunctival space close to the corneal limbus near the corneal NV.

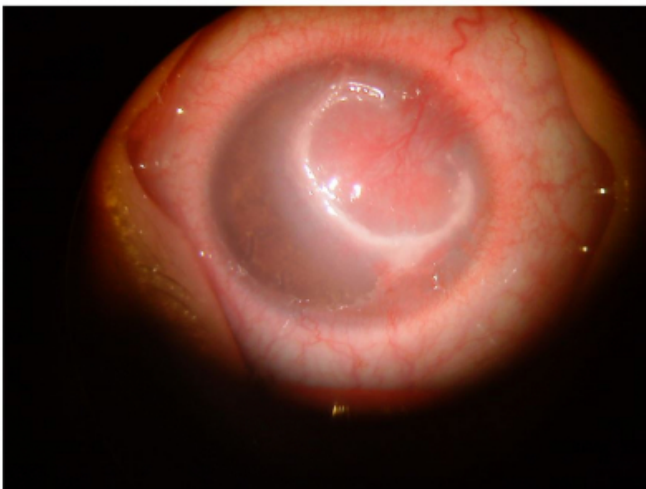
A 1.5 year -old male infant presented with ocular pain, photophobia, and blepharospasm in his right eye. Examination showed oval small corneal ulceration with neovascularization between 7 and 8 o'clock position about 1 mm in diameter, 2 mm from the limbus and severe conjunctival hyperemia. He had no history of trauma, ocular surgery, or disease. He had been on topical artificial tears and antibiotic drops and ointment therapy for about 4 weeks. The patient was examined by a pediatrician for any associated disease or malnutrition and found free. Complete examination of anterior and posterior segments of both eyes revealed no other ocular pathology. A change of antibiotics drops and ointment was changed several times with the addition of systemic antibiotics, and multivitamins. The case worsened and the ulcer enlarged and more vascularized. (Fig

1). Topical antiviral ointments was added and examined after one week. Still worsen. After discussing the situation with his parents about the possibility of Avastin injection and after signing the informed consent (figure 2). A single dose of 1.25 mg (0.05 ml) of bevacizumab was injected into the subconjunctival area 1–2 mm behind the limbus near the corneal NV.

The patient continue on the antibiotic eye drop and artificial tear preparation after subconjunctival drug administration. He was more comfortable after the injection in the follow up visits. The corneal vascularization was rapidly resolved within one week (Fig. 3). After 2 weeks complete healing of the ulcer with no neovascularization( fig. 4) . After 2 month examination reveled ulcer healed with superficial corneal opacity that keep persistent all over the fellow up period of 36 month. No relapse was seen in the follow-up period . No signs and symptoms were detected, and no ocular inflammation and complications were observed throughout the follow-up.

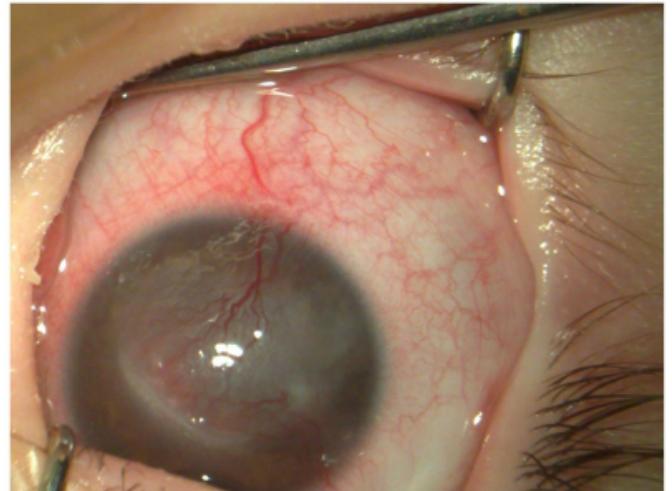
**Figure 1**

Ulcer on medical treatment with vascularization and still progressive ( 2 months on medical treatment)



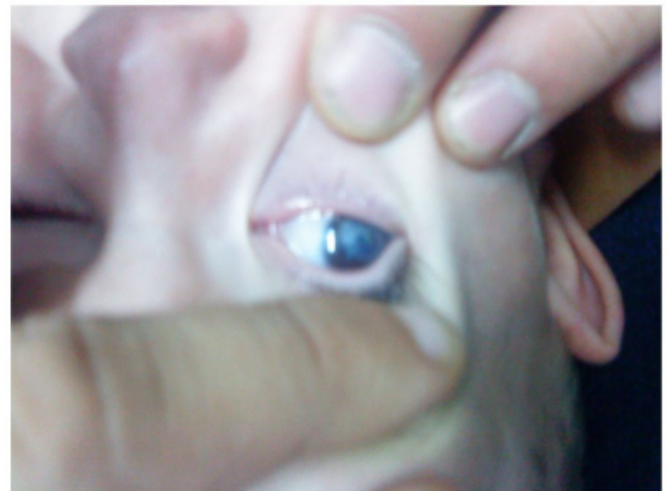
**Figure 2**

on the day of injection of Bevacizumab



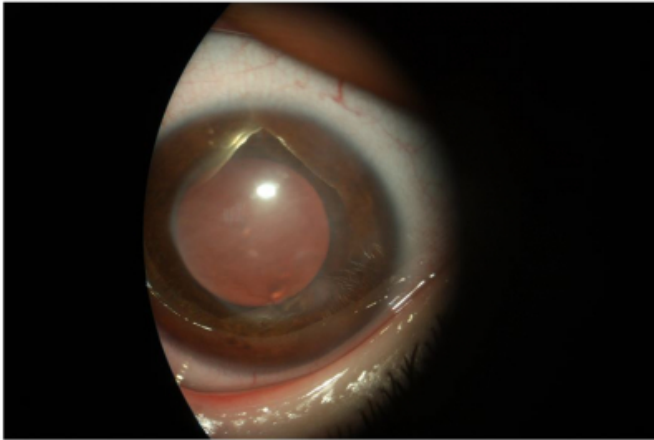
**Figure 3**

one week after injection with no vascularization



**Figure 4**

complete healing with no vascularization and minimal superficial corneal nebula



## DISCUSSION

Recent studies using intravitreal injections of bevacizumab for neovascular age-related macular degeneration showed promising results [ 3]. Iliev et al. [5] also confirmed the regression of iris and iridocorneal angle NV after intravitreal bevacizumab injection and they speculated that it may provide an additional strategy for the treatment of neovascular glaucoma.

Only a single subconjunctival application of the drug caused a dramatic reduction of corneal NV within the first week, with no evidence of inflammation . In the case, all the vessels invading the cornea were resolved completely within one week after injection and the corneal ulcer healed over the following 2 weeks. Briefly, a dramatic regression of corneal NV in eye was confirmed by within just a week after

injection and no relapse was seen within the follow-up period of 36 months.

We used 1.25 mg (0.05 ml) of bevacizumab solution for corneal NV in our patient.

The results suggested that this dosage may be enough for corneal NV and could be repeated if necessary. Although some portion of bevacizumab might have been passed into the systemic circulation via subconjunctival vessels, a sufficient amount seemed to be maintained to lessen the corneal NV.

## References

1. Mesut Erdurmus & Yuksel Totan: Subconjunctival bevacizumab for corneal neovascularization; Graefe's Archive for Clinical and Experimental Ophthalmology Volume 245, Number 10, 1577-1579,
2. Amano S, Rohan R, Kuroki M, Tolentino M, Adamis AP (1998) Requirement for vascular endothelial growth factor in wound- and inflammation-related corneal neovascularization. Invest Ophthalmol Vis Sci 39:18–22
3. Bashshur ZF, Bazarbachi A, Schakal A, Haddad ZA, El Haibi CP, Nouredin BN (2006) Intravitreal bevacizumab for the management of choroidal neovascularization in age-related macular degeneration. Am J Ophthalmol 142:1–9
4. Chang J H, Gabion EE, Kato T, Azar DT (2001) Corneal neovascularization. Curr Opin Ophthalmol 12:242–249
5. Iliev ME, Domig D, Wolf-Schnurrbusch U, Wolf S, Sarra GM (2006) Intravitreal bevacizumab (Avastin) in the treatment of neovascular glaucoma. Am J Ophthalmol 142:1054–1056
6. Philipp W, Speicher L, Humpel C (2000) Expression of vascular endothelial growth factor and its receptors in inflamed and vascularized human corneas. Invest Ophthalmol Vis Sci 41:2514– 2522
7. Wang Y, Fei D, Vanderlaan M, Song A (2004) Biological activity of bevacizumab, a humanized anti-VEGF antibody in vitro. Angiogenesis 7:335–345

**Author Information**

**Mohamed Yasser Sayed Saif**

Assistant Prof of Ophthalmology Beni Suef University  
ysaif@sayedsaif.com

**Ahmed Tamer Sayed Saif**

, Lecturer of Ophthalmology Fayoum University

**Passant Sayed Saif**

Lecturer of Ophthalmology Misr University for Science and Technology