

Recurrent Splenic Pseudocyst

K Vagholkar, M Bendre, N Rane

Citation

K Vagholkar, M Bendre, N Rane. *Recurrent Splenic Pseudocyst*. The Internet Journal of Surgery. 2014 Volume 31 Number 1.

Abstract

Background: Splenic cysts are rare. The etiology and natural history is variable leading to high morbidity. Understanding the etiopathogenesis and possible therapeutic options is necessary for charting the optimal surgical algorithm.

Case report: A case of a recurrent pseudocyst of the spleen treated by open splenectomy is presented.

Discussion: A review of the etiopathogenesis, clinical presentation, diagnosis and therapeutic options is discussed.

Conclusion: Open splenectomy is the procedure of choice for recurrent and complicated splenic pseudocysts.

INTRODUCTION

Splenic cysts are quite uncommon. They can have a varied etiology and are broadly classified into true cysts which have their own epithelial lining and pseudocysts which are devoid of their own epithelial lining. Since the clinical presentation is not specific in the majority of cases, diagnosis is based predominantly on imaging. Therapeutic options depend largely on the etiology of the cyst. Hence understanding the etiology of splenic cysts is pivotal in choosing the best surgical option for treatment of the cyst in order to prevent recurrence. A case of recurrent pseudocyst of the spleen is presented along with a review of literature.

CASE REPORT

A 22-year-old lady presented with symptoms of dull aching pain and fullness in the left hypochondrium for one year. She gave a history of having undergone a major surgical procedure for a post traumatic lesion at a district hospital nine years back. Review of the records of previous surgery revealed that a marsupialization procedure was done for a splenic pseudocyst. During the course of the procedure approximately 900cc of amber colored fluid was aspirated from the cyst prior to marsupialization. The record of the previous histopathology report revealed a fibrous tissue wall devoid of epithelium. The patient was apparently asymptomatic since then. For the last one year the patient has been complaining of vague upper abdominal symptoms such as pain off and on, early satiety and a persistent feeling of fullness maximally experienced in the left side of the

upper abdomen. She did not give any history of alteration in her bowel or bladder habits.

General examination revealed normal vital parameters. There was no evidence of pallor or jaundice. A scar of previous surgery was seen extending from the left subcostal region and crossing the midline. Physical examination of the abdomen revealed an extensive mass predominantly occupying the left hypochondrium but extending to the epigastrium and umbilical region. The mass was moving with respiration. Percussion over the mass revealed a dull note. There were no other masses in the rest of the abdomen nor was there any clinical evidence of free fluid in the flanks.

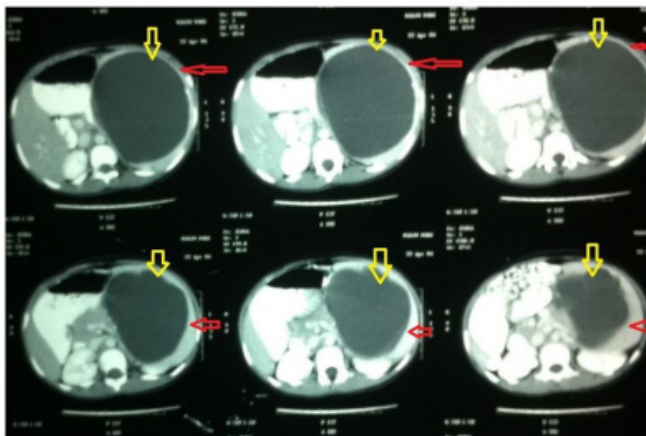
Hematological investigations did not reveal any abnormality. Ultrasound examination revealed the cystic nature of the mass. However the exact extent could not be delineated by sonography. A double-contrast CT scan revealed a large cystic lesion involving the entire spleen extending up to the upper pole of the left kidney. There was a very narrow rim of splenic tissue around the pseudocyst. (Figure 1) The stomach was pushed to the right. The findings were in conformity with a splenic pseudocyst.

As it was a recurrent pseudocyst, anticipating extensive adhesions to the surrounding structures, a decision to proceed with an exploratory laparotomy was made. Through a left paramedian incision the spleen was accessed. The spleen was massively enlarged with just a thin rim of splenic tissue enclosing the fluid collection. There were extensive

adhesions between the spleen and the inferior surface of the left hemidiaphragm as well as to the splenic flexure of the colon, upper pole of the left kidney and to the greater curvature of the stomach and the tail of the pancreas. The adhesions of the fibrous capsule were extremely dense and had to be divided with great care. The splenic pedicle was then accessed. The vessels were identified and ligated individually taking utmost care to avoid damage to the tail of the pancreas. A complete splenectomy was accomplished. The pseudocyst contained approximately 1 liter of amber colored fluid. The post-operative recovery was uneventful. All necessary vaccinations were given postoperatively. Histopathological examination of the wall of the pseudocyst revealed fibro collagenous tissue only.

Figure 1

CT scan showing the recurrent splenic pseudocyst. (Yellow markers point towards the cyst, red markers point towards the thin rim of splenic tissue)



DISCUSSION

Splenic cysts are a rare entity as compared to cystic lesions in other solid organs such as the liver, pancreas and kidney. [1, 2] They are classified into primary or true cysts which have an epithelial lining of their own. These can further be sub-classified into parasitic and non-parasitic. [2] Hydatid disease is the commonest cause of parasitic splenic cysts. [3] Non-parasitic cysts are either congenital or neoplastic in origin. Secondary splenic cysts are usually post-traumatic in origin. The etiopathogenesis determines the choice of surgical option for treatment. Pseudocysts are less common as compared to other cystic lesions of the spleen. As the incidence of pseudocysts of the spleen is low, literature on the topic is fragmented and mostly in the form of case reports. There are no case series or randomized trials done for determining the best surgical option for pseudocysts of the spleen.

The pseudocysts vary in size ranging from 1 to 16cm. The splenic tissue is eventually reduced to a thin rim surrounding the fluid collection. If untreated, they continue to grow. The contained fluid is usually amber colored as they are usually post-traumatic in etiology. Occasionally the cyst may contain necrotic debris. The wall comprises dense fibrocollagenous tissue. [1] Extensive adhesions develop with the adjacent structures leading to a variety of symptoms. Hemorrhage and rupture are complications which can develop in large cysts. Calcification of the wall is a usual sequel in longstanding cysts. Splenic pseudocysts are at times associated with splenoptosis and vertebral anomalies. [4]

Splenic pseudocysts may remain asymptomatic in the majority of cases. Symptoms develop as the lesion starts assuming a bigger size thereby causing pressure and later adhesions to the adjacent organs. A feeling of heaviness, fullness and a typical splenic mass in the left side of the upper abdomen are usually the commonest symptoms. Early satiety is usually due to pressure on the stomach. Alteration of bowel habits may occur if there is pressure on the splenic flexure of the colon. The left hemidiaphragm may be affected by pressure or adhesions leading to respiratory symptoms. Rupture of the cyst may lead to a life-threatening surgical emergency.

Routine blood investigations usually do not reveal any abnormality. Plain X-ray of the abdomen will reveal a calcified rim in a few cases. Ultrasonography will help in confirming the splenic origin of the lesion and the fluid contents of the cyst. However, a double-contrast CT scan of the abdomen will furnish exact details which will help in deciding the surgical strategy. [2,3] It will show the exact size of the cyst, the nature of contents, whether fluid or necrotic debris, the extent of involvement of the splenic parenchyma and adhesions of the spleen to the adjacent organs. Other supportive investigations like immunological tests and tumor markers are negative in pseudocysts.

Management strategies have to be developed based on the individual merits of the case. The salient principles underlying management of splenic pseudocysts are control of symptoms by controlling size, prevention of fatal complications and prevention of recurrence. Cysts smaller than 5cm are usually asymptomatic and managed by expectant treatment. But when the size exceeds 5cm the cysts become symptomatic requiring surgical intervention.

Percutaneous drainage is an option for treating smaller cysts.

However, the recurrence rate with this method is very high and therefore this cannot be advocated as a standard therapy. [5]

Marsupialization is a method in which a part of the cyst wall is removed by cautery dissection. The chances of bleeding are reduced by the use of the cautery. However, the recurrence rate still is quite high. [6] In the case presented, the pseudocyst was marsupialized initially. However, the method failed and the lesion recurred. Laparoscopic marsupialization is also a viable option. The cyst wall can be covered with Surgicel™ followed by omentopexy. [7]

Fenestration techniques like partial cystectomy, unroofing or deroofting are also associated with high recurrence rate. [8]

Partial splenectomy either open or laparoscopic is an option preferred by some. This maintains the immunological function of the spleen thereby preventing septic complications. The option is particularly applicable to the pediatric age group of patients. [9] However, in situations with extensive adhesions the procedure may be technically challenging adding to the morbidity and even mortality by way of hemorrhagic complications.

The traditional open splenectomy continues to be the mainstay of treatment for splenic pseudocysts. [10, 11] This allows dissection of tissue planes under direct vision with good control over hemostasis. The spleen can be removed completely without rupturing the cyst. This surgical option provides a permanent cure to the disease. Laparoscopy-assisted splenectomy can be performed if adequate technical expertise is available. [11]

Recurrences of pseudocysts have been reported with laparoscopic procedures. A recurrence rate as high as 85% has been reported. [1, 2, 11]

CONCLUSION

Contrast-enhanced CT scan of the abdomen provides elaborate details pertaining to the cyst, which is pivotal in

deciding the approach to the cyst.

Partial splenectomy either by open or laparoscopic approach is best suited for pediatric patients.

Traditional open splenectomy is the mainstay of treatment for large as well as for recurrent pseudocysts of the spleen.

ACKNOWLEDGEMENTS:

We would like to thank Dr. Shirish Patil, Dean of Dr. D. Y. Patil Medical College, Navi Mumbai, India for allowing us to publish this case report.

We would also like to thank Parth K. Vagholkar for his help in typesetting the manuscripts.

References

1. Walz MK, Metz KA, Eigler FW: Splenic cysts. Their morphology, diagnosis and therapy. *Dtsch Med Wochenschr*; 1991; 116: 1377-83.
2. Grube-Pagola P, Cadena-Castillo As, Ortiz-Navarrete SG, Ruiz-Juarez I, Remes-Troche JM: Splenic pseudocyst: a rare condition. *Rev Gastroenterol Mex*; 2010; 75: 84-8.
3. Vagholkar K, Nair S, Patel B, Dastoor K, Joglekar O, Nachane S, Rambia S: Hydatid disease of the spleen. *The Internet Journal of Surgery*; 2011; 27(1)
4. Noushif M, Mohandas K, Vasu TA, Rishikesan NK: Splenic pseudocyst: a rare association with splenoptosis and vertebral segmentation anomalies. *Singapore Med J*; 2011; 52: e141-2.
5. Thanos L, Mylona S, Ntai S, Pomoni M, Katakis N: Percutaneous treatment of true splenic cysts: report of two cases. *Abdom Imaging*; 2005; 30: 773-776.
6. Millar JS: Partial excision and drainage of post traumatic splenic cysts. *Br J Surg*; 1982; 69: 477-78.
7. McColl RJ, Hochman DJ, Sample C: Laparoscopic management of splenic cysts: marsupialization, cavity lining with surgicel and omentopexy to prevent recurrence. *Surg Laparosc Endosc Percutan Tech*; 2007; 17: 455-458.
8. Hansen MB, Moller AC: Splenic cysts. *Surg Laparosc Percutan Tech*; 2004; 14: 316-322.
9. Sagar PM, McMahon MJ: Partial splenectomy for splenic cysts. *Br J Surg*; 1998; 75: 488.
10. Rosin D, Brascesco O, Rosenthal RJ: Laparoscopic splenectomy: new techniques and indications. *Chirurg*; 2001; 72: 368-377.
11. Karfis EA, Roustanis E, Tsimoyiannis EC: Surgical management of nonparasitic splenic cysts. *JSLS*; 2009; 13: 2007-2012.

Author Information

Ketan Vagholkar, MS, DNB, MRCS, FACS. Professor

Department of Surgery Dr. D. Y. Patil Medical College

Navi Mumbai, India

kvagholkar@yahoo.com

Mahendra Bendre, MS Professor

Department of Surgery Dr. D. Y. Patil Medical College

Navi Mumbai, India

Nikhil Rane, DNB Assistant Professor.

Department of Surgery Dr. D. Y. Patil Medical College

Navi Mumbai, India