The Internet Journal of Infectious Diseases
Volume 13 Number 1

Multiple Abscess Of The Chest Wall: Rare Complication Of Pulmonary Tuberculosis

A A Mohamed, O Shareefi, K M Hussin, K M Al Atowi, I S Bahurrmoz

Citation

A A Mohamed, O Shareefi, K M Hussin, K M Al Atowi, I S Bahurrmoz. *Multiple Abscess Of The Chest Wall: Rare Complication Of Pulmonary Tuberculosis* . The Internet Journal of Infectious Diseases. 2014 Volume 13 Number 1.

Abstract

Tuberculosis abscesses of the chest wall, though uncommon are not infrequently encountered in countries endemic to the disease. Tuberculosis (TB) of the chest wall constitutes 1% to 5% of all cases of musculoskeletal TB (1-3) which Musculoskeletal TB accounts for 1-2% of all types of tuberculosis (3-6). Isolated chest wall abscess without bone involvement is even rarer and to our knowledge only few cases were reported in the literature. We report a case of chest wall abscess without bone involvement in a young immunocompetent patient.

INTRODUCTION

Tuberculosis (TB) of the chest wall constitutes 1% to 5% of all cases of musculoskeletal TB.The diagnosis must always be confirmed by positive culture or histological proof. Anti tubercular therapy (extended course) is the cornerstone of the treatment.

CASE REPORT

A 23 year old man presented to our surgical outpatient clinic with 3 week history swellings over the right chest wall. The swellings were painless, increasing gradually in size and associated with nocturnal fever, sweating and loss of weight (5 kilograms in two month). He had family history of tuberculosis as his elder brother was recently diagnosed as a case of pulmonary tuberculosis and he is under treatment. There was no history of breathlessness, hemoptysis or chest pain. On clinical examination he was afebrile, average built and well nourished with weight of 63 Kg, pulse rate 80/minute, blood pressure 110/80 mm of Hg. systemic examination were unremarkable apart from two right chest wall swellings. The smaller one is about 4x4cm located on the anterior chest wall below and lateral to the right nipple. The bigger one is about 8x6 cm located on the posterolateral aspect of the lower right chest wall. Both swelling were fluctuant with no evidence of acute inflammation. There was no axillary or cervical lymph adenopathy). The anterior chest wall swelling burst out and disappeared spontaneously after fine needle aspiration (Photograph1&2).

Photograph 1

Showing the site of the anterior chest wall swelling which burst out and disappeared after fine needle aspiration

Photograph 2

Showing the posterior chest wall swelling.

Blood test including full blood count, urea and electrolytes and liver function test were normal. His erythrocyte sedimentation rate was 51mm. at the end of first hour.

Needle aspiration of the anterior swelling drained thick yellowish slightly blood stained pus (Photograph3).The aspirate was negative for alcohol acid fast bacilli and gynogenic organism on culture. PCR test for tuberculosis was positive.

Monteux test was strongly positive.

Photograph 3

Showing the needle aspirate.

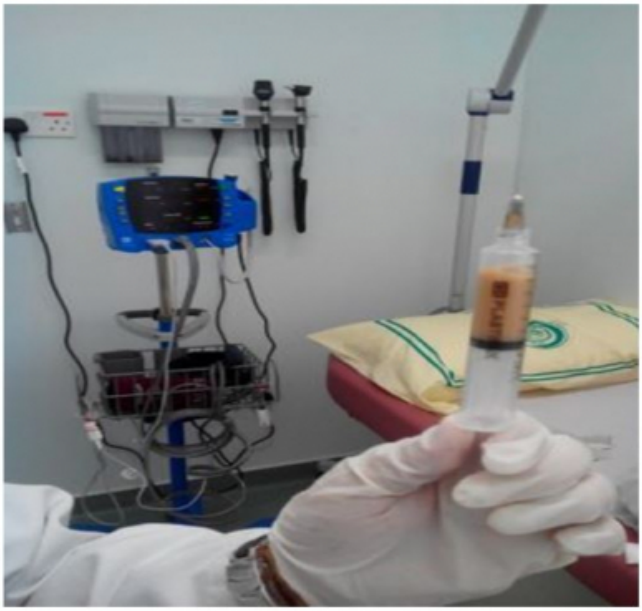

The chest x ray showed obliterated right costophrenic angles by homogeneous opacity with wavy inner margin and a lentiform lateral midpleural-based opacity together with Small atelectatic opacity in the lower right lung zone, otherwise both lung fields are clear with clear both hila. The left costophrenic angle is free with free both cardiophrenic angles. The thoracic cage is unremarkable (figure 1).

Figure 1

Showing obliterated right costophrenic angles by homogeneous opacity and right lower zone patchy opacities together with pleural opacities representing encysted pleural collection.

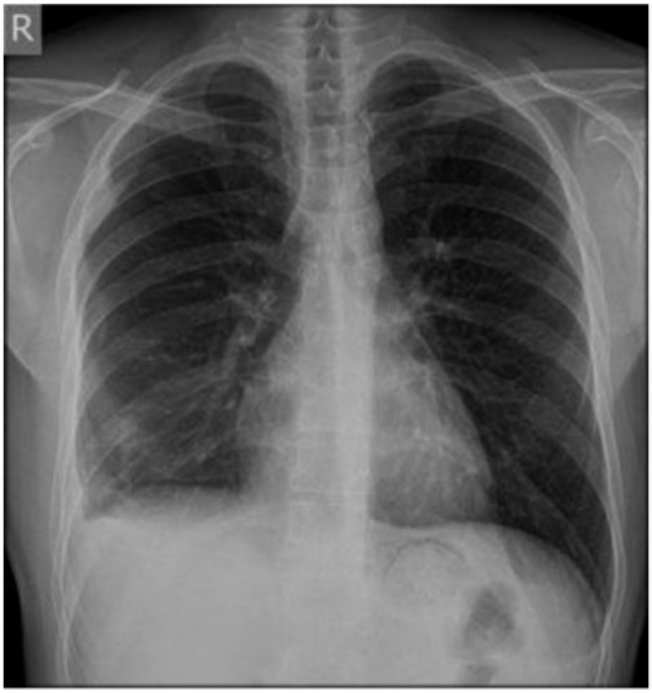

The CT scan showed evidence of multiloculated multiseptated two collections with enhancing walls, the largest one noted in the posterolateral aspect of the lower right chest wall and the smaller one is noted in the anterolateral aspect of the same side. The largest one revealed some extension into the ipsilateral right pleura that evidenced by multiple encysted right pleural collections, Segmental atelectasis of the lateral segment of right lower lung lobe, otherwise both lung fields were clear. There was no lymphadenopathy in the mediastinum and hila. All vertebrae and other visualized skeletons are normal in bone window setting. Findings highly suggestive of tuberculosis cold abscesses (figure 2-6).

Figure 2

Showing right pleural fluid collection.

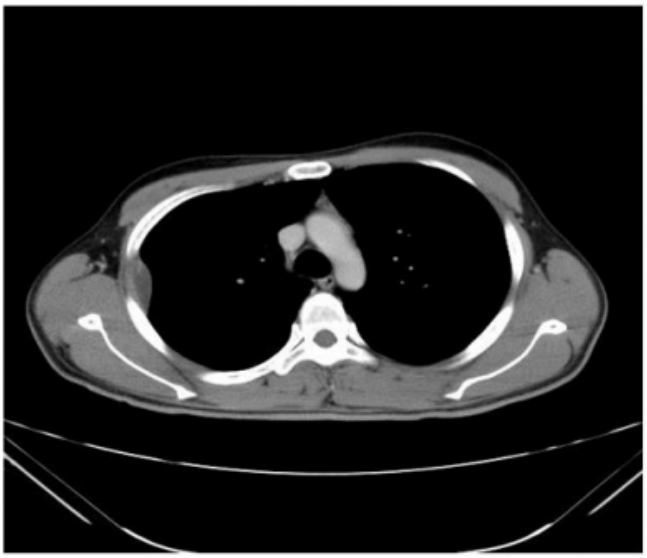

Figure 3

Showing the two chest wall collections communicating with the right pleural cavity posteriorly together with segmental atelectasis.

Figure 4

Showing the two collections with the communication of the posterior chest wall abscess with the pleural cavity.

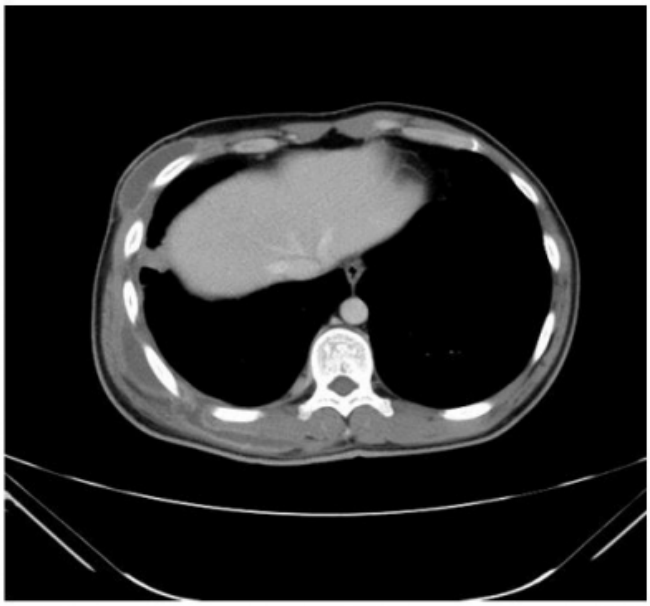

Figure 5

Showing the posterior chest wall abscess and right posterior pleural collection.

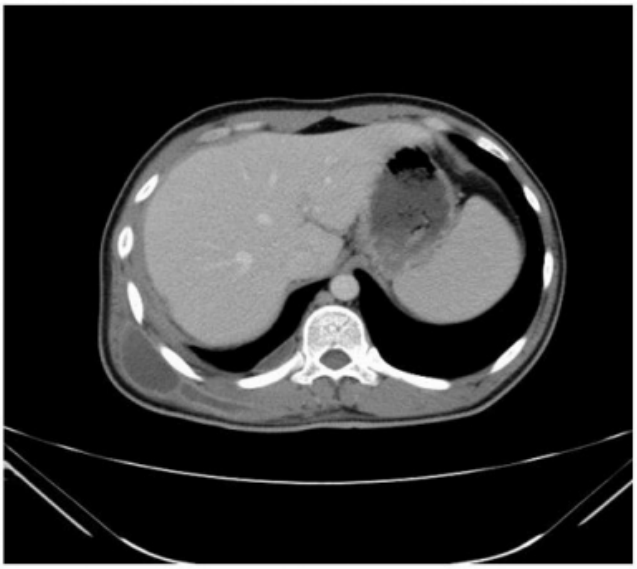

Figure 6
Showing no spine involvement.

In view of highly suggestive clinical presentation, positive PCR and tuberculin skin tests, and the radiographic findings compatible with TB, antituberclous treatment (combination of isoniazid, rifampicin, ethambutol and pyrazinamide) was started immediately after the appropriate microbiological and histological samples have been obtained.

DISCUSSION

Tuberculosis (TB) is still a major cause of significant morbidity and mortality despite universal availability of effective chemotherapy. The emergence of multidrug-resistant mycobacterium along with a worldwide increase in HIV infection has led to a recent surge in the number of patients with TB involves both pulmonary and extra pulmonary sites (7).Musculoskeletal tuberculosis accounts for 1-2% of all types of tuberculosis. Chest wall tuberculosis (CWTB) makes up 1 to 5% of all cases of musculoskeletal tuberculosis (3-6).

Three mechanisms have been suggested to explain the pathogenesis of CWTB: direct extension from underlying pleural or pulmonary parenchymal disease; hematogenous dissemination associated with the activation of a dormant tuberculosis focus; and direct extension from a lymphadenitis in the chest wall (1). Our case had chest wall lesions located adjacent to multiple loculated pleural collections suggesting the possibility of a direct extension from the pleural disease in the form of empyema necessitatis. Although this may explain lack of bone involvement, it is considered to be the least common cause of CWTB compared with the hematogenous and lymphatic routes (8).

As the condition is rare, and its clinical presentation may resemble gynogenic abscess or tumors (9, 10), diagnosis of Chest wall TB remains a challenge for clinicians and requires a high index of suspicion.

Chest wall TB is common in young adult and usually presents as progressively enlarging mass with or without destruction of the underlying bone or cartilage(2).

Laboratory investigations like complete blood picture (CBC), erythrocyte sedimentation rate (ESR), C - reactive protein (CRP) are usually unremarkable (11). The combination of indolent onset of symptoms, positive tuberculin skin test, and compatible radiographic findings, strongly suggests the diagnosis. However, the diagnosis must always be confirmed by positive culture or histological proof (12).

The optimal treatment strategy is controversial. There is general agreement that anti tubercular therapy (extended course) is the cornerstone of the treatment (6). TB treatment should be started immediately after the appropriate microbiological and histological samples have been obtained if the clinical suspicion is high. When there is ribs involvement ribs resection was advised by many authors (13, 14, and 15).

SUMMARY

Tuberculosis abscesses of the chest wall, though uncommon are not infrequently encountered in countries endemic to the disease. Chest wall tuberculosis makes up 1 to 5% of all cases of musculoskeletal tuberculosis. As the condition is rare, and its clinical presentation may resemble gynogenic abscess or tumors, diagnosis of Chest wall TB remains a challenge for clinicians and requires a high index of suspicion. Anti tubercular therapy (extended course) is the cornerstone of the treatment. Ribs resection is advisable in presence of ribs involvement.

References

1. Faure E, Souilamas R, Riquet M, et al. Cold abscess of the chest wall: a surgical entity? Ann Thorac Surg.1998; 66:1174–8.
2. Morris BS, Maheshwari M, Chalwa A. Chest wall tuberculosis: a review of CT appearances. Br J Radiol 2004;

77:449-57.
3. Hulnick DH, Naidich DP, McCauley DI. Pleural tuberculosis evaluated by computed tomography. Radiology; 1983; 149:759-65.
4. Gayler BW, Donner MW. Radiographic changes of the ribs. Am J Med Sci1967; 253:586-619
5. Mathlouthi A, Ben M'Rad S, Merai S, Friaa T, Mestiri I, Ben Miled K, et al. Tuberculosis of the thoracic wall: presentation of 4 personal cases and review of the literature. Rev Pneumol Clin .1998; 54:182-6.
6. K A SM, H S K, Cheluvaraj V, B B. A Young Lady with a Swelling over the Back:A Rare Case of Tuberculosis. Iran J Med Sci. 2011 Dec; 36(4):318-21.
7. De Backer et al.: Imaging of extraspinal musculoskeletal tuberculosis. Eur J Radiol; 2006; 57: 119-30."
8. Khalil A, Le Breton C, Tassart M, Korzec J, Bigot J, Carette M. Utility of CT scan for the diagnosis of chest wall tuberculosis. Eur Radiol. 1999; 9(8):1638-42.
9. Hsu HS, Wang LS, Wu YC, Fuhn HJ, Huang MH. Management of primary chest wall tuberculosis. Scand J Thorac Cardiovasc Surg. 1995; 29:119–123.
10. Paik HC, Chung KY, Kang JH, Maeng DH. Surgical treatment of tuberculous cold abscess of the chest wall. Yonsei Med J 2002; 43:309-14.
11. Ozol D, Köktener A, Uyar ME. Active pulmonary tuberculosis with vertebra and rib involvement: case report. South Med J 2006; 99: 171-3.
12. Papavramidis TS , Papadopoulos VN, Michalopoulos A, Paramythiotis D, Potsi S, Raptou G, Kalogera-Foutzila A, Harlaftis N. Anterior chest wall tuberculous abscess: a case report. J Med Case Rep. 2007 Nov 26; 1:152.
13. Cho KD, Cho DG, Jo MS, Ahn MI, Park CB. Current surgical therapy for patients with tuberculous abscess of the chest wall. Ann Thorac Surg. 2006 Apr; 1(4):1220-6.
14. Kim YT, Han KN, Kang CH, et al. Complete resection is mandatory for tubercular cold abscess of the chest wall. Ann Thorac Surg. 2008;85:273–7.
15. Sakuraba M, Sagara Y, Komatsu H. Surgical treatment of tuberculous abscess in the chest wall. Ann Thorac Surg. 2005 Mar;79(3):964-7.

Author Information

Abbas AR Mohamed, MBBS, FRCSI, FICS, FACS Consultant General and Laparoscopic Surgeon
Department Of Surgical Specialties
NGH –Madinah –KSA
abbas_ar@hotmail.com

Osama Shareefi, MBBS, FRCS(Glasgow) Consultant Plastic Surgeon, Head of the Department
Department Of Surgical Specialties
NGH –Madinah –KSA

Khaled M. A Hussin, M.B.Ch.B, Arab Board Assistant Consultant General Surgery
Department Of Surgical Specialties
NGH –Madinah –KSA

Kamal M.A. Al Atowi, MBBS, Arab board Associate Consultant Radiology Department of Radiology
NGH –Madinah –KSA

Idrees S. Bahurrmoz, MBBS SHO General Surgery
Department Of Surgical Specialties
NGH –Madinah –KSA