

# Gastric Outlet Obstruction Following Postoperative Adhesions From Open Cholecystectomy In A Nigerian Female: A Case Report And Review Of Literature

O Ngim, C Agbor, E Essien, D Eduwem, R Ndoma-Egba

## Citation

O Ngim, C Agbor, E Essien, D Eduwem, R Ndoma-Egba. *Gastric Outlet Obstruction Following Postoperative Adhesions From Open Cholecystectomy In A Nigerian Female: A Case Report And Review Of Literature*. The Internet Journal of Surgery. 2014 Volume 31 Number 2.

## Abstract

Gastric outlet obstruction (GOO) is caused by benign or malignant conditions. Benign causes are commoner in patients below 40 years of age while malignant causes are commoner above this age. Cicatrization and edema from chronic duodenal ulceration is the commonest benign cause in our environment (50-65%), while carcinoma of the head of pancreas is the commonest malignant cause. GOO from postoperative adhesions is uncommon. We present a 62-year-old female who was seen with features of GOO from postoperative adhesions following an open cholecystectomy in our facility. A barium meal and follow-through confirmed the clinical impression of GOO. She had adhesiolysis and a prophylactic gastrojejunostomy at laparotomy with satisfactory results. Laparoscopic cholecystectomy is the way to go as this may not have been attended by this complication.

**Conclusion:** This case has highlighted the rarity of GOO from adhesions following open cholecystectomy and the usefulness of barium meal and follow-through in areas where upper gastrointestinal endoscopy is unavailable to confirm the diagnosis. Laparoscopic cholecystectomy may have prevented this complication if it was possible in this center.

## INTRODUCTION

Gastric outlet obstruction, as the name implies, is an obstruction at the level of the pylorus. The causes could be benign or malignant and can occur at any age<sup>1,2,3</sup>. The causes of GOO may be intraluminal, intramural or extrinsic<sup>1-5</sup>. In children, congenital hypertrophic pyloric stenosis is relatively common with an incidence of 0.25 to 0.50 of all live births<sup>1,5</sup>. Edema and cicatrization from chronic peptic ulcer disease, gastric and duodenal tumors and carcinoma of the head of pancreas are common causes in adults<sup>1,3</sup>. Unusual causes in the literature such as post-operative adhesions, biloma and retained surgical sponge, amongst others, have been reported<sup>4,7</sup>.

These patients present mainly with repeated vomiting which is often post-prandial<sup>1-4</sup>. The vomitus is often non-bilious if the obstruction is complete or bilious if it is incomplete. There may be a history suggestive of a chronic peptic ulcer disease, marked weight loss with dehydration as well as inanition<sup>1,2</sup>. Visible peristalsis from left to right may be seen in the abdomen with a positive succussion splash. Jaundice may be present especially if it is due to carcinoma

of the head of pancreas as a result of common bile duct obstruction<sup>1,2</sup>. Metabolic alkalosis with paradoxical aciduria is a common feature<sup>1,2</sup>. A plain abdominal X-ray, barium meal and follow-through as well as gastroscopy are important diagnostic investigations. Gastroscopy has both diagnostic and therapeutic uses. Apart from demonstrating GOO, biopsy of lesions seen at gastroscopy can be taken for histology and a duodenal stent can be passed during the procedure for therapeutic purposes<sup>1-4</sup>.

Treatment of GOO will depend on the cause, but adequate resuscitation of the patient with gastric lavage is the key to successful treatment. The condition is never treated as a surgical emergency<sup>1-7</sup>.

The treatment could be medical or surgical. Most patients with peptic ulcer disease who develop GOO from edema of the pylorus, often resolve with conservative treatment using nasogastric suction, fluid and electrolyte replacement and proton pump inhibitors<sup>1-3</sup>. Surgical management in this scenario is done when conservative management fails. Surgical options include open laparotomy with adhesiolysis,

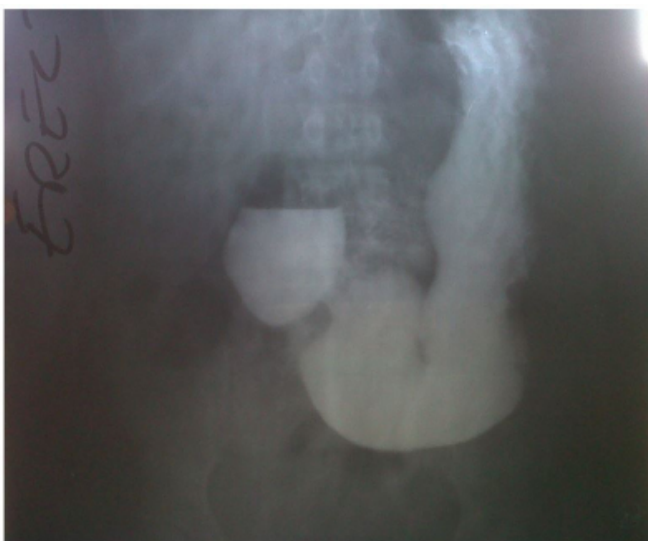pyloroplasty and antrectomy with either a Billroth I or II anastomosis. Also, endoscopic stenting (duodenal stents) or laparoscopic procedures such as a pyloroplasty or gastrojejunostomy can be done<sup>1-4</sup>.

### **CASE REPORT**

Mrs AO, a 62-year-old female presented in the surgical outpatient department of the University of Calabar Teaching Hospital with recurrent colicky abdominal pain, vomiting, weight loss and poor appetite, all of 4 months duration. These symptoms developed 3 years after she had open cholecystectomy done in this hospital by the same surgical unit. She was not a known peptic ulcer disease patient. Abdominal ultrasound scan revealed a grossly dilated stomach with marked debris in the stomach. A barium meal and follow-through (figure 1) suggested gastric outlet obstruction with dilatation of the stomach up to the pelvis and distortion of the duodenal cap. Findings at surgery confirmed gastric outlet obstruction. At surgery, there was marked distortion of the lower third of the stomach and pylorus by fibrous adhesions plastering it to the gallbladder fossa and anterior abdominal wall (Figure 2, 3). Careful adhesiolysis to release the deformed lower third of the stomach was done as well as a prophylactic retrocolic gastrojejunostomy (Figure 4&5). The patient made an uneventful postoperative recovery .

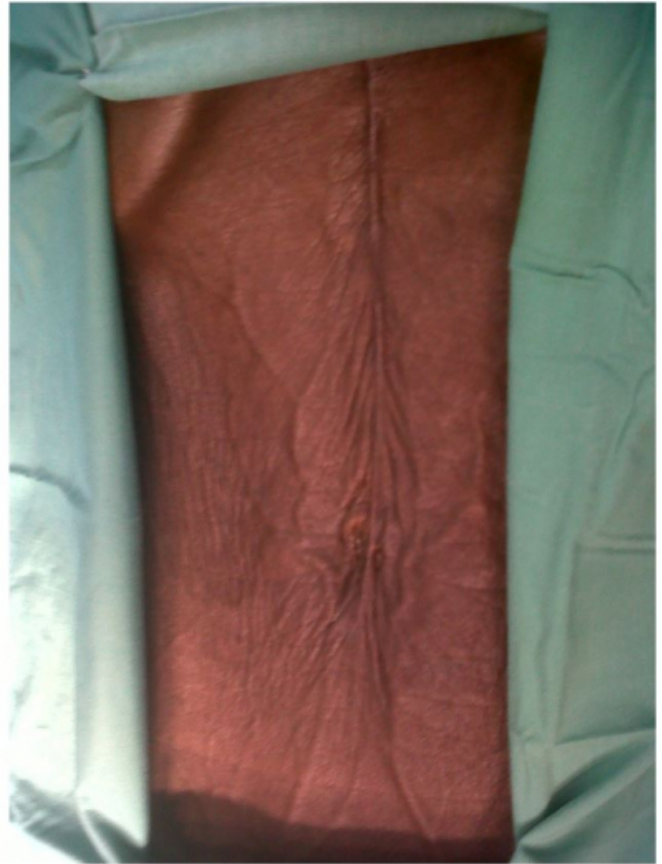**Figure 1**

Barium meal and follow-through showing marked gastric dilatation extending to the pelvis with deformed duodenal cap.



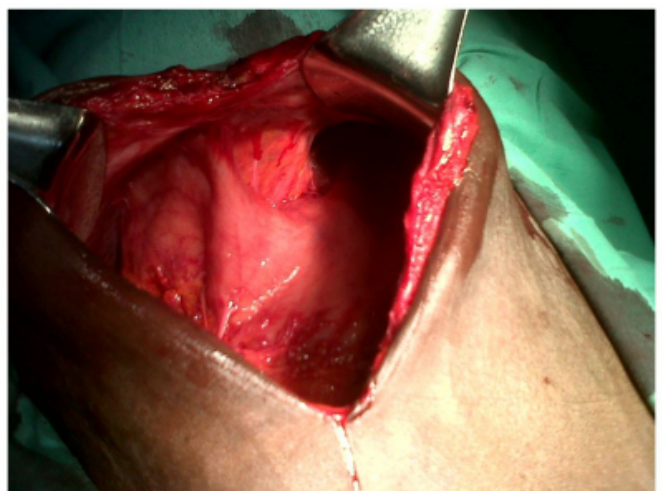
**Figure 2**

Picture showing marked wasting and the previous midline open- cholecystectomy scar



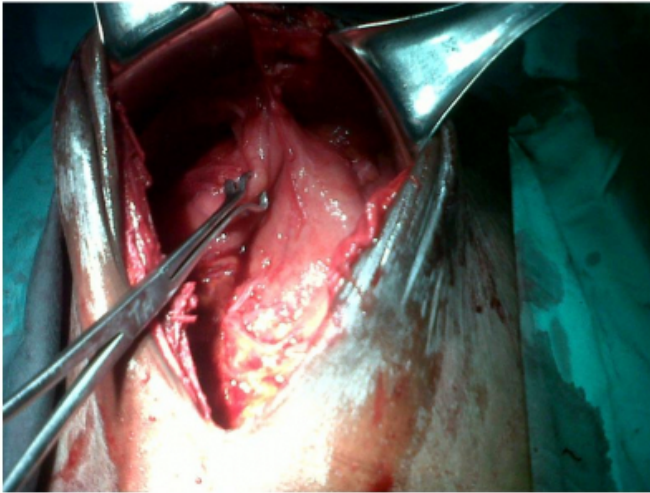
**Figure 3**

Dense fibrous adhesions plastering the deformed stomach to the anterior abdominal wall.



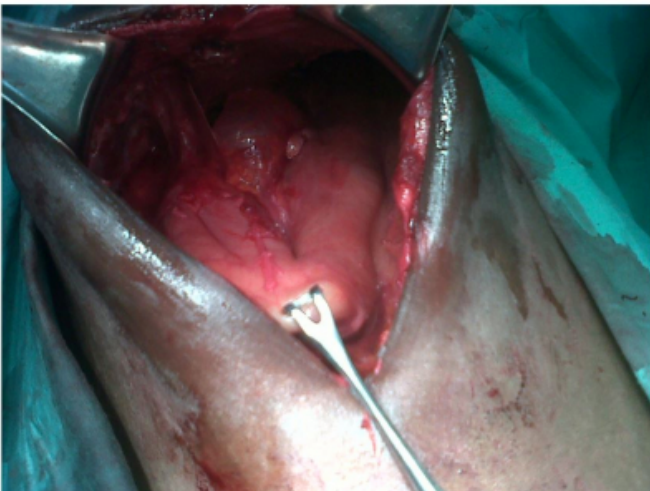
**Figure 3b**

Dense fibrous adhesions plastering the stomach to the liver and anterior abdominal wall after some adhesiolysis



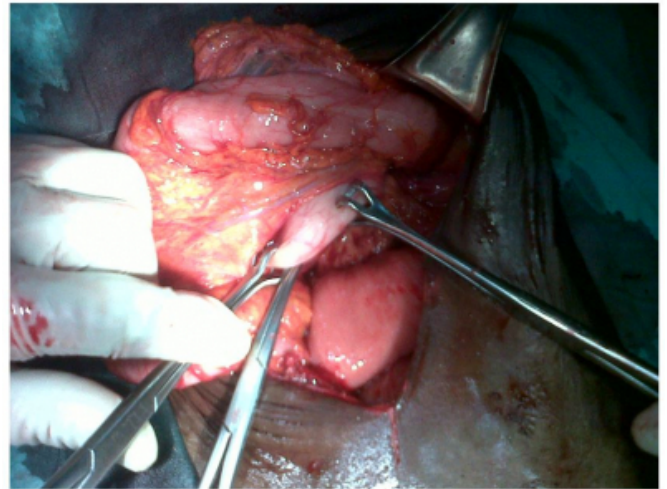
**Figure 4**

Markedly dilated stomach after adhesiolysis was done. The left lobe of the liver is seen still plastered to the anterior abdominal wall.



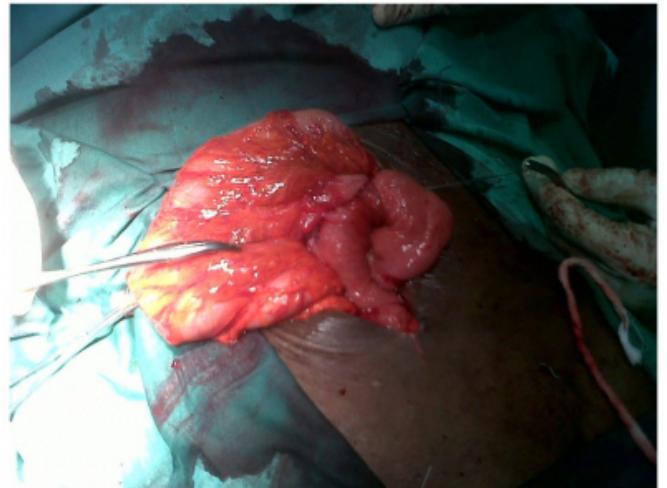
**Figure 5**

Fashioning of the prophylactic retrocolic gastrojejunostomy.



**Figure 6**

Prophylactic gastrojejunostomy done



## DISCUSSION

Gastric outlet obstruction following postoperative adhesions is rare <sup>4</sup>. The cause of GOO in our index patient was initially thought to be due to an intra-abdominal malignancy because of her age and the attendant marked wasting (figure 2). However, clinical evaluation and relevant investigations excluded malignancy. Her barium meal and follow-through demonstrated a huge dilated stomach extending into the pelvis (figure 1). This has been documented in the literature<sup>1-3</sup>.

Strict adherence to operative surgical principles came to the fore in this case. As documented in the case summary, the left lobe of this patient's liver was plastered astride to the previous laparotomy scar (figures 3a-c). An inadvertent

hemi-hepatectomy could have been done if abdominal access was obtained through the previous scar rather than from a virgin site beyond the previous scar in line with surgical principles. Figure 4 shows the dilated stomach after adhesiolysis, while figures 5 and 6 show the prophylactic gastrojejunostomy.

Since postoperative adhesions have a high incidence following each surgical intervention, the surgeon considered it necessary to do a gastrojejunostomy as a prophylactic measure to avoid a situation where the abdomen will be re-explored should GOO recur from new adhesions in future.

The role of laparoscopy in adhesiolysis is well documented in the literature and previous abdominal surgery is no longer considered a contra-indication to laparoscopy<sup>2, 9-12</sup>. However facilities for laparoscopy were not available in our center at the time this patient was treated.

Laparoscopic cholecystectomy should be encouraged where facilities and expertise exist because it provokes less adhesion formation compared to open cholecystectomy<sup>10,11,12</sup>. If laparoscopic cholecystectomy had been performed in this patient, the dense fibrous adhesions involving the liver and stomach at the laparotomy scar may not have occurred, thus preventing the GOO.

## CONCLUSION

Gastric outlet obstruction following postoperative adhesions from open cholecystectomy is a rare condition. A barium meal and follow-through is an invaluable investigation in making a diagnosis of GOO, especially where gastroscopy is unavailable. Laparoscopic cholecystectomy should be encouraged as the incidence of

post-operative adhesions is less with it.

## References

1. Baako BN, Tandoh JFK: Stomach and duodenum. In: Badoe EA, JFK Tandoh, BN Baako eds. Principles and Practice of Surgery – Including Pathology in the Tropics. 4th Ed. Accra: Assemblies of God Literature Centre Ltd. 2009, 621-635.
2. Primerose JN: Stomach and duodenum. In: Russel RCG, Williams NS, Bulstrode CJK, eds. Bailey and Love's Short Practice of Surgery, 23rd Ed. London: Arnold 2008, 1065-1066.
3. Mercer DW, Robinson EK: Stomach. In: Courtney M, Beauchamp R, Evers B, Mattox K, eds. Sabiston Textbook of Surgery, 17th Ed. Elsevier Saunders 2004, 1294-95.
4. Mocciaro F, Curcio G, Tarantino I, Barressi L, Burgio G, Gruttadauria S, Caruso S, Traina V: Adhesions due to peritoneal carcinomatosis leading to mechanical gastric outlet obstruction: a case report. J Med Case Reports; 2011; (5): 306.
5. Gençosmanoğlu R, Sad O, Sav A, Tözün N: Primary hypertrophic pyloric stenosis in the adult: a case report. Turk J Gastroenterol; 2002; 13: 175-9.
6. Dev V, Shah D, Gaw F, Lefor AT: Gastric outlet obstruction secondary to post cholecystectomy biloma: case report and review of the literature. JSLS; 1998; 2: 185-188.
7. Tiwary KS, Khanna R, Khanna A: Transmural migration of surgical sponge following cholecystectomy: an unusual cause of gastric outlet obstruction. Internet J Surg; 2006; 7(2).
8. Park JM, Chi KC: Unresectable gastric cancer with gastric outlet obstruction and distant metastasis responding to intraperitoneal and folfox chemotherapy after palliative laparoscopic gastrojejunostomy: report of a case. World J Surg Oncol; 2010; 8: 109.
9. Al-Rashedy M, Issa ME, Ballester P, Ammori BJ: Laparoscopic surgery for the management of obstruction of the gastric outlet and small bowel following previous laparotomy for major upper gastrointestinal resection or cancer palliation: a new concept. J Laparoendosc Adv Surg Tech A; 2005; 15: 153-159.
10. Efem SEE, Ogunsina GS: Stomach and duodenum. In: Adelola Adeboye, Opeoluwa O Adekunle, Oluyombo A Awojobi, eds. Davey's Companion to Surgery in Africa, 3rd Ed., Acecool Medical Publishers, Eruwa, Nigeria, 2009; 312.

**Author Information**

**OE Ngim**

Department of Surgery, University of Calabar Teaching Hospital (UCTH)  
Cross River State, Nigeria  
ogbungim@yahoo.com

**C Agbor**

Department of Surgery, University of Calabar Teaching Hospital (UCTH)  
Cross River State, Nigeria

**EE Essien**

Department of Radiology, University of Calabar Teaching Hospital (UCTH)  
Cross River State, Nigeria

**DU Eduwem**

Department of Radiology, University of Calabar Teaching Hospital (UCTH)  
Cross River State, Nigeria

**R Ndoma-Egba**

Department of Surgery, University of Calabar Teaching Hospital (UCTH)  
Cross River State, Nigeria