

# Asymmetry Of Both Groins In Melanoderms: Preliminary Study

P Manyacka Ma Nyemb, J Ndoeye, A Ndiaye, A Ndiaye, M Diop, A Ndiaye

## Citation

P Manyacka Ma Nyemb, J Ndoeye, A Ndiaye, A Ndiaye, M Diop, A Ndiaye. *Asymmetry Of Both Groins In Melanoderms: Preliminary Study*. The Internet Journal of Surgery. 2014 Volume 31 Number 2.

## Abstract

**Introduction:** This work is motivated by the frequency of surgery for inguinal hernias. Paradoxically, this fact is correlated with the misunderstanding of the anatomy of the groin. Through this work we wanted to show that in addition to individual variations found among patients with groin hernias, the main anatomical landmarks vary from one side to the other, including in the same subject.

**Patients and Methods:** We realized a prospective study in 42 melanoderm male patients, presenting a groin hernia. An external morphometry of the groin was performed pre- and intraoperatively using major groin landmarks.

**Results:** Twenty-five hernias were found on the right side, and 20 on the left side. These hernias were indirect (external oblique) in 82.3% of cases. Using measurements taken on each groin, we represented and then compared the two mapped inguinal regions. We observed differences in the topography of the groin landmarks depending on whether one is left or right.

**Conclusion:** The topography of landmarks of the inguinal region in general, and that of the deep inguinal ring in particular, are highly variable. There is significant variability of the position of right and left landmarks, including in the same subject. This variation must be taken into account by the operator, especially during the surgery of bilateral hernias.

## INTRODUCTION

The treatment of groin hernias is among the most performed surgical procedures. The anatomy of the inguinal region is an essential prerequisite for any surgery in the groin. It includes conventional anatomy as taught for generations in reference books, but also many anatomical variations found in the groin. These anatomical variations - including those found between the left and right inguinal regions - have been poorly documented, or occulted. However, it appears that there are significant differences between the both inguinal regions<sup>1,2</sup>. These dissimilarities that are also found inside the same subject have implications for the surgical procedure, especially during the surgery of bilateral groin hernias. The risk factors for onset of groin hernias are well known, and the stability of elements that constitute the lower anterior abdominal wall also plays an important role. More recently it has been shown that hernia diseases are essentially a disease of collagen fibers<sup>3</sup>. However, the asymmetry found in the anatomical landmarks of both inguinal regions is mainly explained by embryology<sup>4</sup>. This study is performed in order to find out anatomical variations between left and right groins in melanoderms presenting

with inguinal hernias.

## MATERIAL AND METHODS

This was a prospective study using anatomical data of male subjects, carrying one (or more) uncomplicated hernia(s) of the groin. Our sample consisted of 42 subjects; the study was conducted over a period of 6 months. The type of hernia was specified, and groins concerned were divided according to their left or right topography. Pre- and per-operatively, distances between anatomical landmarks of 45 groins (including 3 bilateral hernias) were measured or calculated.

After the identification of bony landmarks (Fig. 1) and the femoral artery crossing, the following distances were measured:

Anterior superior iliac spine – Pubic symphysis  
(ASIS – PS)

Anterior superior iliac spine – Pubic tubercle  
(ASIS – PT)

Anterior superior iliac spine – Deep inguinal ring

(ASIS – DIR)

Anterior superior iliac spine – Femoral artery  
(ASIS – FA)

Following distances were calculated:

Anterior superior iliac spine – Mid-inguinal point  
(midway between the anterior superior iliac spine and pubic symphysis): ASIS – MIP

Anterior superior iliac spine - ½ of the inguinal  
ligament (midway between the anterior superior iliac spine  
and pubic tubercle): ASIS - ½ of IL

We also noted the position of the deep inguinal ring relative  
to the femoral artery:

Medial

Lateral

Projection on the femoral artery

## RESULTS

Our 42 subjects were male, 3 of them had bilateral inguinal  
hernias. We found 25 hernias on the right groin, and 20  
hernias on the left groin. The average age was 42 years and 4  
months; 41 groins (91.1%) were examined under regional  
anesthesia and 4 groins (8.9%) under general anesthesia.

The following results were found about the topography and  
type of hernia:

22 (48.9%) hernias on the right side, including:

16 (35.5%) right inguinal hernias

6 (13.3%) right inguinoscrotal hernias

17 (37.7%) hernias on the left side, including:

12 (26.7%) left inguinal hernias

5 (11.1%) left inguinoscrotal hernias

3 bilateral hernias (that to say 6 hernias and 13.3%  
of patients), including:

Two bilateral inguinal hernias: that to  
say 4 hernias (8.9%)

One inguinoscrotal bilateral hernia: that  
to say 2 hernias (4.4%)

In total, our sample was divided in 25 right groins and 20

left groins.

Regarding the position of the deep inguinal ring relative to  
the right femoral artery, we found in 18 cases a medial  
position, in 2 cases a lateral position, and in 5 cases a  
superposition of both anatomical structures.

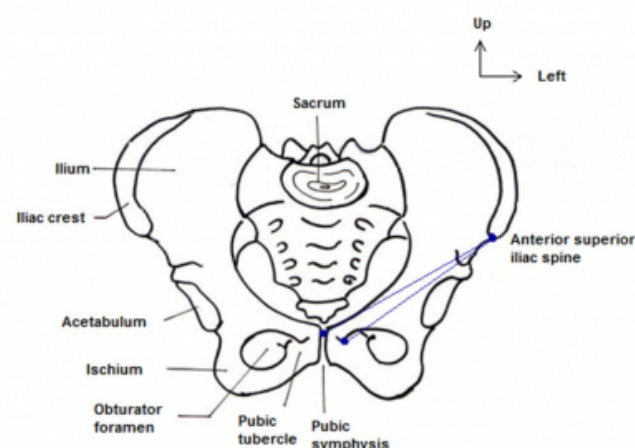
Regarding the position of the deep inguinal ring relative to  
the left femoral artery, we found in 13 cases a medial  
position, in one case a lateral position, and in 6 cases a  
superposition of both anatomical structures.

More detailed results are presented in Table 1.

On the right, the distance ASIS - PS was 5 mm greater, the  
distance ASIS - PT was 4 mm greater, deep inguinal ring  
had a 5 mm more medial situation compared to the left side,  
and the femoral artery had a 6 mm more lateral path  
compared to the left side.

**Figure 1**

Pelvic bony landmarks (figure drawn by author)



**Table 1**

Distances between main landmarks of both groins

GROINS	Distances in millimeters: averages (limits)					
	ASIS - PT	ASIS - PS	ASIS - DIR	ASIS - FA	ASIS - MIP	ASIS - ½ of IL
Total (N=45)	124.82 107 - 135	152.42 148 - 163	83.62 68 - 94	77.91 70 - 90	76.21 74 - 82	62.41 54 - 68
Right (N=25)	126.42 107 - 135	154.83 151 - 163	86.35 72 - 94	73.94 70 - 86	77.42 75 - 82	63.21 54 - 68
Left (N=20)	122.38 113 - 132	149.76 148 - 160	81.08 68 - 91	79.66 70 - 90	74.88 74 - 80	61.19 57 - 66

## DISCUSSION

In sub-Saharan Africa, the problem of groin hernias is not

the same as in the occident. Between 7.7 and 20% of the adult male population has at least a groin hernia in our context 5. Anatomical arguments may partially explain the high incidence of inguinal hernias in African populations<sup>4,6</sup>. In general, the target population is young and active (34 years old on average versus 62 years old in Europe), with a significant impact on the local economy 5. Hernias are larger due to the delay of consultation. A significant proportion of these hernias is operated in emergency, with major complication and recurrence rates. In our context, the non-prosthetic repair techniques are predominant, even for hernias operated electively. Thus, our knowledge of the groin anatomy is of paramount importance.

The history of laparoscopic hernia repair is relatively recent in sub-Saharan Africa. However, the demand is increasingly growing. The main indications are represented by the bilateralism of the disease, recurrence after a conventional approach, and patient preferences<sup>7</sup>. The laparoscopic approach requires an accurate knowledge of anatomy to prevent increased morbidity. Abnormal or aberrant situations of anatomical landmarks are not uncommon and should also be considered. However, few studies have documented the compared prevalence of these anatomical abnormalities to the left or to the right side. Some geometrical concepts ("trapezoid of disaster", "circle of death", "devil and pain triangles") show the importance of anatomical landmarks in mapping dangerous groin areas in endopelvic situation.

In our study we use bony anatomical landmarks such as ASIS, PS and PT. These landmarks have been exploited in many studies<sup>1,2</sup>. They have the advantage of being palpable in most subjects, including obese subjects. Because of their fixity, they also allow to better locate the non-bony anatomical landmarks such as DIR, FA, MIP and  $\frac{1}{2}$  of IL. We use data from living subjects in order to find the various measures in the operatory situation. Mapping the groin and estimating the position of the DIR is of paramount importance in the preoperative diagnosis of the type of hernia, although such proceedings are controversial. The position of the femoral artery and its branches is of importance both in the cure of hernia as for any femoral catheterization maneuver.

We find significant variations in the measured and calculated distances between the left and right groins. These variations are found not only among different subjects, but also between both groins of the same subject. They concern distances between bony landmarks, as well as the situation of DIR and FA. For example, in our work the ASIS-PT

distance varies from 20 to 25mm from one side to the other in the same subject. Scott<sup>2</sup> finds a difference of 19 millimeters. These variations are most probably significant in obese subjects due to the difficulty to accurately locate bony landmarks. Chleborad<sup>1</sup> confirms this observation in obese patients.

The asymmetry and anatomic variations in the same subject are documented in the literature. Chleborad<sup>1</sup> finds that there are many variations in dimensions on the pelvis, between left and right sides. These variations have an impact on the situation of anatomical landmarks resulting of calculated distances (mid-inguinal point and middle of the inguinal ligament). According to Scott<sup>2</sup>, the FA is located laterally to the mid-inguinal point (average of 3 mm), and DIR is medial to this point. The mid-inguinal point found corresponds to the projection of the external iliac artery. The distance between the FA and the medial margin of the DIR varies from 1 to 21 mm. For all these measures, Scott<sup>2</sup> finds variations between left and right groins, including in the same subject. In our study, we find, in some subjects, a lateral position of the FA from the mid-inguinal point only in the right side (3.5mm on average). However, a medial position of the DIR relative to this point is also visible in both sides. According to Scott<sup>2</sup>, the mid-inguinal point should be privileged as an anatomical landmark to locate the DIR and the path of the FA.

In his study, Chleborad<sup>1</sup> finds a significant difference in the ASIS-PT distance between both inguinal regions: it is greater on the right side. We also find this trend in our study. Other measurements made by Chleborad<sup>1</sup> show contralateral differences, but not significantly. These measures concern the horizontal line joining the PT to the FA, the vertical line joining the IL to the origin of the deep femoral artery, and the distance between the horizontal line passing through the PT and the origin of the deep femoral artery. Moreover, the last two measures show significant differences between the both sexes; this aspect has not been investigated in our study. Significant differences reported between measures of both sexes can be explained by dissimilarities between male and female bony pelvis. But they do not explain differences we find within the same sex, especially among men. Within the same sex, we can discuss the bilateral asymmetry phenomenon reported by several authors<sup>8</sup>. This phenomenon mostly concerns thorax cavity and upper extremities, and differences appear to be related to a further development of the dominant upper extremity. Chleborad<sup>1</sup> finds that FA crosses IL in the middle ( $\frac{1}{2}$  of IL),

with a symmetrical path between left and right sides. In our study, the FA crosses the IL 18.47mm medially to the ½ of IL on the left side, and 10.73mm medially to the ½ of IL in the right side. These differences can be explained by the fact that Chleborad<sup>1</sup> worked on cadaveric and not herniated groins.

According to several studies<sup>9</sup>, there are significant differences between the left and right inguinal regions since the fetal life. These differences only occur in males, and during the second and third trimester of pregnancy, with the formation of the processus vaginalis. The patent processus vaginalis (PPV) is a known phenomenon in the general population. It may be present at any age. However, males are the most affected with a predominance of the right side<sup>4</sup>. Thumbe<sup>10</sup> shows that in adult carriers of inguinal hernia, the presence of contralateral PPV can develop into a hernia if it is not treated. It is therefore logical that inguinal hernias are predominant on the same side as PPV, that to say the right side. The predominance of the right PPV is also found in the newborn. Mitchell<sup>11</sup> finds in his dissections that in birth there is a PPV in 70% of cases on the right side, and in only 60% of cases on the left side. Thus, authors suggest, in some patients, immediate bilateral hernia cure to prevent contralateral recurrence<sup>12</sup>.

According to Van Wessen<sup>4</sup>, the predominance of right PPV is explained by embryological phenomena. During intrauterine life, the migration of both testicles into the scrotum is guided by both processus vaginales. This descent ends earlier on the left side, and each processus vaginalis only closes after the complete descent of the testicles into the scrotum. The reasons for this asymmetric descent are currently poorly understood<sup>6,13</sup>. Consequences of this process include the predominance of right PPV, and the anatomical asymmetry of both groins, including in the same subject.

In addition to congenital causes, acquired factors can also explain the asymmetry of both groins. In adults, the biomechanics of the lower anterior abdominal wall and inguinal canal can confirm observations in the newborn. The stability of elements that constitute the lower anterior abdominal wall plays an important role in the occurrence of inguinal hernias. In his study, Wolloscheck<sup>14</sup> measured the strength and resistance of each of the main layers of the lower abdominal wall. The transversalis fascia, the parietal peritoneum, and fascias of the internal oblique muscle and external oblique muscle were examined. It is important to note that apart from differences that he finds concerning the

strength of each layer, Wolloscheck<sup>14</sup> reported significant differences between left and right inguinal regions. These differences appear even in the same subject. This explains the variability in the topography of inguinal hernias and anatomical landmarks of the inguinal region. Abnormalities reported in the synthesis of collagen fibers highlight this anatomical variability. This collagen disease is mostly met in bilateral hernias<sup>15,16,17</sup>.

Biomechanics of the lower anterior abdominal wall can explain the action of risk factors in the occurrence of hernia pathology. These risk factors are involved in the onset of unilateral and bilateral groin hernias<sup>18</sup>. However, even for bilateral hernias, it is rare to find symmetry of both groins.

## CONCLUSION

This preliminary study shows that the topography of the groin landmarks is highly variable. We also find variability between right and left sides, including in the same subject. Many factors may be involved as a cause of this anatomical asymmetry. In our context, this asymmetry must be considered by the operator, especially during surgery of bilateral hernia.

## References

1. Chleborad WP, Dawson DL: The profunda femoris artery: variations and clinical applications. *Clinical Anatomy*; 1990; 3: 33-40.
2. Scott PD, Willan PLT: Anatomical mythology? A study of surface markings of the inguinal region. *Clinical Anatomy*; 1991; 4: 216-222.
3. Bendavid R: The unified theory of hernia formation. *Hernia*; 2004; 8: 171-176.
4. Van Wessen KJP, Simons MP, Plaisier PW: The etiology of indirect inguinal hernias: congenital and/or acquired? *Hernia*; 2003; 7: 76-79.
5. Sanders DL, Porter CS, Mitchell KCD, Kingsnorth AN: A prospective cohort study comparing the African and European hernia. *Hernia*; 2008; 12: 527-529.
6. Brendan Devlin H, Kingsnorth A, O'Dwyer PJ, Bloor K: Epidemiology and aetiology of primary groin hernias in adult. In: *Management of abdominal hernias*, 2nd edn: Chapman and Hall Medical, London, 1998; Chap 3.
7. Saidi H: endoscopic anatomy of the groin; implication for transabdominal preperitoneal herniorrhaphy. *Anatomy Journal of Africa*; 2012; 1: 2-10.
8. Hamilton WJ, Simon G, Hamilton SGI: Surface and radiological anatomy for students and general practitioners, 5th ed. Baltimore, William and Wilkins, 1971; p.6.
9. Brito-Lima JS, Gusmao LCB, Ramalho AJC, Alves-Filho AC, Cavalcanti JS, Silva-Junior GO: Allometry and morphometry of the inguinal region in human fetuses. *Hernia*; 2009; 13: 533-538.
10. Thumbe VK, Evans DS: To repair or not to repair incidental defects found on laparoscopic repair of groin hernias. *Surg Endosc*; 2001; 15: 47-49.
11. Mitchell GAG: The condition of the peritoneal vaginal processes at birth. *J Anat*; 1939; 93: 658-661.
12. Steinau G, Böhm G, Vaassen P, Wenzl T, Schumpelick

V: contralateral inguinal hernia in childhood and youth: which child will develop a contralateral inguinal hernia? *Hernia*; 2008; 12: 631-634.

13. Clarnette TD, Hutson JM: The development and closure of the processus vaginalis. *Hernia*; 1999; 3: 97-102.

14. Wolloscheck T, Gaumann A, Terzic A, Heintz A, Junginger T, Konerding MA: Inguinal hernia: measurements of the biomechanics of the lower abdominal wall and the inguinal canal. *Hernia*; 2004; 8: 233-241.

15. Bendavid R: The unified theory of hernia formation. *Hernia*; 2004; 8: 171-176.

16. Ajabnoor MA, Mokhtar AM, Rafee AA, Taha AM: Defective collagen metabolism in Saudi patients with hernia. *Ann Clin Biochem*; 1992; 29: 430-436.

17. Friedman DW, Boyd CD, Norton P, Greco RS, Boyarsky AH: Increase in type III collagen gene expression and protein synthesis in patients with inguinal hernias. *Ann Surg*; 1993; 218: 754-760.

18. Fischer S, Cassivi S, Paul A, Troidl H: Evidence-based medicine and special aspects in bilateral inguinal hernia repair. *Hernia*; 1999; 3: 89-95.

**Author Information**

**P Manyacka Ma Nyemb**

Laboratoire d'Anatomie Humaine, UFR des Sciences de la Santé (UFR 2S), Université Gaston Berger  
Saint-Louis, Sénégal  
phil\_manyacka@yahoo.fr

**JM Ndoye**

Laboratoire d'Anatomie et d'Organogenèse, Faculté de Médecine de Pharmacie et d'Odontostomatologie, Université Cheikh  
Anta Diop  
Dakar, Sénégal

**Aï Ndiaye**

Laboratoire d'Anatomie et d'Organogenèse, Faculté de Médecine de Pharmacie et d'Odontostomatologie, Université Cheikh  
Anta Diop  
Dakar, Sénégal

**Ass Ndiaye**

Laboratoire d'Anatomie et d'Organogenèse, Faculté de Médecine de Pharmacie et d'Odontostomatologie, Université Cheikh  
Anta Diop  
Dakar, Sénégal

**M Diop**

Laboratoire d'Anatomie et d'Organogenèse, Faculté de Médecine de Pharmacie et d'Odontostomatologie, Université Cheikh  
Anta Diop  
Dakar, Sénégal

**Ab Ndiaye**

Laboratoire d'Anatomie et d'Organogenèse, Faculté de Médecine de Pharmacie et d'Odontostomatologie, Université Cheikh  
Anta Diop  
Dakar, Sénégal