

Pulmonary Involvement In Sweet's Syndrome: A Case Report And Literature Review

A J Huaringa, W H Francis

Citation

A J Huaringa, W H Francis. *Pulmonary Involvement In Sweet's Syndrome: A Case Report And Literature Review*. The Internet Journal of Pulmonary Medicine. 2014 Volume 17 Number 1.

DOI: [10.5580/IJPM.15078](https://doi.org/10.5580/IJPM.15078)

Abstract

There have been many reported cases of Acute Febrile Neutrophilic Dermatitis, since Dr. Sweet initially described the syndrome back in 1964. However, the pulmonary involvement has been eluded in only forty one cases .

We present a 67 year old man who was referred to us for an evaluation of a left hilar abnormality having no respiratory complaints. His past medical history revealed a recurrent erythematous, violaceous, plaque-forming, nodular rash involving hands, forearms and neck, that every time it would flare up, it was accompanied by fever. A retrospective analysis of his chest radiographs disclosed evidence of recurrent ill defined infiltrates concurrent with his febrile episodes and reactivations of his cutaneous disorder that he had been experiencing for the previous 6 years. These infiltrates would leave as sequelae linear fibrotic strands. During these episodes, the patient had been asymptomatic from respiratory standpoint; but his fever and dermatological lesions would respond dramatically to corticosteroid therapy.

Skin biopsy showed the classical dermal neutrophilic infiltration without vasculitis, compatible with Sweet's Syndrome. Fiberoptic bronchoscopy revealed purulent secretions coming out of the superior segment of the left lower lobe and a fine needle lung aspiration disclosed alveolar macrophages and neutrophils. The stains, cultures, and cytologies from both procedures turned out to be all negative.

We conclude that based on the following facts: 1) cyclic concomitance of skin and lung diseases, 2) sterile nature of lung lesions and 3) the response to corticosteroid therapy; that we are reporting the forty second case of pulmonary involvement in Sweet's syndrome.

A review of the literature denoted 41 cases of pulmonary involvement in Sweet's syndrome, most of them associated with hematological malignancies with exquisite response to corticosteroid therapy which has triggered us to generate an etiological hypothesis.

INTRODUCTION

Sweet's Syndrome (SS) or acute febrile neutrophilic dermatosis is a systemic inflammatory disorder characterized by fever, leukocytosis, and tender erythematous skin lesions. This disorder typically involves multiple organs; but pulmonary involvements is rare. The classical manifestations of pulmonary involvement in SS are lung infiltrates, pleural effusion, and bronchiolitis obliterans organizing pneumonia (BOOP). Treatment with steroids shows dramatic improvement. Colchicine and immunosuppressant agents may also be used in treatment.

CASE REPORT

A 68- year old white male was referred to the pulmonary consultation service for evaluation of left hilar mass. He had history of adult - onset diabetes mellitus (AODM) and atherosclerotic heart disease (ASHD) requiring permanent pacemaker insertion 7 years ago and a 50 pack-year cigarette smoking history. He denied night sweats, and weight loss. There was a history of an episode of respiratory tract infection five months ago for which he was treated with oral antibiotics for ten days. He has had dyspnea on exertion for many years, but no recent increase has been noted.

This patient has also had history of recurrent erythematous

rash associated with nodular plaque lesions and pustules on forearms, hands, and neck for last 7 years. Skin biopsy was done in past and diagnosis of Sweet's Syndrome was established and was treated with Prednisone 40 mg/day as recommended by dermatology service.

He also reported history of "spots in the lungs" in the past and review of his old records revealed reports of pulmonary infiltrates at different sites at different times with no pulmonary symptoms. Extensive workup was done several times including cultures of sputum, blood, and urine, thoracentesis, and bronchoscopy. None of tests revealed any infectious, granulomatous or malignant etiology of his pulmonary infiltrates.

Past medical history was consistent with peptic ulcer disease (PUD), ASHD, Diabetic Mellitus with neuropathy. No history of tuberculosis (TB), sarcoidosis, or any fungal disease.

His medications include Insulin, Lasix, Digoxin, Nitropaste, Fluphenazine, Nortryptiline, Lisinopril, Diltiazem, Pentoxifiline, Sucralfate, and Clonidine.

He was divorced and worked as a taxi driver. He had a history of alcohol abuse in the past. His mother has a history of ASHD.

Upon examination, the patient appeared chronically ill appearing in no acute distress. The temperature was 99.2 F., the blood pressure 120/76, the heart rate 76 per minute with regular rhythm, and the respiratory rate 18 breaths per minute. The skin showed erythematous purple rash in both hands and forearms with multiple nodular lesions of 4 to 10 mm in size and pustules. Few of such lesions also were present on the neck. The head and neck examination revealed pupils equally reactive to light. Few teeth were present with poor oral hygiene. The neck was supple with no jugular venous distension, or adenopathy. The chest exam disclosed hyperinflation, with decreased breath sound in both sides, no crackles or wheezes. The auscultation of the heart showed normal heart sounds without gallop or murmurs. The abdomen was soft, no hepato or splenomegaly, no masses, bowel sounds were normal. The extremities showed no joint swelling, clubbing, or pedal edema. On neurological examination, the patient was alert, oriented times 3, decreased sensations to fine touch and pain in both hands and feet.

The laboratory results revealed a white blood cell count of 10.6 k/mcl, Hemoglobin 15g/dl, Hematocrit 43.5%,

Platelets 409 k/mcl, Glomerular filtration rate 89 ml/min, Sodium 135 mEq/L., Potassium 4.6mEq/L., Chloride 101 mEq/L., Bicarbonate 26 mEq/L., Glucose 94 mg/dl, BUN 24 mg/dl, Serum creatinine 9 mg/dl, Ca 9.1 mg/dl., Urine analysis was unremarkable, Erythrocyte sedimentation rate was 5mm/h.

Pulmonary function testing disclosed an FVC of 4.12 L (90% predicted) and FEV1 2.4 L (68% predicted). The chest X-ray revealed bilateral hilar infiltrates. Bronchoscopy showed no endobronchial lesions, but purulent secretions were noted coming from the left lower lobe superior segment.

The microbiological analysis of the secretions was negative for bacteria, acid-fast bacilli, and fungus. A fine needle aspiration of the lung infiltrate showed pulmonary macrophages, but no malignant cells.

DISCUSSION

One half century after Dr. Sweet described the Acute Febrile Neutrophilic Dermatositis syndrome, there have been 41 cases reported of pulmonary involvement and here we are reporting the 42nd case.

This is a 67 year-old man, who was referred to us for an evaluation of a left hilar abnormality, having no respiratory complaints. His past medical history revealed a recurrent erythematous, violaceous, plaque-forming, nodular rash involving hands, forearms, and neck that every time it would flare up, it was accompanied by a fever. A retrospective analysis of his chest radiographs disclosed evidence of recurrent ill defined infiltrates concurrent with his febrile episodes and reactivations of his cutaneous disorder that he had been experiencing for the previous 6 years. These infiltrates would leave as sequelae linear fibrotic strands. During these episodes, the patient had been asymptomatic from respiratory standpoint; but his fever and dermatological lesions would respond dramatically to corticosteroid therapy.

Skin biopsy showed the classical dermal neutrophilic infiltration without vasculitis, compatible with SS. Fiberoptic bronchoscopy revealed purulent secretions coming out of the superior segment of the left lower lobe and a fine needle lung aspiration disclosed alveolar macrophages and neutrophils. The stains, cultures, and cytologies from both procedures turned out to be all negative.

In our literature review we obtained a total of 42 patients

including ours, 19 of them were men and 23 women. The average age was 54.36. Seven patients (17%) have AML. Three patients had anemia. Five patients had a cardiovascular disease. Twelve patients had unremarkable underlying conditions. With chest X-ray 18 patients showed only unilateral infiltrate. From the 42 patients one patient was treated and improved with colchicine. Forty patients had been treated with steroids, 29 patients improved on steroid alone without any recurrence or complications. Five patients improved on combination between steroid and other medications. Five patients improved on steroid then died for a different condition. One patient improved with steroid but had a recurrence.

We conclude that based on the following facts: 1) cyclic concomitance of skin and lung diseases 2) sterile nature of lung lesions 3) response to corticosteroid therapy; that we are reporting the forty-second case of pulmonary involvement in Sweet's syndrome.

Table1a

Previously Reported Cases of Sweet's Syndrome with Pulmonary Involvement

Age/ Gender	Underlying condition	Lung biopsy/ Aspiration	Outcome	Ref#
67 //M	DM/ASHD	Macrophage proliferation and fibrosis . clinically sterile suppurative process	Improves with S. but several recurrences	Present Case
66/ F	Agnogenic myeloid metaplasia	Neutrophil infiltrate with suppurative exudate	Improved with S.	1
60/M	AML	Intraalveolar neutrophilic infiltrate with fibrosis	Improved with S.	2
54/M	Myelodysplastic Syndrome	Interstitial inf. and alveolar neutrophilic exudates	Improved with S. temporarily and died by ARF	3
82/M		L.L.L. inf./ Alveolar and interstitial Syndrome/ neutrophils	Improved with S.	4
20/M		RML,RLL and LLL infiltration/ multilobular PNA	Improved on colchicine 60mg BID	5
74/F	MDS	Unilateral infiltration + effusion / neutrophil infiltrate in lung biopsy	Improved with S.	6
54/F	Seizure disorder	2.5 cm nodule in the Rt. lung base	Improved with S.	7
69/F	Dyslipidemia	3 cm opaque mass in the RUL/large infiltrate in the lt. lingula and LLL	Improved with S.	7
50/F	AML	Unilateral inf/effusion	Improved with S.	8
32/M		Bilateral reticulonodular infiltrations/ pleural effusion. Lung biopsy showed interstitial inflammation . neutrophilic infiltrations	Improved with S.	9
68/F	Dressler's Syndrome	Unilateral infiltration /effusion	Improved with S., Dapson	10

Table1b

Previously Reported Cases of Sweet's Syndrome with Pulmonary Involvement

<1/ F		Hyperinflation of the lungs	Improved with S.	11
67/ F	Plantar pustulosis	Unilateral infiltration	Improved with S.	12
45/M	AML	Bilateral infiltration/ extensive PMN infiltrate + pleural and perivascular fibrosis	Improved with S.	13
80/M	MDS/ AML	Left lower lobe infiltrate revealed bronchiolitis obliterans organizing pneumonia BOOP with pleural effusion	Died after Unresponsive to variety of medication	14
72/F		Bilateral infiltration/ neutrophil infiltration	Improved with S.	15
54/F	MDS	Unilateral interstitial infiltrate+ neutrophil infiltrate	Improved with S. then died	16
58/M		Unilateral infiltrate/ extensive PMN Infiltrate	Improved with S.	17
54/M	Refractory anemia with excess blasts	Bilateral infiltrate / interstitial infiltrate + neutrophil infiltrate	Improved with S. the died	18
35/M	ITP	Bilateral infiltration + effusion	Improved with S.	19
46/M	DMS	Bilateral infiltrate + effusion /mixed interstitial pneumonitis	Improved with S.	19
61/M	Myeloproliferative disorder	Bilateral infiltration	Improved with S.	19
74/F	Refractory anemia with excess blasts	Bilateral infiltration+ effusion	Improved with S.	19
34/M		Unilateral infiltration/interstitial pneumonitis/ cryptogenic organizing pneumonia	Improved with S.	20
63/F	AML	Bilateral infiltration	Improved with S.	21
62/F		Bilateral infiltration	Improved with S. the died	22
48/ F	refractory anemia with excess blast	Unilateral infiltration	Improved with S. - Chemo	23
70/F	Sjogren	Unilateral infiltration/ interstitial pneumonitis	Improved with S.	24

Table1c

Previously Reported Cases of Sweet's Syndrome with Pulmonary Involvement

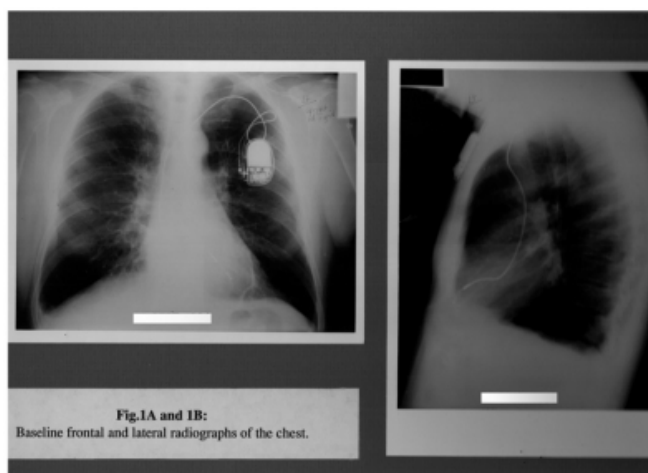
72/ F	MDS	Bilateral infiltrate / neutrophilic infiltrate	Improved with S. + Chemo.	25
55/ M		Bilateral infiltrate/ Ch. interstitial infiltrate	Improved with S. + Cyclo.	26
51/ M		Unilateral infiltration/interstitial pneumonitis/ cryptogenic organizing pneumonia	Improved with S.	27
40/ F		Left lower zone consolidation	Improved with S.	28
25/ F	Myeloproliferative disorder	Unilateral infiltration+ effusion/ Bronchiolitis obliterans organizing pneumonia	Improved with S. + dapson	29
67/ M	AML	Bilateral infiltration	Improved with S.	30
25/ F		Bilateral pulmonary nodules	Improved with S.	31
73/ F	Previous SS	Unilateral infiltration/ chronic interstitial infiltrate with alveolar wall thickening and neutrophils	Improved with S.	32
32/ M	Chronic liver disease	Bilateral infiltration	Improved with S.	33
54/ M	Hypertension	Unilateral infiltration	Improved with S.	34
76/ F	IgA Myeloma		Improved with S.	35
26/ F		Air space filling with aggregated of neutrophils	Improved with S.+ colchicine then died	36
67/ M	Hypertension	Unilateral infiltration	Improved with S. then died	37

AML: Acute myeloid leukemia; Chemo: Chemotherapy; Cyclo: Cyclophosphamide; DMS: Dermatomyositis; F: Female; ITP: Idiopathic thrombocytopenia; M: Male; MDS: Myelodysplastic syndrome; MPD: Myeloproliferative disorder; S: Steroids; D: day; Y: year

A chest X-ray revealed bilateral hilar infiltrates (Fig.1).

Figure 1

Bilateral parahilar infiltrates on chest x-ray



CONCLUSION

Based on the significant evidence of pulmonary involvement in this case and the other reported cases we conclude that Sweet's Syndrome or so called Acute Febrile Neutrophilic Dermatitis does involve the lung, it is frequently

encountered in association with granulocytic cell proliferation or immunological conditions, it does respond to corticosteroid therapy but it has high recurrence rate and promotes a great deal of pulmonary fibrosis which ultimately may lead patients to respiratory insufficiency and death, therefore it should be considered in the differential diagnosis of lung infiltrates.

References

1. Gibson L, Dicken C, Flach D: Neutrophilic dermatoses and myeloproliferative disease: Report of two cases. Mayo Clinic Proc. 1985;60:735-40.
2. Lazarus A, Mc Millan M, Miramadi A : Pulmonary involvement in Sweet's Syndrome (Acute febrile neutrophilic dermatosis). Chest 1986;90: 922-4.
3. Cohen P, Talpaz M, Kurzrock R: Malignancy-associated Sweet's Syndrome: Review of world literature. J. Clin. Oncol. 1988;6:1887-97
4. Astudillo L, Sailler L, Launay F, Josse A, Lamant L, Couret B, Arlet-Suau E.: Pulmonary involvement in Sweet's Syndrome: a case report and review of the literature. Int J Dermatol 2006;6:677-80.
5. Pillai A, Patel N, Kasarabada A, (2012). A case of Sweet Syndrome with pulmonary manifestations. Processing of 2012 American Thoracic Society International Conference: doi:10.1164/ajreem-conference. 2012.185.
6. Fernandez-Bussy S, Labarca G, Cabello F, Cabello H, Folch E, Majid A. Sweet's Syndrome with pulmonary involvement: Case report and literature..Respiratory Medicine Case Reports6(2012)16-19.
7. David j, DiCaudo, Karel JillOrtiz, Stephanie J, Menghden, Katheren K., :Sweet Syndrome (acute Febrile neutrophilic dermatosis) associated with pulmonary coccidioidomycosis. Arch Dermal.2005;141:881-84
8. Soderström R. :Sweet's Syndrome and acute myelogenous leukaemia: a case report and review of the literature. Cutis 1981;28:255e60.
9. Hande A, Nefise Ö, Güven C, Cevdet A, Figen B, Nihal P, Deniz A: Pulmonary and Central Nervous System Involvement in Sweet's Syndrome: A Very Rare Case Report(Inter Med 47: 1481-1484, 2008).
10. Rodriguez de la Serna A, Domingo-Pedrol L, Blanch-Torra L. Acute febrile neutrophilic dermatosis (Sweet's Syndrome) associated with post-myocardial infarction syndrome (Dressler's syndrome). Arch Intern Med 1985;145:1522e4.
11. Ryan A, BS1, Joshua D. Shofner, Daniela K: An Infant with Pulmonary-Cutaneous Sweet Syndrome. J Pediatr 2012;161:959-61
12. Keefe M, Wakeel R, Kerr R: Sweet's Syndrome, plantar pustulosis and vulval pustules. Clin Exp Dermatol 1988;13:344e6.
13. Hatch M, Farber S, Superfon N, Ligorsky R, Williams H: Sweet's Syndrome associated with chronic myelogenous leukaemia. J Am Osteopath Assoc 1989;89:363e70.
14. Tamihiro K, Ayumi K, Sora T, Shinji Y, Norihiro F, Shingo T, Masako M, Yoshinao S: Sweet Syndrome Subsequent to Relapsing Polychondritis and Myelodysplastic Syndrome in a Japanese Patient. Acta derm venereol 2008;88(5):517-9.
15. Bourke S, Quinn A, Farr P, Ashcroft T, Gibson G: Neutrophilic alveolitis inSweet's Syndrome. Thorax

- 1992;47:572e3.
16. Takimoto C, Warnock M, Golden J: Sweet's Syndrome with lung involvement. *Am Rev Respir Dis* 1991;143:177e9.
17. Chien S, Jambrosic J, Mintz S: Pulmonary manifestations in Sweet's Syndrome: first report of a case with bronchiolitis obliterans organizing pneumonia. *Am J Med* 1991 Nov;91(5):553e4.
18. Komiya I, Tanoue K, Kakinuma K, Kaneda M, Shinohara T, Kuriya S: Superoxide anion hyperproduction by neutrophils in a case of myelodysplastic syndrome. Association of Sweet's Syndrome and interstitial pneumonia. *Cancer* 1991;67: 2337e41.
19. Fett D, Gibson L, Su W: Sweet's Syndrome: systemic signs and symptoms and associated disorders. *Mayo Clin Proc* 1995;70:234e40.
20. Reid P, Alderdice J, Carson J, Sinnamon D: Cryptogenic organizing pneumonia in association with Sweet's Syndrome. *Respir Med* 1996 Jan;90(1):57e9.
21. Rodot S, Lacour JP, Van Elslande L: Extracutaneous manifestations of neutrophilic dermatosis. *Ann Dermatol Venereol* 1996;123:129e34 [in French].
22. Thurnheer R, Stammberger U, Hailemariam S, Russi E: Bronchial manifestation of acute neutrophilic dermatosis (Sweet's Syndrome). *Eur Respir J* 1998;11:978e80. 23'
24. Katsura H, Motegi T, Yamada K, Uehara T, Gotoh R, Kida K, et al: Interstitial Pneumonitis Associated Sweet's Syndrome Elderly. *Nippon Ronen Igakkai Zasshi* 1999;36:887e92 [in Japanese].
25. Alberts W: 72-year-old man with fever, skin lesions, and consolidation on chest radiograph. *Chest* 2000;118:861e2.
26. Imanaga T, Hayashi T, Yoshii C, Suzuki S, Yatera K, Kido M: Pulmonary involvement in acute febrile neutrophilic dermatosis (Sweet's Syndrome). *Nihon Kokuyki Gakkai Zasshi* 2000;38:206e10 [in Japanese].
27. Longo M, Pico M, Bueno C, Lazaro P, Serrano J, Lecona M: Sweet's Syndrome and bronchiolitis obliterans organizing pneumonia. *Am J Med* 2001;111:80e1.
28. Ladhani S, Kample R, Sundaram P, Joshi J: Non respoding pneumonia with skin lesion. *Chest Dis Allied Sci* 2001;43:115-17.
29. Garg R, Soud Y, Lal R, Mehta N, Kone B: Myelodysplastic syndrome manifesting as Sweet's Syndrome and bronchiolitis obliterative organizing pneumonia. *Am J Med* 2006 Nov;119(11):e5e7.
30. Petrig C, Bassetti S, Passweg J, Marsch S: Acute respiratory failure due to sweet syndrome. *Am J Med Sci* 2006 Mar;331(3):159e61.
31. Fulton J: Rapidly progressive pulmonary sweet syndrome. *Chest* 2007. Case Reports 706S.
32. Kushima H, Mizunoe S, Ishii H, Hashinaga K, Yamasaki T, Kishi K, et al: A case of Sweet's syndrome with a variety of chest radiological findings. *Nihon Kokyuki Gakkai Zasshi* 2007 Sep;45(9):685e90 [Article in Japanese].
33. Aydemir H, Oztoprak N, Celebi G, Altinyazar C, Barut F, Piskin N, et al: Pulmonary and central nervous system involvement in Sweet's Syndrome: a very rare case report. *Intern Med* 2008;47(16):1481e4.
34. Lawrence K, Hachem R, Wildes TM, Canizares M: A 54-year-old man with a rash and pulmonary infiltrates. *Chest* 2008 Dec;134(6):1340e3.
35. Gaspar C, Leyral C, Orlandini V, Begueret H, Pellegrin J, Doutre M, et al: Lethal pulmonary involvement of neutrophilic dermatosis following erythropoietin therapy. *Ann Dermatol Venereol* 2008 May;135(5):384e8 [Article in French].
36. Robbins CM, Mason SE, Hughey LC: Sweet Syndrome with pulmonary involvement in a healthy young woman. *Arch Dermatol* 2009 Mar;145(3): 344e6.
37. Aparicio V, Gil P, Juárez A, Suárez C: Fatal sweet with pulmonary involvement. *Rev Clin Esp* 2010 Feb;210(2):96e7.

Author Information

Armando J. Huaringa, M.D.

Pulmonary and Critical Care Medicine Section, Mountain Home Veterans Administration Medical Center and East Tennessee James H. Quillen College of Medicine, Johnson City, Tennessee, USA; Department of Medicine, White Memorial Medical Center and Loma Linda University School of Medicine, Los Angeles, California
huaringa@sbcglobal.net

Wassem H. Francis, M.D.

Department of Medicine, White Memorial Medical Center