

# Patterns of Testicular Histopathology in Egyptian Azoospermic Men

M K Khalifa, A M Issa, M O El Hamshary, K Z Shaeer

## Citation

M K Khalifa, A M Issa, M O El Hamshary, K Z Shaeer. *Patterns of Testicular Histopathology in Egyptian Azoospermic Men*. The Internet Journal of Urology. 2014 Volume 13 Number 1.

DOI: [10.5580/IJU.15147](https://doi.org/10.5580/IJU.15147)

## Abstract

Testicular biopsy is considered the gold standard choice in reproductive practice with diagnostic and prognostic importance for Andrologists. Other markers such as serum androgens, FSH level and genetic tests for example cannot reliably differentiate between obstructive azoospermia (OA) and non-obstructive azoospermia (NOA) and can't predict mature sperm retrieval during Testicular Sperm Extraction (TESE).

Purpose: The present study aims to evaluate the percentage of sperm retrieval and the incidence of different testicular phenotypes in patients subjected to testicular biopsy exploration.

Methods: One hundred and twenty-four patients were studied. Hematoxylin and Eosin stained 5 microns paraffin sections were evaluated according to modified Johnsen scoring system. Results: The most common finding in this study was round spermatogenic arrest representing (27%) followed by hypospermatogenesis (22%). Sperm cells were retrieved from (40%) of patients/samples.

In conclusion; Testicular biopsy is critical in determining both reproductive prognosis and therapeutic considerations for azospermic men.

Key words: male infertility; spermatogenesis; TESE; testicular biopsy; testicular phenotypes; ICSI

## INTRODUCTION

The knowledge of the complicated process of spermatogenesis is the prerequisite to develop concepts for therapy of male infertility or to handle germ cells in the management of assisted reproduction (1). About 10% to 15% of men evaluated for infertility are diagnosed as azoospermic men (2). Azoospermia diagnosis is based on two sequential semen analyses indicating the absence of sperm in the original or centrifuged specimen (3; 4). The evaluation of men with azoospermia aimed at determining their causes and accordingly suitable treatment options. The causes of azoospermia can be divided into three main categories: pretesticular, testicular, and posttesticular (5). Evaluation of men with azoospermia included complete history taking, physical examination, genetic studies, hormonal profile and semen analyses. Different testicular phenotype alterations can't be accurately predicted or

discriminated through parameters such as follicle-stimulating hormone serum levels and testicular volume. Because of this, clinicians recommend Testicular Biopsy and/or Testicular Sperm Extraction (TESE) (3) to evaluate the type of pathology and the presence of sperm and spermatogenic cells respectively. Although testicular biopsy is an invasive choice, it is still the golden standard tool for the assessment of men with azoospermia. It represents the final outcome of a variety of testicular phenotypes, ranging from normal spermatogenesis with seminal tract obstruction or absence of vas deferens as in obstructive azoospermia cases to a variety of problems with the spermatogenic process itself as nonobstructive azoospermia cases (6). The indications for testicular biopsy have expanded during the last several decades. Previously azoospermic men with serum follicle-stimulating hormone (FSH) concentrations greater than 2 to 3 times normal were designated as having

severe testicular failure not amenable to conventional therapy, and a diagnostic testicular biopsy was considered unnecessary (3). However, beginning in the mid-1990s, intracytoplasmic sperm injection (ICSI) using sperm retrieved through testicular microdissection has become a viable treatment option for many of these individuals (7). ICSI procedure is unique compared with conventional in vitro fertilization in that it requires only a single, viable spermatozoon per oocyte (8). Therefore, many men who were not previously candidates for in vitro fertilization became now eligible for testicular biopsy.

In this study we investigated the incidence of different testicular phenotypes and different histological patterns in Egyptian azoospermic males opting for TESE-ICSI.

## MATERIALS AND METHODS

### Tissue samples

The study included 124 patients and 210 testicular biopsies collected from Al-Kamal Hospital for Fertility Care and Assisted Fertilization (Cairo, Egypt). All samples were obtained during routine diagnostic testicular biopsy and/or therapeutic testicular sperm extraction from infertile men presented with azoospermia. All patients signed written informed consent. TESE was performed under general anesthesia. All testicular biopsies obtained from 124 infertile men with obstructive or non-obstructive azoospermia were divided into two parts, one for tissue preserving in liquid nitrogen when the tissue is positive for mature sperm. The other part of testicular tissue approximately 2x2x2 mm diameter was fixed in Bouin fixative and paraffin embedding. After eosin-haematoxylin staining of sections, histological evaluation and scoring was performed.

### Histological examination

Tissue was fixed in Bouin's fixative, processed for the preparation of 5 microns paraffin section using SLEE® Microtome, United Kingdom, then stained with Hematoxylin and Eosin (9).

### Microscopic examination

Eosin/hematoxylin stained slides were examined under light microscope using Nikon Eclipse E400 compound microscope, USA. Spermatogenesis scoring was performed according to Johnsen 1970 (10) modified by Holstein et al. (11) as shown in table 1.

**Table 1**

Johnsen scoring system modified by Holstein (2003)

Stage	Description	Score
Intact spermatogenesis	many mature spermatids and zones of spermiation	10
modest reduced spermatogenesis	reduced number of mature spermatids, a few zones of spermiation	9
distinct reduced spermatogenesis	few mature spermatids, no spermiation	8
considerably reduced spermatogenesis	no mature spermatids, only immature spermatids, no spermiation	7
severely reduced spermatogenesis	only few immature spermatids, reduced height of germinal epithelium	6
arrest of spermatogenesis at the stage of primary spermatocytes:	many spermatocytes border the lumen of the seminiferous tubule	5
arrest of spermatogenesis at the stage of primary spermatocytes	a few primary spermatocytes are present	4
arrest at the stage of spermatogonia	A type spermatogonia multiply but do not develop to maturing cells of spermatogenesis	3
Sertoli cell only (SCO)	no germ cells, only Sertoli cells are present	2
no germ cells, no Sertoli cells	The seminiferous tubule is replaced by connective tissue ground substance	1

## RESULTS

Two hundred and ten testicular tissue samples were collected from 124 azoospermic men referred for ICSI-TESE Al-Kamal Hospital for Fertility Care and Assisted Fertilization (Cairo, Egypt) in the period from January 2012 until May 2013. Their age ranged from 22 to 60 years. Thirty eight patients had unilateral and 86 had bilateral testicular biopsies

during exploration. Unilateral or bilateral decision was according to the examination of wet preparation of first testis biopsy if it contains mature sperm it will be enough but if it wasn't sergeant proceed to bilateral biopsy procedures.

Mature sperm could be retrieved from 40% of the examined testicular tissues. According to slide examination of testicular tissue, specimens were classified histologically into seven groups as in table 2.

**Table 2**

Histopathological classification of testicular biopsies

Pattern	Score	No of patients
1) Normal spermatogenesis.	10	16
2) Hypospermatogenesis.	9,8	28
3) Round spermatid maturation arrest.	6,7	33
4) Spermatocytes maturation arrest.	4,5	21
5) Sertoli cell only.	2	15
6) No germ cells no sertoli cells.	1	1
7) Mixed pattern.	--	10

These seven groups were defined as follows:

1) Normal spermatogenesis.

Normal spermatogenesis is characterized by full spermatogenesis in the entire biopsy and the presence of a normal inter-tubular presence of all cell types; spermatogonia, Sertoli, Leydig cells, spermatocytes, round spermatids, late spermatids, elongated spermatid and sperm.

2) Hypospermatogenesis.

All stages of spermatogenesis were present but reduced to varying degrees. This group was characterized by highly reduced number of elongated spermatid and/or sperm but still have full spermatogenesis in all examined tubules.

3) Round spermatid maturation arrest.

Spermatogenesis was arrested at round spermatid phase, seminiferous tubules showing spermatogonia, spermatocytes. The development ended with round spermatids. The zone of spermatogenesis (tubule lumen) was narrower than in normal spermatogenesis.

4) Spermatocyte maturation arrest.

Seminiferous tubules showing thickness in the walls and the dominant cell types were spermatogonia, primary spermatocytes and secondary spermatocytes. Zone of spermatogenesis can hardly be seen in most tubules.

5) Sertoli cell only syndrome.

Thickening of the tubules wall was more clear than in spermatocytes maturation arrest and no germ cells were observed (complete germ cell aplasia). All tubules showed the same pattern.

6) No germ cells no Sertoli cells.

These biopsies were characterized by extensive intratubular and peritubular hyalinization with an absence of germ and Sertoli cells. Normal tubules were not prominent.

7) Mixed pattern.

This group contained all mixed patterns phenotypes which contain two or three testicular patterns in the same testicular biopsy and no specific phase dominated.

## DISCUSSION

The incidence of male infertility and the subsequent histological findings in testicular biopsies differ significantly from one part of the world to another due to several underlying etiological factors including social habits, genetic causes and environmental conditions such as underlying infections, chemicals, radiation and exposure to heat (12; 13).

Although a basic male infertility evaluation requires a comprehensive history and physical examination along with semen analysis, testicular biopsy remains the key investigation for all testicular causes of infertility (14).

Testicular biopsy is gaining more value as it can provide valuable information to the urologist and/or andrologist by further categorizing men with azoospermia for purposes of diagnosis, prognosis and treatment (3).

Currently, there is no agreement on systemic reporting of testicular biopsies. Terms used are not standardized and are often subjective with vague terms. The most commonly used histopathological classification of testicular biopsy depends on the presence and the amount of spermatogenesis, maturation of germinal cells and presence of associated tubular atrophy, interstitial fibrosis and Leydig cell hyperplasia (15; 16).

In the present study the frequency of different testicular phenotypes in TESE-ICSI patients and the cut of ratio of mature sperm retrieval in Egyptian azoospermic men were evaluated.

Eighty six representing (69%) of Egyptian males got bilateral and 38 (31%) unilateral testicular biopsies taken for histopathological examination and six of these bilateral biopsies (7%) showed a discordant pattern.

The most common finding in this study was round spermatogenic arrest representing 33 patients (27%) followed by hypospermatogenesis with 28 patients (22%).

The present results showed agreement with some International studies and discrepancies with others and these results are compared as follow:

Normal spermatogenesis accounted for 13% out of the total number of samples studied. The azoospermia in these patients was confirmed to be of post-testicular obstructive etiology. This is almost similar to the result obtained by Nagpal et al. reporting 16%. (17), and Haddad et al., at Jordon who reported 11.2% for obstructive azospermia (18).

Few studies reported lower frequency for the normal spermatogenesis group, 5% (19). Other studies reported higher incidence of Brannen and Roth reported (35%) (20). Al-Rayess and Al-Rikabi (2000) in Saudia both denoted a frequency of 35% of normal spermatogenesis. Rashed et al (2007), from Egypt reported a normal spermatogenesis in 24% of patients. The difference between the present study and that of Rashed group could be due to their small sample size (50 patients) and their grouping of patients as they considered scores 10 and 9 as normal, while in the present study, score 10 was considered normal and 9 was considered as hypospermatogenesis.

**Hypospermatogenesis:** Twenty two percent (22%) of the samples showed patterns of hypospermatogenesis. This result was similar to that obtained by Brannen and Roth (1979) but higher than that of Rashed et al (8%) results and Thomas at the Nigerian male infertility center (19%). On the other hand the incidence of hypospermatogenesis in this study was considerably lower when compared to other studies; such as those of Haddad et al from Jordan reporting 55.8% (18), and Meinhard et al (1973) reporting 46% for the same group (19).

**Spermatogenic arrest:** In the current study, spermatogenic arrest tissue samples were further subdivided into two groups: round spermatid maturation arrest and spermatocytes maturation arrest. These phenotypes may be caused by genetic etiologies including trisomy, balanced autosomal anomalies (translocations, inversions) or deletions in the Y chromosome (Yq11) AZF and DAZ genes. Secondary

factors for spermatogenetic arrest could be toxic substances (radiotherapy and chemotherapy), heat or general diseases (liver or renal insufficiency, sickle cell anemia (20;21).

All tissue samples showing spermatogenic arrest represented 44% which was the highest incidence compared to all the earlier studies. The round spermatid maturation arrest group represented 27% of the studied tissues and spermatocytes maturation arrest group represented 17 %. Spermatogenic arrest at spermatogonia stage was not detected in this study. Rashed et al (2007) reported spermatogenic arrest as a whole at a frequency of 28% in Egyptian males , Brannen and Roth (1979 )denoted (12.5%) in United States , Al-Rayess and Al-Rikabi (2000) concloded (11%) for soudian community and Thomas (1990) reported (5%) in Nigeria while Haddad et al (2004) reported a very low incidence of spermatocyte maturation arrest (1.7%) in Jordon. On the other hand, Glina et al (2005) reported a higher incidence compared to mentioned studies (37.5%) in Brazil (22), but yet lower than the present results.

Sertoli cell only represented 12% of the tissue samples. This result was low compared to the 34% noted by M. Rashed et al (23), and other countries studies such as a 9% value by Thomas cases (24), 12.5% in Brannen and Roth study (20). Haddad et al (2004) recorded a very low incidence for SCOS which was; 2.9% (18). SCO may result from numerous causes, such as cryptorchidism, cytotoxic drugs, or irradiation. However, in many cases the etiology is unknown. The absence of germ cells may be due to factors present during fetal life (25).

The No germ cells no sertoli cells group was represented by a low percentage (1%) compared to the 6% reported by Rashed et al (23), and by Al-Rayess and Al-Rikabi (26). On the other hand, a high incidence of 28.4% was reported in Haddad et al study (18), and 23% in Thomas study (1999).

In the Mixed pattern group of the present study all mixed patterns detected in the same examined tissue with no dominant phenotype detected across the section tubules were included in one group in a trial to make better understanding for this phenomena. This was detected at a frequency of 8%. This mixed profile may be due to some genetic factors related to gene expression, gene regulation and interaction with other environmental factors. More studies and larger number of samples are needed to solve the many questions raised from this heterogeneity in the same tissue.



## CONCLUSION

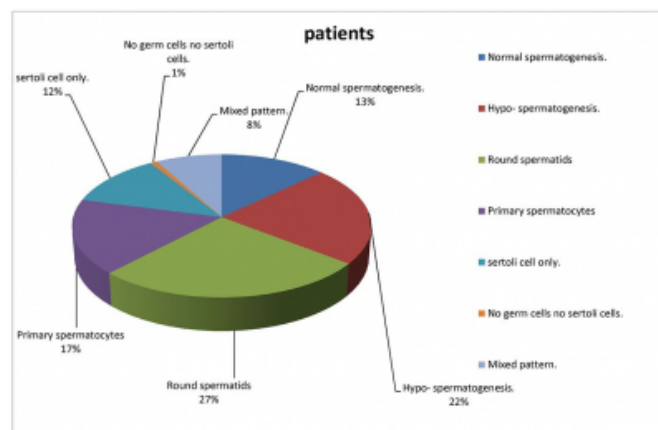
Testicular biopsy is critical in determining a diagnosis of the testicular causes of azoospermia, reproductive prognosis and therapeutic considerations for azoospermic men.

In this respect, testicular biopsy is gaining more value as a golden standard tool for differential diagnosis and for the recovery of mature sperm from men presented with either non-obstructive or obstructive azoospermia and opting for ICSI treatment to conceive.

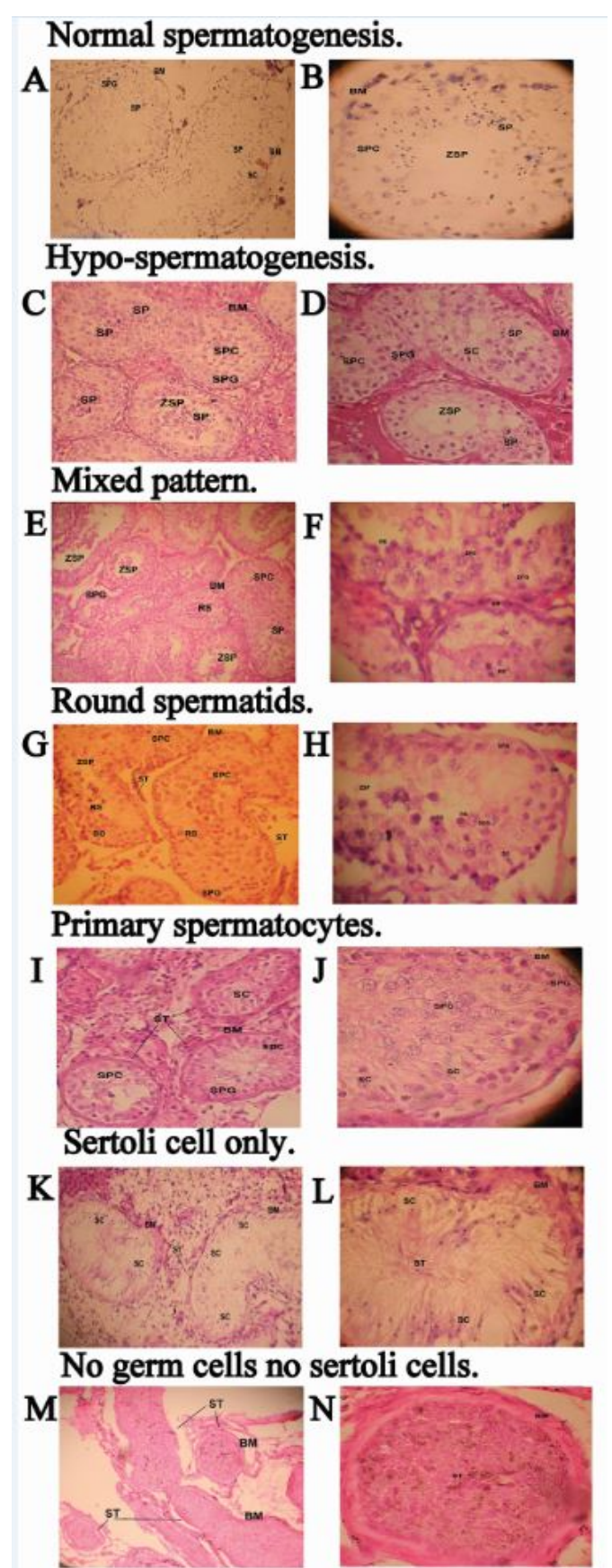
These results revealed that the chance of retrieving a mature sperm for ICSI procedure in Egyptian community represents 40% of the subjected patients. This may be a guideline for clinicians as a success ratio for retrieving mature sperm from TESE procedure.

Further understanding of the molecular and genetic factors, their interaction with other environmental factors and the association of all this complex with the testicular pattern and stage of spermatogenic arrest are strongly needed to solve the mystery of testicular function and dysfunction. This is a must for better classification, diagnosis, prognosis and treatment of men presented with non-obstructive azoospermia.

### Figure 1



## Figure 2



## ACKNOWLEDGEMENTS

Special thanks to all lab team in (Al-Kamal Hospital for Fertility Care and Assisted Fertilization, Cairo, Egypt.), grateful thanks to Dr. Ahmed Ibrahim Amin assistant professor of Embryology and Comparative anatomy Faculty of science, Cairo University, Miss Doaa Samir teaching assistant Biochemistry department faculty of science, Cairo University, and biotech lab7 team (Biotechnology program, faculty of science, Cairo University).

## References

- 1- Dolores DM and Cheng Y : Sertoli-Sertoli and Sertoli-Germ Cell Interactions and Their Significance in Germ Cell Movement in the Seminiferous Epithelium during Spermatogenesis; *Endocrine Reviews* 25 (5): 747-806 August 9, 2004.
- 2- Ahmet Gudeloglu and Sijo J Parekattil (2013). Update in the evaluation of the azoospermic male Clinics (Sao Paulo). 2013 February; 68(Suppl 1): 27–34.
- 3- Lisa A. Cerilli, MD; Wayne Kuang, MD; David Rogers, MD 2010. A Practical Approach to Testicular Biopsy Interpretation for Male Infertility. *Arch Pathol Lab Med*. 2010;134:1197–1204).
- 4- World Health Organization. WHO Laboratory Manual for the Examination 62 and Processing of Human Semen. 5th edn. Geneva, CH: World Health Organization; 2010.
- 5- Male Infertility Best Practice Policy Committee of the American Urological Association; Practice Committee of the American Society for Reproductive Medicine. Report on optimal evaluation of the infertile male. *Fertil Steril*. 2006; 86(5 suppl):S202–S209.
- 6- Bin Wu, Timothy J. Gelety and Juanzi Shi (2012). Advances in Fertility Options of Azoospermic Men, *Advances in Embryo Transfer*, Dr. Bin Wu (Ed.), ISBN: 978-953-51-0318-9, InTech.
- 7- Esteves, S. C., R. Miyaoka and A. Agarwal, 2011 Surgical treatment of male infertility in the era of intracytoplasmic sperm injection - new insights. *Clinics* 66: 1463-1478.
- 8- Anick De Vos (2000). Intracytoplasmic sperm injection (ICSI). *Human Rproduction*, Vol. 15, (Suppl. 4), pp. 59-64.
- 9- Bancroft JD, Gamble M. (2007). *Theory and Practice of Histological Techniques*. (6 th ed.)
- 10- Johnsen, S.G.(1970) Testicular biopsy score count-a method for registration of spermatogenesis in human testes: normal values and results in 335 hypogonadal males. *Hormones*, 1, 2-25.
- 11- Holstein AF, Schulze W, Davidoff M. Understanding spermatogenesis is a prerequisite for treatment. *Reprod Biol Endocrinol*. 2003;11:107. doi: 10.1186/1477-7827-1-107.
- 12- Lunenfeld B, Steirteghem VA. Infertility in the third millennium: Implications for the individual, family and society: Condensed meeting report from the Bertarelli foundation's second global conference. *Hum Reprod Update* 2004;10:317-26.
- 13- Saradha B, Mathur PP. Effect of environmental contaminants on malereproduction. *Env Tox Pharma* 2006;21:34-41.
- 14- Levin HS. Testicular biopsy in the study of male infertility: Its current usefulness, histologic techniques, and prospects for the future. *Hum Pathol* 1979;10:569-84.
- 15- Nistal M, Paniagua R. Testicular biopsy Contemporary interpretation. *Urol Clin North Am* 1999;26:555-93.
- 16- McLachlan RI, Rajpert-De Meyts E, Hoei-Hansen CE, de Kretser DM, Skakkebaek NE. Histological evaluation of the human testis—approaches to optimizing the clinical value of the assessment: Mini review. *Hum Reprod* 2007;22:2-16.
- 17- Nagpal BL, Manjari M, Kapoor K, Dhaliwal US. Testicular biopsy in cases of male infertility: A retrospective study. *J Indian Med Assoc* 1993;91:171-4.
- 18- Haddad FH, Omari AA, Malkawi OM, et al ; Patterns of testicular cytology in men with primary infertility: any change since the Gulf War *Acta Cytol*. 2004 Nov-Dec;48(6):807-12.
- 19- MEINHARD E, McRAE CU, CHISHOLM GD : Testicular Biopsy in Evaluation of Male Infertility *British Medical journal*, 1973, 3, 577-581.
- 20- Brannen GE and Roth RR. Testicular abnormalities of the subfertile male. *J Urol* 1979; 122: 757.
- 21- Behre HM and Bergmann M ; PRIMARY TESTICULAR FAILURE Chapter 6; November 17, 2003 ; available at <http://www.endotext.org/male/male6/maleframe6.htm>.
- 22- Glina S, Soares JB, Nelson JR et al : Testicular histopathological diagnosis as a predictive factor for retrieving spermatozoa for ICSI in non-obstructive azoospermic patients; *Int Braz J Urol*. 2005; 31: 338-41.
- 23- M Rashed, N Ragab, A Shalaby, W Ragab. Patterns Of Testicular Histopathology In Men With Primary Infertility. *The Internet Journal of Urology*. 2007 Volume 5 Number 2.
- 24- Thomas JO : Histological pattern of testicular biopsies in infertile males in Ibadan, Nigeria. *East African Medical Journal* 1990; 67: 578-584.
- 25- Skakkebaek NE; Giwercman A; de Kretser D : Pathogenesis and management of male infertility *Lancet* v343, n8911 (June 11, 1994):1473.
- 26- Al-Rayess MM and Al-Rikabi AC : Morphologic patterns of male infertility in Saudi patients A University Hospital experience *Saudi Medical Journal* 2000; Vol. 21 (7): 625-628.

**Author Information**

**Mohamed K. Khalifa**

Biotechnology and Biomolecular Chemistry Program, Faculty of Science, Cairo University  
Cairo, Egypt

**Aliaa M. Issa**

Professor of Histology and Histochemistry, Department of Zoology, Faculty of Science, Cairo University  
Cairo, Egypt

**Manal O. El Hamshary**

Department of Molecular Diagnostics and Therapeutics, Genetic Engineering & Biotechnology Inst. Sadat City University  
Sadat City, Egypt  
manshary@hotmail.com

**Kamal Z. Shaeer**

Andrology Department Faculty of Medicine, Cairo University  
Cairo, Egypt