

Hereditary Multiple Gastrointestinal Atresias: A Report Of Three Cases From The Kingdom Of Saudi Arabia

M Farhan Qureshi, M Abdellatif, M Yousuf Al Hindi, G Davis, S Qureshi

Citation

M Farhan Qureshi, M Abdellatif, M Yousuf Al Hindi, G Davis, S Qureshi. *Hereditary Multiple Gastrointestinal Atresias: A Report Of Three Cases From The Kingdom Of Saudi Arabia*. The Internet Journal of Pediatrics and Neonatology. 2013 Volume 16 Number 1.

Abstract

Intestinal atresia is a well-known etiology for bowel obstruction in the neonatal period. Hereditary multiple Intestinal Atresia (HMIA) and Severe Combined Immunodeficiency Syndrome (SCID) are the two rare conditions related to intestinal atresia. In this paper, an interesting report on three Saudi siblings affected with unusual pathologies of multiple gastrointestinal atresias is presented. The parents of these infants are first cousins free of any visible genetic disorder. Clinical history and the anomalies found in these siblings suggest possibility of a congenital immunodeficiency syndrome. Infants succumbed to overwhelming sepsis despite clinical intervention

INTRODUCTION

Hereditary multiple intestinal atresia (HMIA) is the rarest form of multiple intestinal atresia with a presumed autosomal recessive mode of inheritance. HMIA is a well-known cause of bowel obstruction in neonates. The condition may involve any part of the gastrointestinal tract. However; the small bowel is the most commonly affected. Symptoms and clinical findings in the newborn include distended abdomen, epigastric mass, recurrent bilious emesis, and failure to pass meconium and jaundice (Dalla et al., 1998). Although the treatment option involves surgical interventions, diagnosis to reach the site plays a major role. Most of the Intestinal atresias are discovered before birth by a routine sonogram, which show a dilated intestinal segment due to the obstruction or due to polyhydramnios. These abnormalities are indications that the fetus may have a bowel obstruction (http://en.wikipedia.org/wiki/Intestinal_atresia). The present study is a report of 3 sisters of a common descent from consanguineous marriage of a couple who are first cousins. The setting of the study was Armed Forces Hospital. The similarity of the cases was that all suffered congenital HMIA with immune deficiency and had a normal karyotype. The first child died at the age of 4 months while second and third died at the ages of 1 and 10 months respectively. There was a variance in the period (34-36 weeks) of gestation when they were born and in their birth weight (1800 to 2600 gram). The point of interest observed was that despite the common descent, identical etiology,

pathology and care, there was diversity in survival time. Moreover, the observation HMIA and SCID in 3 siblings from the same parents was a unique finding, hence, it was found worthwhile to present the scenario of clinical maneuvers and the outcome.

CASE REPORTS

Case 1

A girl was the first child born to the family at 34 weeks gestation. The pregnancy was complicated by polyhydramnios. Birth weight was 1800 grams. After birth the baby developed abdominal distension. An abdominal radiograph showed air in the dilated stomach with no air beyond the antral region. Barium enema demonstrated obstruction at the level of the caecum. At laparotomy the entire small bowel was atretic except for few centimeters. Resection of the atretic bowel was carried out followed by ileostomy. Post operatively the bowels remained non-functioning. Total parenteral nutrition was maintained. The data on immunodeficiency pointed to low number of circulating T-cells, B-cells and NK cells the lymphocytic count of below 500/mm. Cytological analysis revealed normal chromosomes. At the age of four months, the child succumbed to septicemia.

Case 2

A female infant born at 34 weeks of gestation was the second child of the family. Antenatal scan showed distended stomach with normal amniotic fluid. Birth weight was 2300

grams. An abdominal radiograph was consistent with proximal bowel obstruction. Gastrograffin enema showed large bowel obstruction. Echocardiogram showed large ventricular septal defect. At laparotomy multiple atresias were found in the jejunum and ileum. Resections of the severely atretic jejunum and ileum were carried out followed by jejunostomy and ileostomy. Total parenteral nutrition was maintained. The data on immunodeficiency pointed to low number of circulating T-cells, B-cells and NK cells. The absolute neutrophil count at the time of sepsis was only 450/mm. Cytological analysis revealed normal chromosomes. The infant died at the age of one month following *serratia marcescens*

Case 3

The sister of the two siblings was the third of the family and born at 36 weeks of gestation. Antenatal scan showed dilated stomach with normal amniotic fluid. Birth weight was 2600 grams. She was noted to have distended abdomen with an epigastric mass at birth. An abdominal radiograph demonstrated distension of the stomach with no air in the distal intestine. Contrast studies showed no passage beyond pylorus of the stomach or the rectum. She underwent laparotomy on day two of life and was found to have duodenal membrane with duodenal and jejunal atresia. Two sections of ileum were atretic. The ascending and transverse colon were also atretic. The descending colon and sigmoid colon contained multiple intraluminal diaphragms and the rectum was atretic. Resection of the atretic bowel followed by multiple anastomoses and ileostomy was carried.

Attempts to feed her were unsuccessful. Subsequent contrast studies showed ongoing obstruction between the duodenum and jejunum. She underwent further resections at the age of 2 months. At the age of 3 months, a gastrojejunal tube was inserted but attempts to feed her failed. At the age of 4 months, she developed *klebsiella* sepsis. At this time the patient was transferred to Great Ormond Street Hospital in London. Immunologic evaluation showed low T, B and NK cells (CD3 90/UL, CD4 80/UL, CD19 130/UL), with low immunoglobulins (IgG 2.9 g/L, IgM 0.1 g/L, IgA 0.17 g/L). In light of her severe immunodeficiency state prophylactic antifungal, antibacterial, and antiviral medications were started. Strict protective isolation precautions were undertaken. Abdominal ultrasound confirmed multiple dilated small bowel loops. She was noted to have dilated bowel loops with debris in them. Since then she developed recurrent culture negative fever associated with raised C-reactive protein for which she was treated with broad spectrum antibiotics. Parainfluenza 2 was also found to grow

in the nasopharyngeal aspirate. Subsequently she had increasing abdominal distension compromising her chest movement with resultant tachypnea. An ileal drain was inserted to relieve the abdominal distension. Fluid from the ileal drain and stoma swabs grew *pseudomonas*. During this time she had ongoing poor weight gain and failure to thrive. A liver biopsy performed (because of high direct bilirubin) revealed portal fibrosis and minimal inflammation of the portal tracts with no evidence of cirrhosis. Interestingly the jaundice improved after insertion of the ileal drain. The only potential cure for the patient was to consider performing a bone marrow transplant to correct the immune system and minimize the inflammatory process in the gut. The patient went for unrelated cord blood transplant to correct the immunodeficiency. Unfortunately the isolated loops of bowel between the atretic segments acted as a sump of infected material, particularly the multiple resistant *pseudomonas* species. In the post-transplant period, the *pseudomonas* species invaded the blood stream and the patient died of septicemia after a long struggle to live for 10 months.

DISCUSSION

There are many cases of HMIA in siblings from non-consanguineous parents (Moreno et al., 1990, Pumberger et al., 2002; Moore et al., 1996). Although, Gungor et al., (1995) reported two cases from a consanguineous couple, this is perhaps the first report of an association of HMIA and immunodeficiency in 3 siblings from consanguineous parents. Familial occurrence in these cases suggests the inheritance type to be autosomal recessive (Pumberger et al., 2002).

At laparotomy a sizeable small bowel atretic in sibling 1 was resected. At the age of four months, the child succumbed to septicemia. Immunodeficiency was evident from the low lymphocyte count. Extensive atresia coupled with immunodeficiency and septicemia were the visible signs of death. An association of HMIA and immunodeficiency is a known cause of septicemia (Rothenberg et al., 1995; Moore et al., 1996). Literature reports confirm HMIA is invariably non-curable and fatal (Shen-Schwarz and Fitko, 1990). However, the case 1 child survived for a total duration of 120 days, while the mean survival time in most HMIA and immunodeficiency cases was 50-52 days (Chou et al., 2002; Bilodeau et al., 2004).

Multiple atresias were found in the jejunum and ileum at laparotomy in sibling 2. One point of difference between sibling 1 and sibling 2 was that the latter's echocardiogram

revealed a ventricular septal defect. In an earlier report, Chehab et al., (2007) reported consanguinity as the risk factor for association of congenital anomalies of the gastrointestinal tract with congenital heart disease. Immunodeficiency was evident from low number of circulating T-cells, B-cells and NK-cells. The absolute neutrophil count at the time of sepsis was only 450 mm. Obstructions in proximal bowel and large bowel in addition to severe atretic jejunum and ileum coupled with large ventricular septal defect, immunodeficiency and an onset of *Serratia marcescens* were the visible signs of death. Literature reports confirm HMIA is invariably non-curable and fatal (Shen-Schwarz and Fitko, 1990). However, the survival of case 2 child for a total duration of 30 days, much less than the observation in case 1 (4 months) of our study and the mean survival time (50-52 days) in most HMIA and immunodeficiency cases (Chou et al., 2002; Bilodeau et al., 2004). The difference is attributed to the observation of a large ventricular septal defect and onset of *Serratia marcescens* in sibling 2.

In addition to HMIA, there was SCID as revealed by low T, B and NK cells (CD3 90/UL, CD4 80/UL, CD19 130/UL), with low immunoglobulins (IgG 2.9 g/L, IgM 0.1 g/L, IgA 0.17 g/L) in sibling 3. The child developed klebsiella sepsis at the age of 4 months, despite of all prophylactic measures and protective isolation precautions taken. The microscopic findings in surgical material from the small intestine (Plate 1) of sibling 3 showed sieve like multiple lumina, each surrounded by its own separate mucosa and muscularis mucosa but with a common muscularis coat at the periphery. The mucosa was ulcerated in some areas. In the present study marked inflammatory changes were noticed in the caecum (Plate 2) with high magnification image showing acute inflammatory infiltrate mostly lymphocytes with scattered eosinophils and neutrophils. The histological observations on bowel details of present study corroborate with reports available in the literature (Teja et al., 1981; Arnal-Monreal et al., 1983; Puri et al., 1985).

Figure 1

Plate 1: Transverse section of the jejunum showing sieve like multiple lumina.

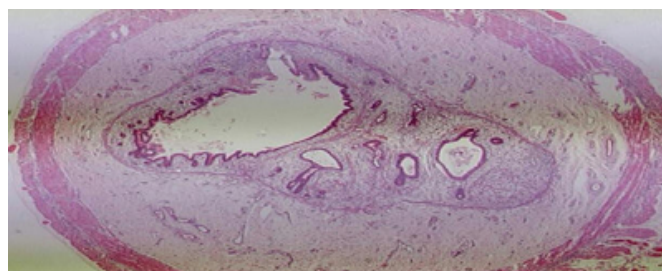
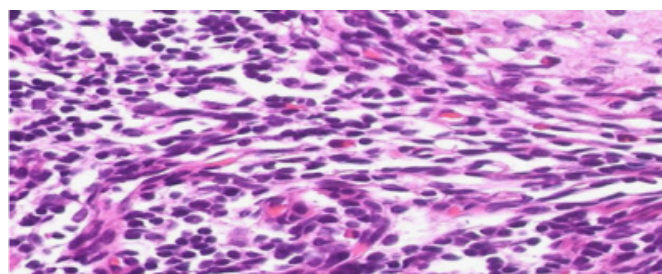


Figure 2

Plate 2: Transverse section of the caecum showing inflammatory changes



Although surgical procedures and anastomoses were carried out, it was difficult to control the immunodeficiency state which rendered the baby develop comorbidities. Previous studies have shown excellent results for bone marrow transplants for neonatal SCID (Buckley et al., 1999). In our patient there was a potential possibility of correcting the immune system by bone marrow transplant. Hence, to minimize the inflammatory process in the gut, unrelated cord blood transplant was undertaken to correct the immune system. Nevertheless, the isolated loops of bowel between the atretic segments acted as a sump of pseudomonas species, which invaded the blood stream and the patient died of septicemia after a long struggle to live for 10 months. In view of the fact that the mode of inheritance of HMIA (autosomal recessive and SCID (X-linked recessive) are different, the observed intestinal anomalies might be related to immune dysfunction. The link between intestinal anomalies and the immune deficiency has been adequately described in the literature (Cole et al., 2010; Chen, 2009). Our observation on septicemia in the three siblings is supported by literature reports on the association of immunodeficiency and HMIA (Moreno et al., 1990; Rothenberg et al., 1995). No real improvement has been made in the treatment or outcome of this pathology. The disorder has been uniformly lethal, with lack of recovery of

bowel function even in those patients in whom resection was performed (Puri et al., 1985).

The mode of inheritance in all the three cases was of familial occurrence (Pumberger et al., 2002) and an association of HMIA and SCID, is invariable lethal (Moreno et al., 1990; Yasser et al., 2011) and is reckoned to be Autosomal recessive. Although, the karyotype was normal, implication of genetic analysis could not be hypothesized in the absence of a thorough genetic analysis.

CONCLUSION

The present report suggests that in the presence of multiple gastrointestinal atresias, attention should be directed to possible immunological disorders and a need for prenatal diagnosis is warranted in future pregnancies. Thorough genetic evaluation would define etiology and proper surgical and therapeutic interventions.

CONSENT

Consent was obtained from the parents of the patients for publication of this case report and any accompanying images. The same is preserved in hospital records

References

- Chen K: A familial Case of Hereditary Multiple intestinal Atresia with Immunodeficiency. Primary Immunodeficiency Disease Consortium Conference; 11 June 2009, San Francisco (CA).
- Arnal-Monreal F, Pombo F, Caodevila-herta A: Multiple hereditary gastrointestinal atresias: Study of a family. *Acta Pediatr Scand*; 1983; 72: 773-777.
- Bilodeau A, Prasil P, Cloutier R, Laframboise R, Meguerditchian AN, Roy G, Leclerc S, Peloquin J: Hereditary multiple intestinal atresia: thirty years later. *J. Pediatr Surg*; 2004; 39: 726-730.
- Buckley RH, Schiff SE, Schiff RI, Louise Markert M, Williams LW, Roberts JL: Hematopoietic stem-cell transplantation for the treatment of severe combined immunodeficiency. *N Engl J Med*; 1999; 340: 508-516.
- Chehab G, Fakhoury H, Saliba Z, Issa Z, Faour Y, Hammoud D, El-Rassi I: [Congenital heart disease associated with gastrointestinal malformations]. *J Med Liban*; 2007; 55: 70-74.
- Chou MM, Tseng JJ, Ho ES, Peng HC: In utero sonographic findings in a fetus with a hereditary multiple intestinal atresia. *Zhonghua Yi Xue Za Zhi (Taipei)*; 2002; 65: 131-134.
- Cole C, Freitas A, Clifton MS, Durham MM: Hereditary multiple intestinal atresias: 2 new cases and review of the literature. *J. Pediatr. Surg*; 2010; 45:2292.
- Dalla VLK, Grosfeld JL, West KW: Intestinal atresia and stenosis: a 25-year experience with 277 cases. *Arch Surg*; 1998; 133: 490-496.
- Gungor N, Balci S, Tanyel FC, Gogus S: Familial intestinal polyatresia syndrome. *Clin Genet*; 1995; 47: 245-247. http://en.wikipedia.org/wiki/Intestinal_atresia
- Moore SW, de Jongh G, Bouic P, Brown RA, Kirsten G: Immune deficiency in familial duodenal atresia. *J. Pediatr Surg*; 1996; 31: 1733-1735.
- Moreno LA, Gottrand f, Turck D, Manouvrier-Hanu S, Mazingue F, Morisot C, Le Deist F, Ricour C, Nihoul-Fekete C, Debeugny P: Severe combined immunodeficiency syndrome associated with autosomal recessive familial multiple gastrointestinal atresias: study of a family. *Am J Med Genet*; 1990; 37: 143-146.
- Pumberger W, Birnbacher R, Pomberger G, Deutinger J: Duodeno-jejunal atresia with volvulus, absent dorsal mesentery, and absent superior mesenteric artery: a hereditary compound structure in duodenal atresia? *Am J Med Genet*; 2002; 109: 52-55.
- Puri P, Guiney EJ, Carrol R: Multiple gastrointestinal atresias in three consecutive siblings: Observation of pathogenesis. *J Pediatr Surg*; 1985; 20: 22-24.
- Rothenberg ME, White FV, Chilmoneczyk B, Chatila TA. Immunodeficiency; 1995; 5: 171-178.
- Shen-Schwarz S, Fitko R: Multiple gastrointestinal atresias with imperforate anus: pathology and pathogenesis. *Am J Med Genet*; 1990; 36: 451-455.
- Teja K, Shnatterly P, Shaw A: Multiple intestinal atresias: Pathology and pathogenesis. *J Pediatr Surg*; 1981; 16: 194-199.
- Yasser AHA, Sajjad R, Venkatraman B, Sheikha AT, Adel I, Ibrahim B: Hereditary multiple intestinal atresia (HMIA) with severe combined immunodeficiency (SCID): a case report of two siblings and review of the literature on MIA, HMIA and HMIA with immunodeficiency over the last 50 years. *BMJ Case Reports*; 2011; 05: 3031.

Author Information

Mohammad Farhan Qureshi

Division of Neonatology, Department of Pediatrics, Prince Sultan Military Medical City
Riyadh, Saudi Arabia

Mohammed Abdellatif

Sultan Qaboos University Hospital
Muscat, Oman

Mohamed Yousuf Al Hindi

Division of Neonatology, Department of Pediatrics, North West Armed Forces Hospital
Tabuk, Saudi Arabia

Graham Davis

Great Ormond Street Hospital
London, UK

Shoeb Qureshi

College of Medicine, Salman Bin Abdulaziz University
Alkharj, Saudi Arabia