

Reduction Of Surgical Site Infections In Colorectal Surgery By The Combined Use Of Absorbable Subcuticular Staple Closure And Silver Nylon Dressings: A Retrospective Review Comparing To Percutaneous Metal Staples With Gauze Dressings

S M Cohen

Citation

S M Cohen. *Reduction Of Surgical Site Infections In Colorectal Surgery By The Combined Use Of Absorbable Subcuticular Staple Closure And Silver Nylon Dressings: A Retrospective Review Comparing To Percutaneous Metal Staples With Gauze Dressings*. The Internet Journal of Surgery. 2014 Volume 32 Number 1.

DOI: [10.5580/IJS.15339](https://doi.org/10.5580/IJS.15339)

Abstract

Background

Surgical site infections (SSI) significantly impact patient morbidity, extend hospital stays, increase readmissions, and may ultimately lead to death. Reported 30 day SSI rates of 18% and readmission rates of 12% in colorectal surgery are not unusual. The Surgical Care Improvement Project and other preventive disciplines are promising, but arguably have had little effect to date. The need remains for new methods to substantially decrease the rate of SSI and readmissions to improve outcomes and reduce costs in colorectal surgery. Innovative surgical technologies are available that may have potential to decrease the rate of SSI in colorectal surgery. A novel subcuticular absorbable staple and a high silver content nylon dressing were used in combination to explore a potential influence on the incidence of SSI.

Methods

Thirty consecutive colorectal surgery patients with primary incisions of 3cm or longer were closed with subcuticular absorbable staples and application of a moist silver nylon dressing, and the SSI rate was compared to the prior rate with percutaneous metal skin staples and dry gauze dressing. With the exception of absorbable staples and silver dressing the wound closure procedures were identical and all patients had been examined for infection at discharge and monitored until 30 days after surgery.

Results

Thirty patients with absorbable staples and silver nylon dressing had no surgical site infections occur within 30 days after surgery. This zero incidence of infection compares to a 9% incidence in the retrospective cohort with percutaneous metal staples and dry gauze dressings.

Conclusions

The absorbable staples and silver dressing demonstrated a significant decrease in SSI (9% vs 0%) and patients expressed high satisfaction with wound comfort and appearance. The importance of these results should not be underestimated. The new health care law will begin linking payment with quality of care, outcome improvement, and patient satisfaction. SSI and readmission are "never events" which can lead to zero payment from CMS and other third-party payers. A larger, multi-center, prospective randomized trial is required to identify statistical significance.

BACKGROUND

Surgical site infections (SSIs) substantially impact patient morbidity, extend hospital stay, increases the potential for readmission, and may ultimately lead to death. The annual SSI occurrence in the U.S. is estimated as high as 1 million with an associated cost of \$1.6 billion in excess hospital charges [1]. The reduction of SSI in colon and rectal surgery is an important goal to improve surgical quality. A 30 day SSI rate of 18.8% in colorectal surgery was reported by Wick, et al [2] in a recent claims study of over 10,000 patients. Readmission rates were 11.4% and 23.3% at 30 and 90 days, respectively, with a median cost of an SSI readmission being \$12,835. Efforts to reduce SSI by way of the Surgical Care Improvement Project (SCIP) have had mixed results, despite improved compliance [3]. Hawn, et al [4] assessed the correlation between SCIP adherence and SSI rate and found no association with lower patient or hospital SSI rates and concluded that policies regarding continued SCIP measurement and reporting should be reassessed. These preventive disciplines seem logical and promising, but arguably have had little effect. The need remains for a methods to substantially decrease the rate of SSI and markedly improve clinical outcomes and reduce costs in colorectal surgery.

There are innovative technologies available for use in surgery that present an opportunity for evaluation of their potential to effect a reduction of SSI in colorectal surgery. A novel subcuticular absorbable staple and a silver coated nylon dressing have each been shown individually to influence a reduction in the incidence of surgical site infection; each by different means.

This current retrospective chart review study was undertaken to measure the incidence of SSI in colorectal surgery primary incisions treated with a combination of the subcuticular absorbable staple for skin closure and a silver nylon wound dressing with a high metallic silver content.

METHODS

This study was performed at a single institution as a chart review of thirty consecutive colorectal surgery patients having their primary incisions closed with absorbable subcuticular staples (INSORB®, Incisive Surgical, Inc., Plymouth, MN) (Figure 1.) and dressed with the silver nylon dressing (SILVERLON®, Cura Surgical, Geneva, IL) (Figure 2.). Surgeries were all performed by the author at a single institution during about a six week period (January – February 2013). Patients with incisions of 3cm or longer were included and incisions ranged from approximately 4 cm to 18cm in length depending on the procedure.

Patients in both groups were excluded if they had presented in septic shock or retention sutures were utilized based on surgical judgment. All participants received our standard perioperative antibiotic protocol, including administration 30-60 minutes before surgery and discontinuation within 24 hours. The test subject wound closure procedures were unchanged from the subjects of retrospective SSI rate with the exceptions of the skin closure with INSORB subcuticular absorbable staples instead of percutaneous metal staples, and a SILVERON dressing applied in place of a dry sterile gauze dressing. The SILVERON dressing was hydrated and applied at surgery and hydration was maintained through the hospital stay. The dressing was replaced at the time of discharge and then removed and discontinued at the 7-10 day follow-up examination.

Patients in this study and the subjects of the prior overall SSI rate were all treated by the same surgeon at one institution and followed according to the same infection surveillance routine. Metal staples in the prior group were removed between day 7 and 10 in all patients unless there were signs of an active wound infection. Patients were observed for infection throughout the hospital stay by a physician member of the surgical team and examined for infection at their follow-up visit, then surveyed for events in the period until 30 days after the surgical procedure. The infection identification and the follow-up period were in accordance with the Centers for Disease Control and National Health Safety Network criteria and definitions for SSI Infection Surveillance [5].

RESULTS

Thirty consecutive patients are described in Table 1 and are comparable to patients treated previously without absorbable staples and a silver dressing. Results are from the period of 30 days after hospital discharge and there were no surgical site infections reported. This absence of SSI in patients treated with the combination of INSORB staples and SILVERON dressing compares to a retrospective 9% incidence of SSI in patients treated with percutaneous metal skin staples and dry gauze dressings.

DISCUSSION

These innovative modalities of absorbable staples and the silver nylon dressing have each been shown to influence a reduction in the incidence of surgical site infection, and each by different means. The dressing introduces effective antimicrobial silver to the wound by transdermal diffusion

[6,7]. The absorbable staples are a rapid and secure means of wound closure that is comfortable, and appears to be minimally traumatic with very little erythema or swelling. Patients were uniformly pleased with the comfort and appearance of their incisions. The absence of wound infection in these patients with the combination of INSORB staples and SILVERON dressing is understandable when considering the pathogenesis of SSI and the reported reduction of infections with INSORB in studies comparing it to conventional modalities in contaminated wounds [8,9].

Efforts to reduce SSI that address exogenous contamination and modifiable patient risk factors have been successful to a limited degree and yet meaningful rates of SSI persist, especially where wound contamination is likely. Most pathogens leading to SSI are commonly gram-positive cocci present from the patient's own endogenous flora, and the higher the burden of contamination, the greater the risk of infection [10,11]. A given level of contamination such as <105 microorganisms in the presence of the antimicrobial prophylaxis may not cause a SSI, whereas those same or much lower levels of contamination would likely cause SSI in the presence of other known risk factors: prosthetic implants, suture and foreign bodies, injured or compromised tissue, and debris and necrotic tissue [10]. Piñeros-Fernandez, et al [9,12] evaluated contaminated wounds in a porcine model closed with metal staples, continuous braided absorbable suture, and subcuticular absorbable staples. An equal number of wounds were contaminated with 104 and 105 colony-forming units of *S. Aureus*/0.05 mL. Wounds were each isolated with a barrier dressing and evaluated after 7 days without antimicrobial treatment. The statistically significant results demonstrated that the INSORB subcuticular staples had the lowest incidence of infection (33%); followed by percutaneous metal staples (44%), and all braided absorbable (polyglactin 910) suture (100%) were infected. A similar subsequent study by the same researchers [9] included a comparison of continuous monofilament absorbable (poligleccaprone) suture and braided absorbable suture and showed a high rate of infection for both continuous sutures regardless of the biomaterial and structure, 89% and 100% infected, respectively.

The INSORB absorbable subcuticular skin stapler contains 30 absorbable staples, sufficient to close a 21 cm incision. The wound closure is a simple and rapid single-operator technique that places subcuticular absorbable staples horizontally within the dermis at approximately 7mm

intervals to create a secure well approximated and everted closure (Figure 3.). The staples are comprised of a polylactide-polyglycolide co-polymer that breaks down by hydrolysis with substantial absorption in 10-12 weeks and with minimal inflammatory response [8,9,13]. The absorbable staples are a non-continuous interrupted modality that secures the wound without the trauma of percutaneous injury or tissue strangulation and compression of suture and metal staples that are thought to increase the risk of infection, poor healing, and other complications. The interrupted subcuticular staples allow immediate postoperative drainage and eliminate the risk of communication and contamination along a continuous suture line. Studies have shown absorbable staple closures to be secure, comfortable, and cosmetic, with a reduced risk of infection compared to suture and metal staples [8,9,14]. Patients reported their incisions closed with absorbable staples were comfortable and pleasing in appearance (Figure 4.). Nitsche, et al [15] compared cesarean incisions closed with metal staples and INSORB staples and found that patients with the INSORB closure had less pain, indicated by a 1.5 fold reduction in their requests for ketorolac during the in-hospital postoperative course.

If it becomes necessary to partially open the wound postoperative, then the interrupted staples can be safely cut individually with a heavy scissors. The staple remnants are left in place without consequence. These wounds were low maintenance and without the inconvenience and discomfort of staple removal. The INSORB® stapler is a sharps safe device without the risk of suture-associated needlesticks. It complies with the Needlestick Safety and Prevention Act as a U.S. OSHA-defined SESIP device (Sharps with Engineered Sharps Injury Protections).¶ At a cost of \$48 the better outcomes can account for significant savings, mostly by way of the reduction of readmissions or outpatient treatment associated with wound infections.

The Silveron silver nylon dressing is a simple and straight forward intervention with very little if any additional wound or dressings care on the floor. The dressing is hydrated with sterile water and applied at surgery and then hydrated daily during the hospital stay, per product instructions. The duration of effect is 7 days. When silver ionizes in contact with a wound and bodily fluids, it has a broad spectrum and devastating antimicrobial effect that is well understood [6]. Kreiger B, et al [7] showed a surgical site infection reduction from 33% to 13% comparing the Silveron dressing to a

Reduction Of Surgical Site Infections In Colorectal Surgery By The Combined Use Of Absorbable Subcuticular Staple Closure And Silver Nylon Dressings: A Retrospective Review Comparing To Percutaneous Metal Staples With Gauze Dressings

control group in colorectal surgery. The cost of the dressing ranges from \$24-\$96 depending on size. This is can be greatly recovered by the reduction of costs associated with surgical site infections.

The absorbable staple closure modality permits surgeons to no longer concede to accepting the limitations of either interrupted percutaneous metal skin staples or running subcuticular suture for wound closure. The absorbable staple is a fast interrupted closure with the comfort and cosmesis of absorbable suture. Since the results of this study have been so dramatic, the primary surgeon has continued the use of INSORB staples and SILVERLON dressing in every segmental colectomy. Furthermore, the patients have been very pleased, happy, and satisfied with the appearance of their wound. In fact, many patient referrals have been identified solely due to the fact the "plastic surgery" closure performs so well and heals with a very small, barely noticeable scar.

The importance of these results should not be underestimated. The new health care law will begin linking payment with demonstrated improvement of outcome, quality of care, and patient satisfaction. One of the 17 "never events" is a wound infection which can lead to zero payment from CMS and other third-party payers. Hospitals and physicians can ill afford to have a preventable complication be the reason for the bankruptcy of an institution.

CONCLUSION

Although the study was not performed in a prospective, randomized fashion, having a single setting and surgeon for the retrospective control and the test groups largely eliminates confounding variables for evaluation of the test materials as an independent variable. The overall retrospective SSI rate for metal staples was lower than benchmark data of >15% [16], however, the end result of utilizing INSORB stapler and SILVERLON dressing still demonstrated a significant decrease in SSI (9% vs 0%). A larger, multi-center, prospective randomized trial will be required to identify statistical significance.

Table 1

Patient characteristic and procedures

Number of Patients, n=	30
Gender	
Male	17
Female	13
Age, years	
Mean	60
Range	24 to 75
Procedure	
Right colectomy	11
Total colectomy	5
Sigmoid resection	5
LAR/colostomy	4
Small bowel resection	3
Low anterior	2
Surgical Site Infection (SSI) during 30 days post operative.	0

ABBREVIATIONS USED:

(SSI) Surgical site infections

(SCIP) Surgical Care Improvement Project

ACKNOWLEDGEMENTS

Funding for data retrieval and manuscript preparation was provided by Incisive Surgical, Inc., Plymouth, MN. We thank James A Peterson, who provided medical writing services on behalf of Incisive Surgical.

Author details

SC is a practicing colon and rectal surgeon at Atlanta Colon & Rectal Surgery.

Figure 1

INSORB Subcuticular Skin Stapler. The stapler contains 30 absorbable staples, sufficient to close a 21 cm incision. The wound closure is a simple and rapid single-operator technique that places subcuticular absorbable staples horizontally within the dermis at approximately 7mm intervals to create a secure well approximated and everted closure. The staples are comprised of a polylactide-polyglycolide co-polymer that breaks down by hydrolysis with substantial absorption in 10-12 weeks and with minimal inflammatory response.

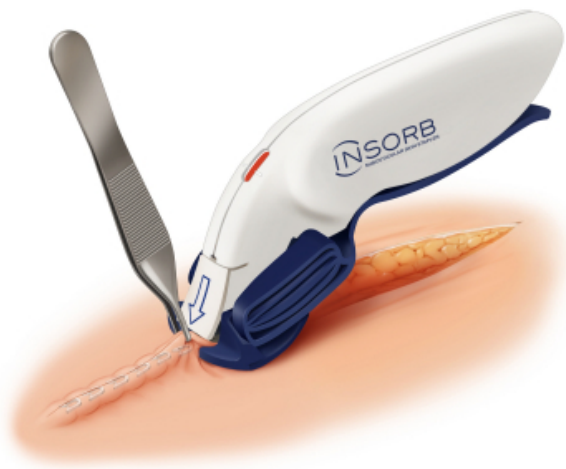

Figure 2

SILVERON Silver Nylon Dressing. The dressing introduces effective antimicrobial silver to the wound by transdermal diffusion. The dressing was hydrated and applied at surgery and hydration was maintained through the hospital stay. The dressing was replaced at the time of discharge and then removed and discontinued at the 7-10 day follow-up examination.



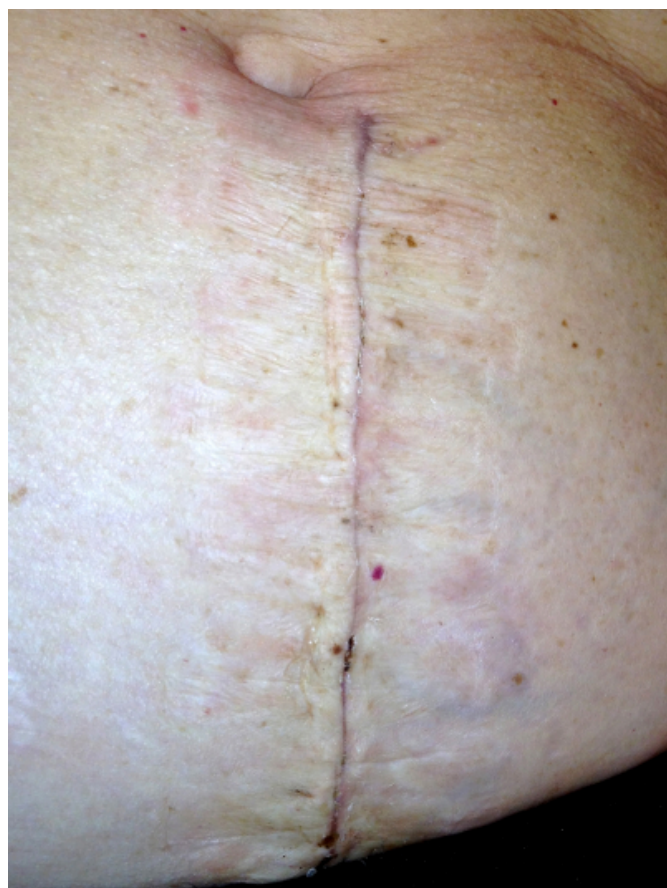
Figure 3

A midline closure with subcuticular staples. The absorbable staples are a non-continuous interrupted modality that secures the wound without the trauma of percutaneous injury or tissue strangulation and compression of suture and metal staples that are thought to increase the risk of infection, poor healing, and other complications. The interrupted subcuticular staples allow immediate postoperative drainage and eliminate the risk of communication and contamination along a continuous suture line. If it becomes necessary to partially open the wound postoperative, then the interrupted staples can be safely cut individually with a heavy scissors. The staple remnants are left in place without consequence. These wounds were low maintenance and without the inconvenience and discomfort of staple removal.

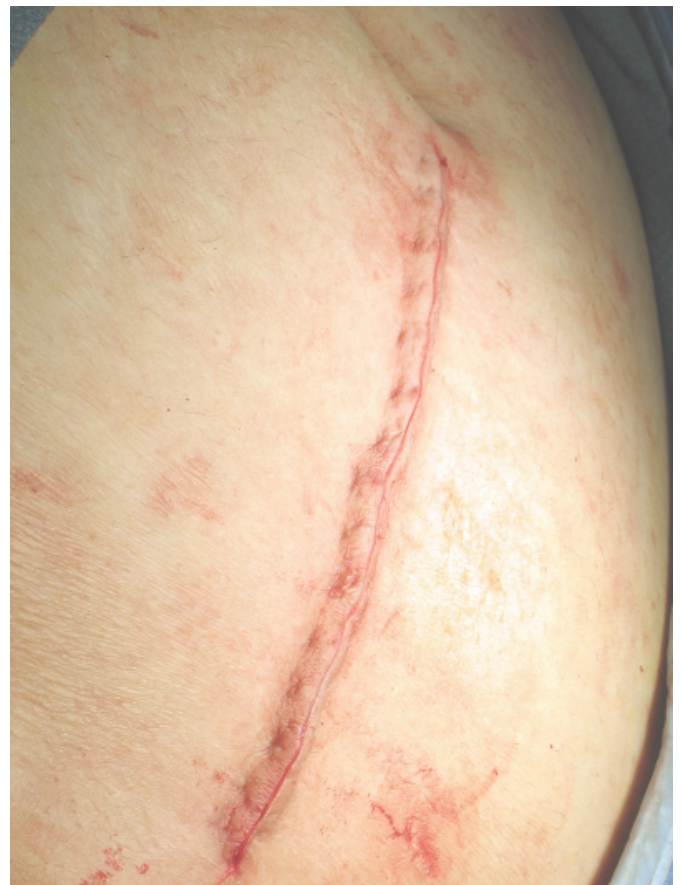

Figure 4

Subcuticular staple closure at 2 weeks. This closure modality appears to be minimally traumatic. These were low maintenance wounds with very little apparent inflammation. Patients reported their incisions closed with absorbable staples were comfortable and pleasing in appearance.



References

1. Bratzler, D. W., Houck, P. M., Richards, C., Steele, L., Dellinger, E. P., Fry, D. E., ... & Red, L. (2005). Use of antimicrobial prophylaxis for major surgery: baseline results from the National Surgical Infection Prevention Project. *Archives of Surgery*, 140(2), 174.
2. Wick, E. C., Shore, A. D., Hirose, K., Ibrahim, A. M., Gearhart, S. L., Efron, J., ... & Makary, M. A. (2011). Readmission rates and cost following colorectal surgery. *Diseases of the Colon & Rectum*, 54(12), 1475-1479.
3. Stulberg, J. J., Delaney, C. P., Neuhauser, D. V., Aron, D. C., Fu, P., & Koroukian, S. M. (2010). Adherence to surgical care improvement project measures and the association with postoperative infections. *JAMA: the journal of the American Medical Association*, 303(24), 2479-2485.
4. Hawn, M. T., Vick, C. C., Richman, J., Holman, W., Deierhoi, R. J., Graham, L. A., ... & Itani, K. M. (2011). Surgical site infection prevention: time to move beyond the surgical care improvement program. *Annals of surgery*, 254(3), 494-501.
5. Horan, T. C., Gaynes, R. P., Martone, W. J., Jarvis, W. R., & Emori, T. G. (1992). CDC definitions of nosocomial surgical site infections, 1992: a modification of CDC definitions of surgical wound infections. *Infection Control and Hospital Epidemiology*, 13(10), 606-608.
6. Lansdown, A. B. G. (2002). Silver I: its antibacterial properties and mechanism of action. *Journal of wound care*, 11(4), 125-130.
7. Krieger, Beth R., et al. The use of silver nylon in preventing surgical site infections following colon and rectal surgery. *Diseases of the Colon & Rectum* 54.8 (2011): 1014-1019.
8. Fick, J. L., Novo, R. E., & Kirchhof, N. (2005). Comparison of gross and histologic tissue responses of skin incisions closed by use of absorbable subcuticular staples, cutaneous metal staples, and polyglactin 910 suture in pigs. *American journal of veterinary research*, 66(11), 2005.
9. Píñeros-Fernandez, A., Salopek, L. S., Rodeheaver, P. F., & Rodeheaver, G. (2012). The Influence of Absorbable Subcuticular Staples, Continuous Subcuticular Absorbable Suture, and Percutaneous Metal Skin Staples on Infection in Contaminated Wounds. *Journal of long-term effects of medical implants*, 22(2).
10. Krizek, T. J., & Robson, M. C. (1975). Evolution of quantitative bacteriology in wound management. *The American Journal of Surgery*, 130(5), 579-584.
11. Houang, E. T., & Ahmet, Z. (1991). Intraoperative wound contamination during abdominal hysterectomy. *Journal of Hospital Infection*, 19(3), 181-189.
12. Piñeros-Fernandez, A., Salopek, L. S., Rodeheaver, P. F., Drake, D. B., Edlich, R., & Rodeheaver, G. T. (2006). A revolutionary advance in skin closure compared to current methods. *Journal of long-term effects of medical implants*, 16(1).
13. Fisher, David A., et al. (2010). A randomized, prospective study of total hip wound closure with resorbable subcuticular staples. *Orthopedics* 33.9 (2010): 665-665.
14. Shibley KA, Biorn J, Brearley AM. 500 consecutive cesarean deliveries closed with subcuticular absorbable Staples. Poster presentation ACOG, 60th Annual Clinical Meeting, May 5-9, 2012, San Diego, CA.
15. Nitsche, J., Howell, C., & Howell, T. (2012). Skin closure with subcuticular absorbable staples after cesarean section is associated with decreased analgesic use. *Archives of gynecology and obstetrics*, 285(4), 979-983.
16. Edwards, J. R., Peterson, K. D., Mu, Y., Banerjee, S., Allen-Bridson, K., Morrell, G., & Horan, T. C. (2009). National Healthcare Safety Network (NHSN) report: data summary for 2006 through 2008, issued December 2009. *American journal of infection control*, 37(10), 783-805.

Reduction Of Surgical Site Infections In Colorectal Surgery By The Combined Use Of Absorbable Subcuticular Staple Closure And Silver Nylon Dressings: A Retrospective Review Comparing To Percutaneous Metal Staples With Gauze Dressings

Author Information

Stephen M. Cohen, MD, MBA, FACS, FASCRS

Atlanta Colon & Rectal Surgery

Marietta, GA

stephencohen615@gmail.com