

Giant Cell Tumor Of The Distal Ulna- A Rare Presentation Treated With Wide Resection And Stabilization Of The Ulnar Stump By The Extensor Carpi Ulnaris

R Sharma, S Gupta, N Saini, V Kakkar, Y Saini, H Singh

Citation

R Sharma, S Gupta, N Saini, V Kakkar, Y Saini, H Singh. *Giant Cell Tumor Of The Distal Ulna- A Rare Presentation Treated With Wide Resection And Stabilization Of The Ulnar Stump By The Extensor Carpi Ulnaris*. The Internet Journal of Orthopedic Surgery. 2013 Volume 21 Number 1.

Abstract

The location of a giant cell tumor (GCT) at the distal end of the ulna is very rare with a reported incidence from 0.45% to 3.2%. Various treatment options have been proposed. En-bloc resection of the distal part of the ulna maintaining extra-lesional margins with or without reconstruction or stabilization of the ulnar stump is the more oncologically advantageous treatment for GCT located in this area. We present one patient with GCT of the distal ulna, treated by wide resection of the distal ulna followed by stabilisation of the remaining ulna using one half of the extensor carpi ulnaris (ECU) tendon.

INTRODUCTION

Giant cell tumour (GCT) of the bone is a rare, benign, locally invasive tumour, accounting for approximately 3% to 5% of all primary bone tumours¹. The location of GCT at the distal end of the ulna is very rare, with a reported incidence from 0.45% to 3.2%.² It generally occurs in adults between the ages of 20 and 40 years. GCT of bone is very rarely seen in children or in adults older than 65 years of age. GCT tumors occur in approximately one person per million per year. Usually, the tumor site is at the long bone meta-epiphysis, especially the distal radius and femur, proximal humerus and tibia.³

Wide resection of the distal ulna with or without reconstruction or stabilisation of the ulnar stump is the recommended treatment for GCTs in such locations.⁴

We present one patient with GCT of the distal ulna, treated by wide resection of the distal ulna followed by stabilisation of the remaining ulna using one half of the extensor carpi ulnaris (ECU) tendon.

The purpose of this report is to present another case with this localization that was treated successfully with resection of a large distal ulnar segment followed by stabilisation of the remaining ulna using one half of the extensor carpi ulnaris (ECU) tendon.

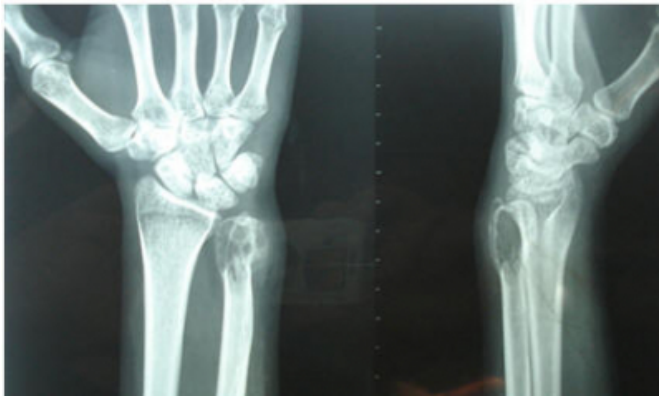CASE REPORT

A 22-year-old Indian female, student by occupation, presented with painful progressive swelling over the ulna aspect of her left distal forearm over the past six months. There was no history of any other swelling in the body, fever, loss of weight or appetite, or history of similar complaints in the past. The family, occupational, recreational and drug histories were not significant. The general physical and systemic examinations were within normal limits. On examination, there was a diffuse oval swelling of the distal left forearm along the ulnar aspect measuring 6 x 4 cm. The mass was firm in consistency and tender with normal overlying skin and temperature. The overlying skin was of normal colour and temperature. There was no overlying scar, sinus or prominent veins. It was free from the overlying skin but adherent to the underlying bone. The range of motion of wrist was normal with supination terminally painful and restricted. The distal neurovascular status was normal and grasping power equal in both hands.

Serum biochemistry studies were within normal limits. Plain radiographs of the left ulna showed an expansile, multiloculated lytic lesion at its lower end with absence of periosteal reaction (Figure 1). Plain chest radiographs showed no evidence of lung metastases.

Figure 1

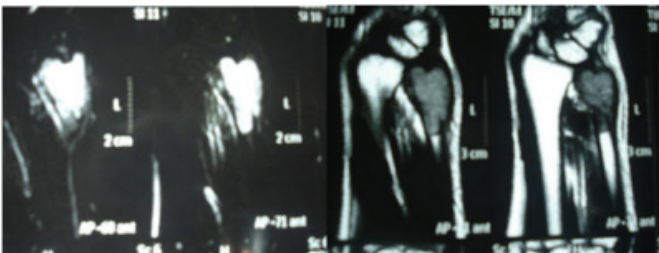
Pre-operative radiographs of GCT of the distal ulna showing osteolytic lesion of distal ulna



MRI STIR images of focal expansile lesion of distal ulna showed homogeneous high-intensity signal in subarticular location. (fig 2a). On T1 weighted the lesion showed loss of normal high signal intensity by hypointense soft tissue signal changes in the distal ulna. (fig 2b) and The lesion also showed marked thinning of the overlying cortex with cortical breach at places.

Figure 2

Fig.2a - MRI of the wrist. STIR images, focal expansile lesion of distal ulna showing homogeneous high-intensity signal in subarticular location 2b — T1 weighted image of the distal forearm showing loss of normal high signal intensity by hypointense soft tissue signal changes in the distal ulna.



A clinical diagnosis of GCT was made, which was confirmed post operatively by histopathological examination. The condition, its prognosis and various treatment

modalities were discussed with the patient. On the basis of clinical and radiographic evaluation, the lesion was graded as Stage 3 (aggressive) as per the Enneking Staging system for benign bone tumors. As per the standard recommendations for Stage 3 lesions, a wide resection was planned after obtaining informed and written consent from the patient. The resection margins were calculated keeping

in view the radiological extent of the lesion. Keeping in view the patient's high functional demands, we also decided to stabilize the ulnar stump using the extensor carpi ulnaris tenodesis technique described by Kayias & Drosos 2. The tumor was exposed (Figure 3) and resection extra-periosteal with 3 cm margin of the normal bone proximal to the tumor. This included approximately half (ten centimetres) of the distal end of the ulna, the triangular fibro cartilage complex, the ulnar border of the pronator quadratus and a part of the distal radio-ulnar joint capsule (Figure 4a). The extensor carpi ulnaris (ECU) tendon was dissected free from the tumor mass by blunt dissection and longitudinally split to a point 1 cm proximal to the cut end of the ulna. The tendon was passed through a 3.2 mm drill hole, 5 mm above the end of the ulnar stump in a dorsal to volar direction with the forearm held in supination. The tendon was then directed to the ulnar side and sutured back on itself (Figure 4b). This manoeuvre resulted in a cuff of the ECU tendon, which effectively stabilized the ulnar stump. The remnant of distal radio ulnar joint capsule was sutured with the ECU tendon in order to prevent ulnar subluxations of the carpus. The wound was closed in layers over a drain. Postoperatively, the forearm was immobilized in supination using an above elbow splint for three weeks, following which physiotherapy was started. The patient was gradually advised full range of motion at the wrist and elbow. Histologically the lesion was a typical GCT composed of numerous osteoclast-like giant cells, interspersed with spindle-shaped stromal cells arranged in a storiform pattern. Mitotic figures were absent. Surgical margins were free of tumour.

Follow-up was carried once every three months for one year. After one year, she had normal function of his left hand without ulnar instability with terminal restriction of forearm supination.

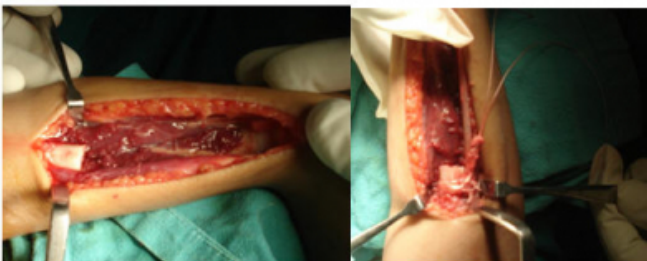
Figure 3

Figure 3 showing operative picture of the tumor mass at the distal end of ulna.

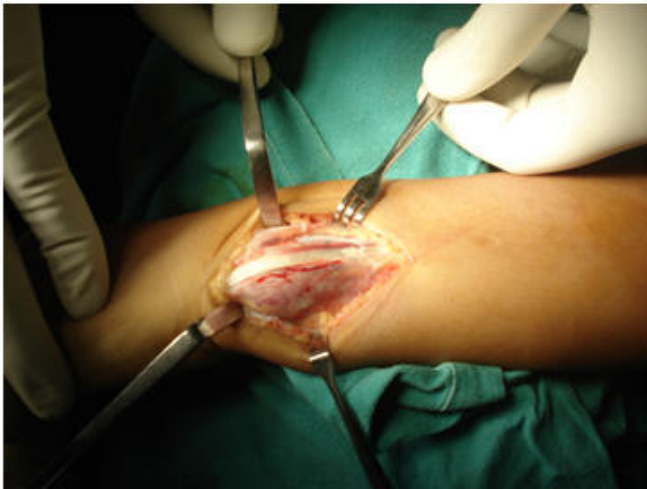

Figure 4

Figure 4a showing operative picture after the wide excision of the tumor mass. Figure 4 b showing ulnar stump stabilization using extensor carpi ulnaris slip.



DISCUSSION

The distal end of ulna is a rare site for primary bone tumors, especially giant cell tumour.

The incidence of distal ulna GCT varies in different reported studies. Harness et al 5 reported an incidence as low as 0.5%, while Campanacci 6 reported a 1.2%. A review of large series of GCT was reported. These studies reported 41 cases of GCT of the distal ulna out of a total of 3222 cases of GCT, with a cumulative incidence of 1.27%. 7, 8

Tumours at this location can be benign, locally aggressive or malignant. The Enneking staging system for musculoskeletal tumours is useful not only for planning the modality of treatment but also for prognostication. Stage 1 lesions require no treatment, Stage 2 lesions can be managed by extended curettage whereas Stage 3 lesions will need a wide excision [3]. As per this system, most GCTs present as Stage 2 or 3 lesions.

Functionally, the distal end of the ulna helps in forearm rotations (supination and pronation), grip strength and in maintaining the relationship between the carpus and the distal end of the radius. The ulnar collateral ligament of the wrist, which emanates from the ulnar styloid process and the triangular fibrocartilage complex (TFCC), plays an important role in the maintaining of this anatomical relationship. 4

The insertion of the pronator quadratus is another important anatomical structure, which can cause problems after distal ulna excision. Resection at a lower level could potentially cause impingement symptoms due to the pull of this muscle, while resection at a higher level causes instability and undue prominence of the ulnar stump. Even the Darrach procedure was criticized for the ulnar stump instability and radio-ulnar convergence leading to pain and clicking during rotatory movements of the wrist in spite of its excellent functional results by achieving painless supination and pronation in patients with DRUJ dysfunction. Many stabilizing procedures such as tenodesis, pronator quadratus muscle transfer, combination of the two, ulnar lengthening osteotomy and ulnar head prosthesis were recommended to avoid these complications. The functional outcome following en bloc resection of the distal ulna without reconstruction has been reported in two studies. Cooney et al 8 have studied the functional outcome in patients with 3 malignant and 5 benign neoplasms of the distal ulna at a mean follow-up of 7.5 years. Wolfe et al 9 have studied the results of distal ulnar resection in 9 patients with pain following DRUJ excision and 3 patients with neoplastic conditions. Both of these studies had concluded that excision of a substantial portion of the distal ulna can be performed without concern for subsequent instability, ulnar translocation of the carpus and radioulnar convergence. 7

Various treatment options have been proposed, including intralesional curettage, curettage and bone grafting, cryotherapy of the cavity after curettage, application of phenol after curettage, radiation, insertion of methylmetacrilate cement in the cavity after curettage, resection followed by allograft, en-bloc resection with or without reconstruction or stabilization of the ulna and prosthetic reconstruction. Of these, en-bloc

resection of the distal part of the ulna maintaining extra-lesional margins with or without reconstruction or stabilization of the ulnar stump is the more oncologically advantageous treatment for GCT located in this area.10

According to Cooney et al.⁸, reconstruction of the osseous defect after resection of a neoplasm of the distal end of the ulna, including GCT, is usually not necessary to maintain function. Similar results were observed by Wolfe et al.⁹ in a multicenter study over wide excision of the distal ulna. However, other authors disagree because stabilization of the distal ulna following large resection, as in our case, can be a significant clinical problem with associated pain and weakness due to a decreased interosseous space with ulnar stump impingement on the radius metaphysis or instability of the radiocarpal joint with ulnar translation of the carpus ^{11, 12}. For this reason, they suggest that soft tissue stabilization of the ulnar stump should be performed whenever possible. ¹⁰

We report another case with this localization that was treated successfully with resection of a large distal ulnar segment followed by stabilisation of the remaining ulna using one half of the extensor carpi ulnaris (ECU) tendon.

CONCLUSION

GCT of distal ulna is a rare entity with no standard modality of treatment. From this case study we conclude that wide resection and stabilization of ulnar stump by extensor carpi ulnaris gives satisfactory functional results.

References

1. McDonald DJ, Sim FH, McLeod RA, Dahlin DC. Giant cell tumor of bone. *J Bone Joint Surg* 1986 ; 68-A : 235-242.
2. Efsthathios H. KAYIAS, Georgios I. DROSOS, Georgia A.

- ANAGNOSTOPOULOU. Resection of the distal ulna for tumours and stabilisation of the stump. A case report and literature review. *Acta Orthop. Belg.*, 2006, 72, 484-491.
3. Daniele Vanni, Andrea Pantalone, Elda Andreoli, Patrizio Caldora, Vincenzo Salini Giant cell tumor of distal ulna: a case report. *Journal of Medical Case Reports* 2012, 6:143.
 4. Manjeet Singh, Siddhartha Sharma, Chetan Peshin, Ifitikhar H Wani, Agnivesh Tikoo, Sanjeev K Gupta and Dara Singh. Wide resection and stabilization of ulnar stump by extensor carpi ulnaris for giant cell tumor of distal ulna: two case reports. *Cases Journal* 2009, 2:8617.
 5. Harness NG, Mankin HJ. Giant cell tumour of distal forearm. *J Hand Surg* 2004 ; 29-A : 188-193.
 6. Campanacci M. Giant cell tumour. In : Campanacci M, ed. *Bone and Soft Tissue Tumours*. 2nd ed. Springer, New York, 1999, pp 99-132.
 7. Mandeep Singh Dhillon, Raghav Saini, Shivinder Singh Gill. Is there a need for reconstruction after excision of the distal ulna for Giant-Cell tumour? *Acta Orthop. Belg.*, 2010, 76, 30-37.
 8. Cooney WP, Damron TA, Sim FH, Linscheid RL. En bloc resection of tumours of the distal end of ulna. *J Bone Joint Surg* 1997 ; 79-A : 406-412.
 9. Wolfe SW, Mih AD, Hotchkiss RN, Culp RW, Keinfehaber TR, Nagle DJ. Wide excision of the distal ulna: a multicenter case study. *J Hand Surg.* 1998;23A:222–228.
 10. Isidre Gracia, Ignacio R. Proubasta, Laura Trullols, Ana Peiró, Esther Moya, Sarah Cortés, Oscar Buezo, Joan Majo. Distal radioulnar joint prosthesis for the treatment of giant cell tumor of the distal ulna: a case report and literature review. *Strategies Trauma Limb Reconstr.* 2011 August; 6(2): 103–106.
 11. Noble J, Arafa M. Stabilisation of distal ulna after excessive Darrach's procedure. *The Hand*.1983;15:70–72. doi: 10.1016/S0072-968X(83)80038-2.
 12. Laurentin-Pérez LA, Goodwin AN, Babb BA, Scheker LR. A study of functional outcomes following implantation of a total distal radioulnar joint prosthesis. *J Hand Surg.* 2008;33E(1):18–28.

Author Information

Rohit Sharma, Assistant Professor, DNB (Ortho), MNAMS

Department Of Orthopaedics, SGRD Medical College
Amritsar, Punjab, India
dr.rohitsharma@gmail.com

Sachin Gupta, Assistant Professor, MS (Ortho)

Department Of Orthopaedics, SGRD Medical College
Amritsar, Punjab, India

Nitin Saini, Senior Resident, DNB (Ortho)

Department Of Orthopaedics, SGRD Medical College
Amritsar, Punjab, India

Vikas Kakkar, Assistant Professor, MS, DNB (Gen Surgery), MCh (Plastic Surgery),

Department Of Surgery, SGRD Medical College
Amritsar, Punjab, India

Y Saini, Professor & Head, MS (Ortho)

Department Of Orthopaedics, SGRD Medical College
Amritsar, Punjab, India

Harpreet Singh, Postgraduate student, MBBS

Department Of Orthopaedics, SGRD Medical College
Amritsar, Punjab, India