

# Cervical Spine Locking Plate In The Treatment Of Neer Type-2 Lateral Third Clavicle Fractures: A New Method Of Fixation

R Sharma, S K Garg, R K Kansay, S Aggarwal, P Aggarwal

## Citation

R Sharma, S K Garg, R K Kansay, S Aggarwal, P Aggarwal. *Cervical Spine Locking Plate In The Treatment Of Neer Type-2 Lateral Third Clavicle Fractures: A New Method Of Fixation*. The Internet Journal of Orthopedic Surgery. 2013 Volume 21 Number 1.

## Abstract

**OBJECTIVE:** There is very high risk of delayed union, malunion, non-union (22-35%) and acromioclavicular joint arthritis with conservative management of fracture lateral third of clavicle. This study was done to find a new method of fixation of such fractures.

**METHODS:** 11 patients were operated for displaced fracture of the lateral third of the clavicle by Cervical Spine Locked Plate. The shoulder was immobilized for 3 weeks post-operatively. The patients were evaluated in clinic following operative treatment for the lateral third clavicle fractures at 6 weeks, 3 months and 6 months. All patients with more than 6 months follow-up after surgery were included. X-rays in AP projection were taken at every follow-up to look for bony union and clinical assessment was done by using the UCLA Shoulder Score at each follow-up. **RESULTS:** The UCLA Shoulder Score at each follow-up showed gradual improvement in the score. At final follow-up all the fractures had united and no additional procedure like bone grafting was done. **CONCLUSION:** We conclude that type-2 fracture of the lateral third of the clavicle require open reduction and can be safely fixed by a locked cervical spine plate which has not showed any complication.

## INTRODUCTION

Fractures of the lateral third of the clavicle, which account for 10-15% of all clavicle fractures, can present a difficult treatment dilemma when trying to achieve union with standard conservative methods (1). There is very high risk of delayed union, malunion, non-union (22-35%) and acromioclavicular joint arthritis with conservative management. Most authors recommend open reduction and internal fixation as treatment of choice but there is still no consensus about the ideal method and ideal implant to achieve the best outcome (2). Numerous techniques have been described for fixation using coracoclavicular screw, crossed K-wires, hook plate, tension band wire around coracoid process, trans-acromial K-wire and Knowles pin (3). The disadvantage of these technique relate to the necessity of implant removal prior to mobilization. We report our experience with use of Cervical Spine Locked Plate in fixation of unstable fractures of the lateral third of the clavicle.

## PATIENTS AND METHODS

Between July 2007 to Dec. 2008, 11 patients were operated

for displaced fracture of the lateral third of the clavicle by a Cervical Spine Locked Plate. Patients with more than 6 month follow-up after surgery were included. A total of 11 fractures were operated on 5 males and 6 females with an average age of 55 years (range 45-58 years). The dominant shoulder was involved in 4 cases and non-dominant was involved in 7 cases. Patients were evaluated with X-rays to access union and shoulder function was accessed using UCLA Shoulder Score.

**IMPLANT:** Cervical Spine Locked Plate is a very low profile plate designed for stabilization of the anterior cervical spine. This plate is available in different sizes according to levels to be fixed. The unique feature of this plate is its locking screws which get locked in plate which is advantageous in osteoporotic and cancellous bone.

## SURGICAL TECHNIQUE:

All patients were operated on under general anaesthesia in beach chair position. The shoulder was prepped and draped with the arm free. An incision was made in Langer's lines, positioned between the coracoid process and acromio-

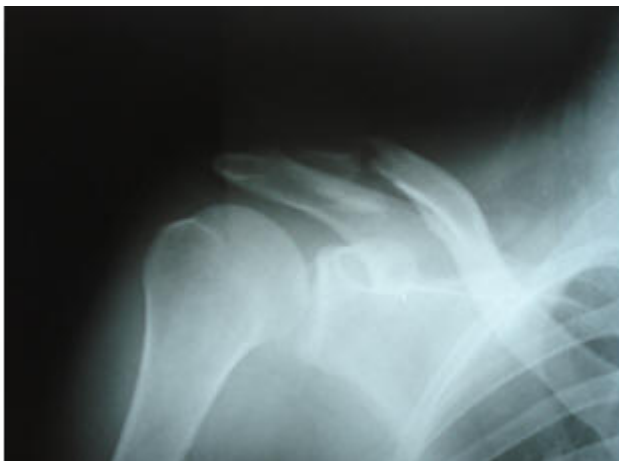clavicular joint to permit access to both locations. The incision extended from the posterior aspect of the clavicle down to the coracoid. Large subcutaneous flaps were raised superficial to deltotrapezial fascia. The fascia was then sharply divided along the length of exposed clavicle, over the fracture site and to the acromio-clavicular joint. The fracture was exposed and cleaned from soft tissue. Fixation was done with Cervical Spine Locking Plate after reduction of the fracture either with pointed reduction forceps or temporary k-wire fixation. Closure was done after achieving complete hemostasis. The average surgical time for the procedure was 1 hour and 10 minutes. The shoulder was immobilized for 3 weeks post-operatively. During the period of immobilization the patients were instructed to perform elbow range of motion exercises for maintaining normal function and preventing stiffness. Sutures were removed on 11th post-operative day.

#### **FOLLOW-UP:**

A series of radiographs in antero-posterior view of involved clavicle were taken at 6 weeks, 3 months, 6 months and 1 year to see for fragment alignment, implant position and bony union. Shoulder range of motion and strengthening exercises were started gradually after 6wks depending on X-ray evaluation. Range of motion exercises included pendulum arm swings, “walking” the fingers up the wall and pulling on either end of a towel held behind the back. After complete union of fracture strengthening exercises were started using hand weights or elastic exercise bands. The clinical outcome was recorded using UCLA Shoulder Score (4).

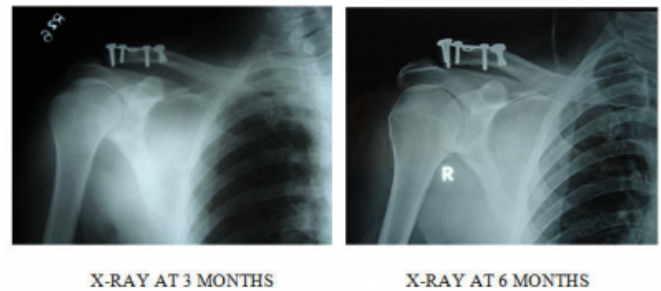
**Figure 1**

Pre-Operative X-Ray



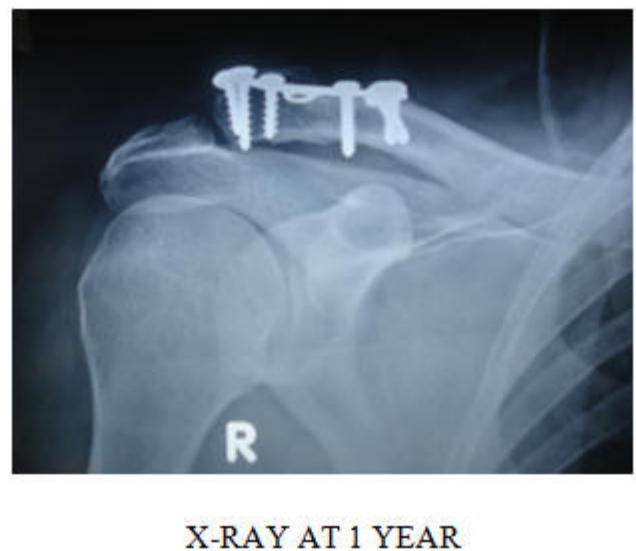**Figure 2**

X-Rays at 3 and 6 months



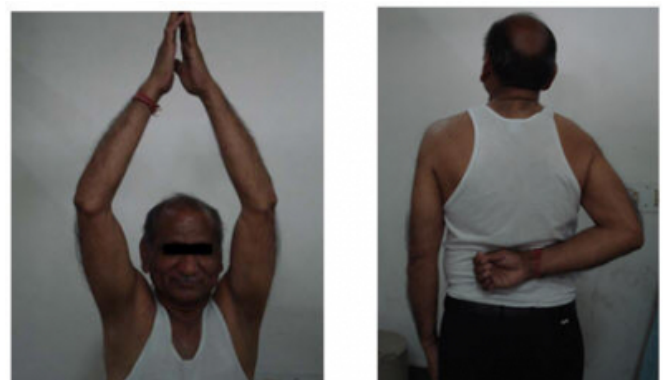**Figure 3**

X-Ray at 1 year



**Figure 4**

Post-operative shoulder range of movement at 1 year



## **RESULTS**

The 11 patients were evaluated in clinic following operative treatment for Lateral third clavicle fractures at 6 weeks, 3

months and 6 months. The average time of follow-up was 12 months (range 4-15 months). X-rays in AP projection were taken at every follow-up to look for bony union and clinical assessment was done by using UCLA Shoulder Score at each follow-up which showed gradual improvement in score at each follow-up. At the final follow-up all the fractures had united and no additional procedure like bone grafting was done. Out of 11 patients, 5 showed excellent results and the remaining 6 showed good results. No complication occurred throughout the period of this study pertaining to infection or implant like screw back out, breakage and impingement of plate. There was no incidence of screw and plate back out because of its locking mode. At recent follow-up at 15 months all patients were fully satisfied in terms pain and shoulder function.

**Table 1**

UCLA score at each follow-up

NO. OF PTS	PAIN			FUNCTION			ACTIVE FORWARD FLEXION			STRENGTH OF FORWARD FLEXION			PATIENT'S SATISFACTION		
	6 wks	3 mon	6 mon	6 wks	3 mon	6 mon	6 Wks	3 mon	6 mon	6 Wks	3 mon	6 mon	6 wks	3 mon	6 mon
1	4	8	10	2	6	10	3	4	5	3	4	4	5	5	5
2	4	8	10	2	6	10	3	4	5	4	4	4	5	5	5
3	6	8	10	2	6	10	4	4	5	3	4	5	5	5	5
4	4	8	10	4	8	8	4	4	5	4	4	5	5	5	5
5	4	8	10	4	6	8	3	5	4	3	4	5	5	5	5
6	4	8	8	2	6	10	3	4	5	3	4	5	5	5	5
7	6	8	10	4	6	10	3	5	4	3	4	5	5	5	5
8	6	8	8	4	8	10	4	4	5	4	4	5	5	5	5
9	4	8	10	2	8	8	3	4	5	4	4	5	5	5	5
10	4	8	10	2	8	10	3	4	4	4	4	5	5	5	5
11	6	8	10	4	6	8	4	4	5	3	4	5	5	5	5

## DISCUSSION

It has been estimated that fractures of the clavicle account for 1 in 20 of all fractures and 44% of all injuries to the shoulder girdle (5). Allman divided clavicle fractures in 3 types:

- Group -1: involve middle third (80%).
- Group -2: involve lateral third (12-15%).
- Group -3: involve proximal third (least common 5%) (6).

Fractures of group -2 have been further sub classified into three main types according to location of coraco-clavicular ligaments relative to fracture fragments by Neer:

1. Type -1: stable fractures lateral to the coraco-clavicular ligament.
2. Type -2: unstable fractures with damage to coraco-clavicular ligament causing a loss of ligamentous connection between coracoid and medial fragment.

3. Type -3: Intra-articular fracture at acromioclavicular joint (3).

Lateral third clavicle fractures were seen in an older population and a higher proportion was due to simple falls (5). Because of the rarity of this type of fracture, it is important to note that most studies in the literature are retrospective outcome studies involving small number of patients. Therefore, it is difficult to find conclusive data to support one treatment modality (1). The ultimate goal is to achieve bone healing with minimum morbidity, loss of function and residual deformity in type -2 fractures. They have a high rate of non-union (22-33%) when treated non-operatively. A sling does not reduce the fracture and use of figure of eight bandage is contraindicated because it can further displace the fragment. Non-union in type-2 fractures is likely to be related to penetration of the medial fragment through the trapezius ("button-hole" injury), coupled with weight of dependent arm, which acts to maintain displacement at fracture site (6). A type-2 distal clavicle fracture may take up to 12 wks to heal if it is treated conservatively.

Several surgical techniques have been reported, but none is widely accepted as the gold standard. Kirschner wire and Transacromial Kirschner wire fixation has been advocated, but this has been shown to have a high complication rate in form 32% rate of infection, non-union and wire migration which may occur due to movements at the fracture site due to muscular activity, respiratory excursion, capillary action, electrolysis, regional resorption of bone, gravitational forces and great freedom of motion of upper extremity (7) (8).

The transacromial extra-articular Knowles pin fixation method is a reliable method to treat the unstable distal clavicle fractures with an acceptable complication rate (16). Temporary coracoclavicular screw fixation achieves bony union without violating the acromioclavicular joint and requires minimal soft tissue dissection (12,13, 14, ) but Screw back out is a potential complication. Strict compliance with the postoperative physiotherapy regimen is necessary to avoid early scapular-thoracic motion, which causes rotation and tilting of the fracture site, which predisposes to screw back out (15).

An extra articular tension band technique gives no protection against wire migration, and the metal work may cause skin problems that require removal under general anesthetic. Coracoclavicular slings using Dacron or polydioxanone mersilene have been reported to produce satisfactory outcome, but considerable dissection is required to pass the slings below the coracoid process and risk of fatigue fracture

of sling, coracoid process and fixation failure (9, 10, 11). Tambe et al used pre-contoured hook plate (designed by AO/ASIF) for fixation of fracture of lateral third clavicle which gets fit under the posterior part of the acromion but confers a major risk of acromion osteolysis and requires plate removal before mobilization (2). Open reduction and internal fixation for lateral end clavicle with 4.5mm malleolar AO/ASIF screw have been described (17). All the above mentioned modalities for treatment of fracture of lateral end clavicle are associated with complications and failure rate as Biomechanical studies have confirmed that rotational movement occurs between the clavicle and the scapula. Displaced fractures of the lateral third clavicle are unstable injuries with a high potential for symptomatic non-union that affects function. Therefore, open reduction and internal fixation is recommended to obtain optimum results and to prevent and minimize the complications. We have used Cervical Spine Locking Plate which has following advantages:

- Stable fixation of fracture
- Low profile implant
- No need for implant removal prior to mobilization

The superior surface of the clavicle is broad and fits the Cervical Spine Locking Plate comfortably. Moreover the angle of screw to be inserted can be changed up to 120°. So we conclude that type-2 fractures of the lateral third of the clavicle require open reduction and can be safely fixed by locked cervical spine plate which has not showed any complication.

## References

1. Ritche et al. Distal clavicle fractures: A current Review. *Current Opinion in Orthopaedics*. 15 (4); 2004:257-60.
2. Tambe AD, Motkar P, Qamar A, Drew S, Turner SM. Fractures of distal third of clavicle treated by hook plating. *International Orthopaedics (SICOT)* (2006) 30: 7-10.
3. Badhe SP, Lawrence TM, Clark DI. Tension band suturing for the treatment of displaced type-2 lateral end clavicle fractures. *Arch Orthop Trauma Surg* (2007) 127:25-28.
4. Matson-III FA, Smith KL, Parsons M. Effectiveness evaluation and the shoulder. *The Shoulder*. 3rd ed. 2004. 1387-1417.
5. Robinson CM. Fractures of the clavicle in the adult. *J Bone Joint Surg [Br]* 1998;80-B:476-84.
6. Housner JA, Kuhn JE. Clavicle Fractures. *The Physician and Sports Medicine*. Vol 31, No.12, Dec 2003.
7. Abdelnoor J, Mantoura J, Nahas A. Cervicothoracic pin migration following open reduction and pinning of a clavicular fracture: a case report. *Eastern Journal of Medicine*. 5(1); 2000:26-28.
8. Kona J, Bosse MJ, Staeheli JW, Rosseau RL. Type II distal clavicle fractures: a retrospective review of surgical treatment. *J Orthop Trauma* 1990; 4:115-20.
9. Moneim MS, Balduino FC. Coracoid fracture as a complication of surgical treatment by coracoclavicular tape fixation. A case report. *Clin Orthop Relat Res* 1982; 168:133-5.
10. Hughes PJ, Bolton-Maggs B. Fractures of the clavicle in adults. *Curr Orthop* 2002; 16:133-8.
11. Webber MC, Haines JF. The treatment of lateral clavicle fractures. *Injury* 2000; 31:175-9.
12. Ballmer FT, Gerber C. Coracoclavicular screw fixation for unstable fractures of the distal clavicle. A report of five cases. *J Bone Joint Surg Br* 1991; 73:291-4.
13. Yamaguchi H, Arakawa H, Kobayashi M. Results of the Bosworth method for unstable fractures of the distal clavicle. *Int Orthop* 1998; 22:366-8.
14. Edwards DJ, Kavanagh TG, Flannery MC. Fractures of the distal clavicle: a case for fixation. *Injury* 1992; 23:44-6.
15. Fazal MA, Saksena J, Haddad FS. Temporary coracoclavicular screw fixation for displaced distal clavicle fractures *Journal of Orthopaedic Surgery* 2007;15(1):9-11
16. Cheng-Yuh F et al. Transacromial Knowles Pin in the treatment of Neer Type-2 Distal clavicle fractures: a Prospective evaluation of 32 cases. *The Journal of trauma, injury, infection, and critical care*. vol. 56, (5); 2004:1102-1106
17. Scadden J, Richards R. Intramedullary fixation of Neer type 2 fractures of the distal clavicle with an AO/ASIF screw. *Injury*, Volume 36, Issue 10, Pages 1172 – 1175.

**Author Information**

**Rohit Sharma**

Department of Orthopaedics, Government Medical College and Hospital  
Sector 32, Chandigarh, India

**Sudhir K Garg**

Department of Orthopaedics, Government Medical College and Hospital  
Sector 32, Chandigarh, India

**Rajeev Kumar Kansay**

Department of Orthopaedics, Government Medical College and Hospital  
Sector 32, Chandigarh, India

**Siddharth Aggarwal**

Department of Orthopaedics, Government Medical College and Hospital  
Sector 32, Chandigarh, India

**Purnima Aggarwal**

Department of Radio Diagnosis, Government Medical College and Hospital  
Sector 32, Chandigarh, India