

Branchial Cyst In The Midline Of The Neck: A First Case Report In The Literature

S Aggarwal, P Garg, S Bhoariwal, V S Rathee, S Verma, S Mittal, A Narang, K Kaushik, J Singh

Citation

S Aggarwal, P Garg, S Bhoariwal, V S Rathee, S Verma, S Mittal, A Narang, K Kaushik, J Singh. *Branchial Cyst In The Midline Of The Neck: A First Case Report In The Literature*. The Internet Journal of Otorhinolaryngology. 2013 Volume 15 Number 1.

Abstract

Branchial cysts are the commonest cystic swelling of the neck, known to occur usually in the lateral side of the neck mostly in relation with the sternocleidomastoid muscle. It is also described at various other non-classical sites but the literature is silent about its presence in the midline of the neck. The following case describes the location in the midline of the neck hence enriching the literature.

INTRODUCTION

Branchial cysts are the commonest cystic swelling of the neck, known to occur usually in the lateral side of the neck mostly in relation with the sternocleidomastoid muscle. It is also described at various other non-classical sites but the literature is silent about its presence in the midline of the neck. The following case describes the location in the midline of the neck hence enriching the literature.

CASE PRESENTATION:

A 35 year old female presented with a gradually progressive painless swelling in the midline of the neck for the past 4 years. It was not associated with any other relevant symptom. Her general physical examination was essentially normal. On local examination, a non-tender and non-transilluminant, cystic swelling, 3x4 cm in size present in the midline of the neck just below the hyoid bone. It was not moving with deglutination and protrusion of the tongue. No other swelling was present in any other region. She was worked up for excisional biopsy under general anesthesia. Intraoperative finding were suggestive of a cystic swelling of size 3.5 x 3.5 cm was present about 2.5 cm above the sternal notch without connective stalk. It also adhered with the strap muscles and pre tracheal fascia, however, it was free from the trachea. It contained milky white material. Histopathological examination revealed it to be a branchial cyst with marked congestion and fibrosis. The patient was discharged on the 2nd postoperative day and is doing well in

the follow up.

Figure 1

Pre operative photo of patient showing midline swelling

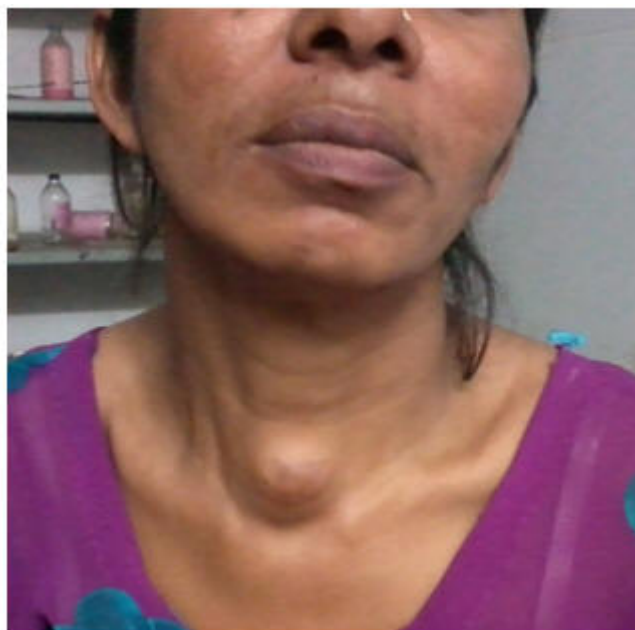
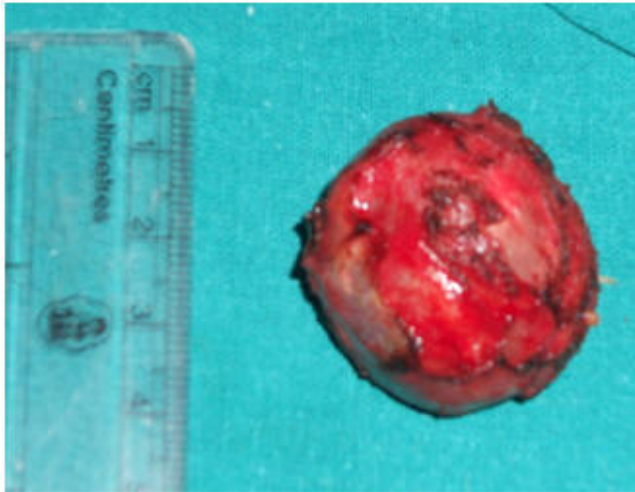

Figure 2

Excised cyst with scale.



DISCUSSION

The mature structures of the head and neck are embryologically derived from six pairs of branchial arches, their intervening clefts externally, and pouches internally. Congenital cysts, sinuses, or fistulas result from failure of these structures to regress, persisting in an aberrant location.¹⁰ In children, fistulas are more common than external sinuses, which are more common than cysts. In adults, cysts predominate.¹⁰ Overall cyst predominates fistula and sinus. Ninety-five percent of branchial cleft cysts derive from the remnant of the second branchial cleft.^{1,2} The rest arises from remnant of other branchial clefts. The maldevelopment appears to be in the branchial groove rather than the branchial cleft. By definition, branchial remnants are present at the time of birth, although they may not become clinically evident until later in life.¹⁰ Such cysts are found more commonly in females and usually occur in the 2nd or 3rd decade of life³ and mostly suspected in all the cystic swellings of the neck except the median ones.³ Classically they are located along the anterior border of upper and lower third of sternocleidomastoid muscle. Other sites like posterior triangle³, salivary gland⁴, oral cavity⁵, thyroid gland⁶, mediastinum⁷ and pancreas⁸ have also been described. Due to the variability of the position King suggested that any cyst arising outside the midline, with the histological features as above should be regarded as a lymphoepithelial or a branchial cyst⁹. Clinical signs and symptoms may vary in accordance to distant inflammatory processes such as upper respiratory or dental infection resulting in sudden swelling, pain, difficulty in swallowing, hoarseness, sore throat, and fluctuation in size¹¹ Complete surgical removal remains the only acceptable form of

treatment.³

Embryological derivative of branchial cleft

The first branchial cleft normally gives rise to the eustachian tube, tympanic cavity, and mastoid antrum and contributes to the formation of the tympanic membrane. It is the only cleft to contribute to an adult structure, the external auditory canal. The second, third, and fourth branchial clefts are part of an ectodermally lined depression known as the cervical sinus of His. As the second and fifth branchial clefts merge with each other, this cervical sinus is obliterated. The second branchial pouch, lined by endoderm, gives rise to the palatine tonsil and tonsillar fossa. The third branchial pouch forms the inferior parathyroid gland, thymus, and pyriform sinus; the fourth branchial pouch leads to the formation of the superior parathyroid gland and apex of the pyriform sinus. Location of these remnants dictates their embryologic origin and guides the subsequent operative approach. Failure can result in incomplete resection or injury to adjacent structures.

CONCLUSION

Branchial cyst should be kept in mind as differential diagnosis in a non transilluminant, cystic swelling of the midline of the neck if it is not moving with protusion of the tongue or with deglutination.

References

1. Som PM. Cystic lesions of the neck. *Postgrad Radiol* 1987;7:21 1-236
2. Harnsberger HR, Mancuso AA, Muraki AS, Byrd SE, Dillon WP, Johnson LP et al. Branchial cleft anomalies and their mimics: computed tomographic evaluation. *Radiology* 1984;152:739-48.
3. Sinha P, Utture S: Branchial Cysts: a Case Report of a Benign Lymphoepithelial Cyst in the Neck with Review of Literature: *Bombay hospital journal*, Volume 43 No.3, July 2001
4. Chiang CH, Chiang FY, Lin CH, Jaun KH. Lymphoepithelial cyst of the parotid gland-a case report. *Kaohsiung J med sci*. 1998; 14: 738-42.
5. Kumara GR, Gillgrass TJ, Bridgman JB. A lymphoepithelial cyst (branchial cyst) in the floor of the mouth. *N Z Dent J*. 1995; 91: 14-5.
6. Ryska A, Vokurka J, Michal M, Ludvikova M. Intrathyroidal lymphoepithelial cyst. A report of two cases not associated with Hashimoto's thyroiditis. *Pathol Res Pract*. 1997; 193: 777-81.
7. Tanaka H, Igarashi T, Teramoto S, Yoshida Y, Abe S. Lymphoepithelial cyst in the mediastinum with an opening to the trachea. *Respiration* 1995; 62:110-3.
8. Yamamoto K, Fujimoto K, Matsushiro T, Ota K. Lymphoepithelial cyst in the pancreas: a case report. *Gastroenterol Jpn*. 1990;25: 758-61.
9. Golledge J, Ellis H. The aetiology of lateral cervical(branchial) cysts: past and present theories. *J Laryngol Otol*. 1994;108:653-9.
10. Warner BW. Pediatric surgery. In: Townsend CM,

Beauchamp RD, Evers BM, Mattox KL eds. Sabiston textbook of surgery. 18th ed. Philadelphia. Saunders Inc., 2008.

11. Rickles NH, Little JW. The histogenesis of the branchial cyst. II. A study of lining epithelium. Am J Pathol. 1967;50:765-77.

Author Information

Sourabh Aggarwal, Dr, M.B.B.S

Department of Surgery, Pt. B. D. Sharma Post Graduate Institute of Medical Sciences
Rohtak, Haryana, India

Pradeep Garg, Dr, M.S, D.N.B

Department of Surgery, Pt. B. D. Sharma Post Graduate Institute of Medical Sciences
Rohtak, Haryana, India
drpradeepgarg@rediffmail.com

Sandeep Bhoariwal, Dr, M.S

Department of Surgery, Pt. B. D. Sharma Post Graduate Institute of Medical Sciences
Rohtak, Haryana, India

Vazir Singh Rathee, Dr, M.S

Department of Surgery, Pt. B. D. Sharma Post Graduate Institute of Medical Sciences
Rohtak, Haryana, India

Surender Verma, Dr, M.S

Department of Surgery, Pt. B. D. Sharma Post Graduate Institute of Medical Sciences
Rohtak, Haryana, India

Sachin Mittal, Dr, M.B.B.S

Department of Surgery, Pt. B. D. Sharma Post Graduate Institute of Medical Sciences
Rohtak, Haryana, India

Amit Narang, Dr, M.B.B.S

Department of Surgery, Pt. B. D. Sharma Post Graduate Institute of Medical Sciences
Rohtak, Haryana, India

Kaviraj Kaushik, Dr, M.B.B.S

Department of Surgery, Pt. B. D. Sharma Post Graduate Institute of Medical Sciences
Rohtak, Haryana, India

Jaspreet Singh, Dr, M.B.B.S

Department of Surgery, Pt. B. D. Sharma Post Graduate Institute of Medical Sciences
Rohtak, Haryana, India