

Adrenal Cortical Carcinoma: An Updated Review

J Rose, M A Guerrero

Citation

J Rose, M A Guerrero. *Adrenal Cortical Carcinoma: An Updated Review*. The Internet Journal of Endocrinology. 2013 Volume 8 Number 1.

Abstract

This article reviews adrenal cortical carcinoma (ACC), especially associated synchronous and metachronous malignancies. The authors will discuss the genetic lesions associated with ACC, the clinical presentation, diagnosis, and treatment options. We hope to provide a thorough and updated review of this rare malignancy.

INTRODUCTION

Adrenal cortical carcinoma (ACC) is a rare and aggressive cancer that affects about 1 or 2 patients per million. ACC comprises only 0.02% of all reported cancers worldwide, but accounts for 0.2% of all cancer deaths annually. It has a variable presentation. Its distribution is bimodal: it commonly occurs in patients under the age of 5 years or between the ages of 40 and 50 years [1].

ACC affects women more frequently than men (male to female ratio, 1 to 1.5) [2]. Recent epidemiologic studies have shown that oral contraceptives and tobacco use increase the risk of developing ACC [1]. If oral contraceptives are started before (vs. after) the age of 25 years, the risk is 5 times higher. Smokers (vs. nonsmokers) have a rate of ACC that is 1.6 to 2 times higher [3].

In most patients, ACC arises as a spontaneous mutation, without any known risk factors. However, various genetic alterations have been implicated in its development. Genetic mutations in patients with ACC have been linked to hereditary syndromes and thus might contribute to the development of synchronous and metachronous cancers.

In this comprehensive overview, we note the current advances in the diagnosis and management of ACC.

GENETICS

Most genetic alterations identified in patients with ACC are associated with hereditary syndromes (Table 1). In patients with hereditary syndromes, ACC usually develops as a metachronous cancer. However, in patients without any hereditary syndrome, metachronous ACC and synchronous ACC have also been reported (Table 2). Those reports did

not specifically include genetic analysis, but we know that the p53 germline mutation is more frequently identified in patients with ACC and another lesion.

Table 1

Hereditary syndromes associated with ACC

Syndrome	Chromosome abnormalities	Diseases/clinical manifestations
Li-Fraumeni	TP53, chromosome 17q13, hCHK2, 1q23	Breast carcinomas, soft-tissue sarcomas, brain tumors, osteosarcomas, leukemia, ACC
MEN type 1	11q3	Tumors of the parathyroids, anterior pituitary, and endocrine pancreas; thyroid adenomas; adrenal adenomas; ACC
Carney complex	PRKARIA (17q22-24), 2p16	Cardiac and cutaneous myxomas, pigmented skin lesions, endocrine disorders (including ACC), pituitary growth hormone adenomas, testicular tumors
Beckwith-Wiedemann syndrome	11p15, p57kip2 (CDKN1C), KCNQ10T, H19, IGF-II	Overgrowth disorder with macrosomia, macroglossia, and organomegaly; developmental abnormalities; Wilms tumors; ACC; neuroblastomas; rhabdomyosarcomas; hepatoblastomas
Gardner syndrome	5q12	Colorectal cancer, GI polyps, osteomas, soft-tissue sarcomas, adrenal adenomas, ACC

Table 2

Malignancies associated with ACC

Synchronous lesions	Reference	Presentation	Lesions
	Guerrero 2010	32-year-old female: vaginal bleeding and LLE edema	Stage I endometrial adenocarcinoma, stage I ovarian adenocarcinoma
	Eisinger 1983	45-year-old female: lumbar pain and diarrhea	Breast cancer, colorectal cancer
	Inoue 1998	51-year-old male: new mass with known malignancy	Metastatic seminoma (stage IIIB)
	Pivnick 1998	20-month-old female: hypertension workup, with cardiac defects, Li-Fraumeni syndrome	Ganglioneuroblastoma
	Khayat 2004	7-year-old female: jaw swelling, history of rhabdomyosarcoma	Osteosarcoma
	Jani 2008	53-year-old male: gastroparesis, nausea, hypertension	Clear-cell renal carcinoma
Metachronous lesions		Gastrointestinal stromal tumors, paragangliomas, pulmonary chondromas, astrocytomas, osteogenic sarcomas, non-small-cell lung cancer, rhabdomyosarcomas	Familial syndromes: Lynch II with endometrial and breast cancer, Gardner syndrome with colon cancer

Legend: ACC = adrenal cortical carcinoma, GI = gastrointestinal, LLE = left lower extremity

One of the most common genetic mutations (identified in 85% of patients with ACC) affects the chromosome 11p15 locus. This mutation leads to overexpression of insulin-like growth factor II (IGF-II) [2,4]. IGF-II acts on the IGF-I receptor to induce cell proliferation and tumor growth [2].

Another gene commonly mutated in patients with ACC (in nearly 70% of them) is the TP53 gene [2,4]. A tumor suppressor gene, TP53 encodes for transcription factors involved in apoptosis and in regulation of the cell cycle. The TP53 mutation is the most common mutation in human cancers [5,6]. It leads to uncontrolled cellular proliferation.

In addition, the P53 gene mutation on chromosome 17q13 [2,4] has been identified in patients with the Li-Fraumeni syndrome. This hereditary syndrome is characterized by breast carcinomas (in 24% of patients), soft-tissue sarcomas (11.6%), brain tumors (12.0%), osteosarcomas (12.6%), hematologic malignancies (4% to 6%), and ACC (3% to 4%) [5,7]. In children, a diagnosis of ACC often reveals the Li-Fraumeni proband [1].

Another mutation (identified in 12.5% of patients with ACC) is the N-ras mutation, which encodes a guanosine

triphosphate (GTPase) involved in signaling pathways that encode genes regulating proliferation, differentiation, motility, and death. The N-ras mutation is one of the most frequently mutated genes in human cancers [8].

The Wnt signaling pathway, which comprises a group of lipoproteins with roles in embryogenesis and hemostatic processes, is also frequently mutated in patients with adrenal adenomas (27%) and, in particular, in patients with ACC (31%) [8,9]. This pathway is also commonly mutated in patients with familial adenomatous polyposis coli [10].

Recent advances in genomic microarray analysis have identified several genetic alterations in patients with ACC. Loss of genetic material on chromosomes 1, 2, 3, 6, 11, and 13—and gains on chromosomes 4, 5, 9, 12, 17, and 20—may also contribute to the development of adrenal cancer [1,11]. Gains on chromosome 17 are most commonly associated with the development of ACC (found in 17% to 25% of patients with ACC) and are also frequent in patients with adrenal adenomas (26% to 35%) and in patients with adrenal hyperplasia (17% to 33%) [11,12].

A specific genetic mutation on chromosome 17 (17q22-24) encodes the PRKARIA gene, a mediator of cyclic adenosine monophosphate (cAMP) signaling [5,13]. This mutation has been associated with the Carney complex, which is characterized by cardiac and cutaneous myxomas, pigmented skin lesions, pituitary growth hormone-producing adenomas, testicular tumors, and endocrine disorders (including ACC) [4].

Mutations on chromosome 11 have also been associated with the development of ACC. A mutation on chromosome 11q3 affects the MEN1 gene that encodes for the suppressor protein menin [13]. Mutations on the MEN1 gene result in multiple endocrine neoplasia syndrome (MEN) type 1, which is characterized by tumors of the anterior pituitary gland, tumors of the endocrine pancreas, and parathyroid gland hyperplasia. Patients with MEN type 1 are also at risk of developing adrenal adenomas (55%), and, albeit rarely, ACC [4,5].

A mutation on chromosome 11p15 is associated with Beckwith-Wiedemann syndrome (BWS) [5]. The clinical features of BWS, an overgrowth disorder, include macrosomia, macroglossia, organomegaly, and some developmental abnormalities. Other genetic abnormalities associated with BWS include P57kip2 (CDKN1C),

KCNQ10T, H19, and IGF-II overexpression; these abnormalities have also been found in patients with sporadic ACC, who have a propensity to develop Wilms tumors, neuroblastomas, rhabdomyosarcomas, and hepatoblastomas [4,5]. ACC also develops in about 5% of patients with BWS [5]. Less commonly, ACC develops in patients who do not have BWS but do have Wilms tumors or WAGR (Wilms tumor, aniridia, genitourinary abnormalities, and mental retardation) syndrome [14].

Other genetic mutations leading to hereditary syndromes have been shown to predispose to the development of ACC. Adenomatous polyposis coli (APC) gene mutations on chromosome 5q21 lead to Gardner syndrome. This autosomal disorder results in colorectal cancer, gastrointestinal polyps, osteomas, and soft-tissue sarcomas [15]. Such patients are also prone to adrenal adenomas and, to a lesser extent, to ACC [15,16].

GNAS gene mutations on chromosome 20q13.3 lead to McCune-Albright syndrome; such patients are prone to developing ACC [17]. This syndrome is characterized by precocious puberty, café-au-lait spots, and polyostotic fibrous dysplasia.

CLINICAL PRESENTATION

The clinical presentation of ACC is variable. Most patients are asymptomatic or have vague symptoms. However, more than 50% of ACC tumors produce hormones, which may result in symptoms related to hormone excess [1]. Patients with nonfunctioning tumors (i.e., those that do not produce hormones) commonly have nonspecific symptoms. Usually, symptoms result from the mass effect of the tumor, which causes vague abdominal pain, back pain, nausea, vomiting, abdominal fullness, varicocele, or dyspnea [1,2]. Patients with symptoms are more likely to have metastatic disease at presentation [13].

Cushing syndrome is the most common presentation in patients with hormonally active ACC [2]. It occurs in 30% to 40% of patients with ACC, and symptoms usually progress rapidly [13]. Symptoms can include hypertension, skin atrophy, muscle weakness, hyperglycemia, psychiatric disturbances, hirsutism, facial plethora, a dorsocervical fat pad, abdominal striae, acne, ecchymosis, and proximal muscle wasting [4,18]. However, in children, virilizing tumors are the most common manifestation of ACC, accounting for 20% to 30% of their tumors [13]. Adrenal tumors causing virilization in women, and feminization in

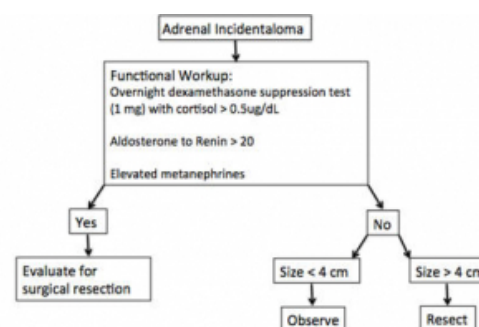
men, are highly suspicious for ACC. Pure aldosterone-secreting tumors are extremely rare in patients with ACC (< 1%), but such patients may have hypertension and hypokalemia [1].

DIAGNOSIS

No specific laboratory or imaging study is diagnostic of ACC. Again, most patients with ACC are asymptomatic or have vague symptoms, so a diagnosis of ACC is typically suspected only after an imaging study has been performed. Not uncommonly, an adrenal mass is found incidentally, during an imaging study performed for other reasons (known as an adrenal incidentaloma). Evaluation of an adrenal mass first involves determining whether or not it is metabolically active (Table 3).

Table 3

Adrenal incidentaloma workup



*Adapted from Zeiger MA, Thompson GB, Duh QY, Hamrahian AH, Angelos P, Elaraj D, Fishman E, Kharlip J. American Association of Clinical Endocrinologists and American Association of Endocrine Surgeons Medical Guidelines for the Management of Adrenal Incidentalomas. *Endocr Pract* 2009; 15 (Suppl 1): 1-20.

Testing for hypercortisolism is commonly performed with an overnight dexamethasone (1 mg, a low dose) suppression test. However, 2 other screening tests can also be used: (1) a midnight salivary cortisol, 48-hour low-dose dexamethasone suppression test and (2) a 24-hour urine free cortisol level test. Any positive result on one screening test should be confirmed with a different screening test. In addition, evaluation for a pheochromocytoma is necessary by testing for plasma-fractionated metanephrines. Hyperaldosteronism is diagnosed with plasma aldosterone and plasma renin activity levels [1,18].

Rapidly progressive feminization or virilization is suggestive of ACC. However, hormone levels are often elevated without clinical symptoms. Therefore, biochemical evaluation of ACC also includes testing for androstenedione, 17-alpha-hydroxyprogesterone, estradiol, and

dehydroepiandrosterone sulfate (DHEA-S) [2,4,13].

Elevated levels of any of those hormones indicate a higher likelihood of malignancy.

In addition to hormonal analysis, tumor size helps determine the risk of malignancy. Lesions larger than 6 cm confer the highest risk of ACC: 25% of lesions larger than 6 cm are ACCs. Only 6% of lesions between 4.1 and 6 cm are ACCs; only 2% of lesions < 4 cm are malignant [18]. The current recommendation is to resect all nonfunctioning adrenal tumors 4 cm or larger; as lesions greater than 4 cm have a 93% sensitivity and 24% specificity for a diagnosis of ACC [1,18]. Despite the current recommendation, ACCs can be smaller [2].

Other radiologic findings are suggestive of malignancy, regardless of tumor size. ACCs are more likely to have irregular margins and to be inhomogeneous and irregular, per contrast enhancement (suggestive of necrosis) [2,4,18]. Occasionally, such lesions have calcifications. More advanced lesions also demonstrate invasion into adjacent organs and structures, and may cause inferior vena cava thrombosis [18]. Metastasis can also be found on imaging studies, most commonly involving the liver and lungs; such a finding helps determine the cancer stage at presentation.

The density of the adrenal mass on computed tomography (CT), defined in Hounsfield units (HU), can also differentiate ACCs from adrenal adenomas. CT is 71% sensitive and 98% specific for a diagnosis of ACC, whose lesions typically have a non-enhanced density of > 10 HU and an enhanced density of > 35 HU, with a washout rate of < 50% and a delayed attenuation of 35 HU [2].

Magnetic resonance imaging (MRI) with gadolinium can be used to evaluate adrenal tumors. T2-weighted MRI shows lesions that light up more intensely than the liver. On chemical shift imaging, adenomas can be distinguished from malignancies because adenomas have high lipid content. Adenomas also display signal washout on subsequent images. Malignancies appear heterogeneous, due to hemorrhage and necrosis. They also tend to have more visible fluid on T2-weighted images [4]. MRI is 81% to 89% sensitive and 92% to 99% specific for a diagnosis of ACC [2]. Before surgery, MRI can also help assess the extent of vascular invasion by tumors [19]. For diagnostic purposes, adrenal scintigraphy is also available, but given its high cost and the risks of irradiation, it is uncommonly used.

Recent studies have shown that 18F-

fluorodeoxyglucose–positron emission using an adrenal gland to liver maximum to standardized uptake value (SUV) ratio of 1.45, was 100% sensitive and 88% specific for differentiating adenomas from ACCs. Although PET is not diagnostic of ACC, it may be a useful test to further evaluate lesions that are indeterminate on other imaging modalities [20]. Table 4 shows sensitivities and specificities of various imaging modalities.

Table 4

Sensitivity and specificity of imaging modalities for ACC

Modality	Sensitivity	Specificity
CT	71%	98%
MRI	81% to 89%*	92% to 99%*
18F-FDG-PET	100%	88%

*Range of MRI values due to multiple types of enhanced views and controversy on optimal method

Legend: ACC = adrenal cortical carcinoma, CT = computed tomography, 18F-FDG-PET = 18F-

fluorodeoxyglucose–positron emission tomography, MRI = magnetic resonance imaging

Biopsies in patients with ACC (unlike in those with other malignancies) may lead to needle tract metastasis. Biopsies also provide little information to help distinguish ACCs from adenomas. Therefore, they are used only when metastasis is suspected, when a surgical approach is not possible, or when a diagnosis is necessary to tailor medical therapy [2,13,18]. If a biopsy is being considered, hormonal analysis must be completed before performing fine-needle aspiration, in order to prevent catastrophic complications.

Molecular markers, though not routinely used clinically, can help differentiate benign from malignant adrenal tumors. For example, nuclear transcription factor 1 can identify > 95% of ACCs and can influence prognosis. In addition to the previously mentioned genetic mutations, the presence of these molecular markers can help confirm malignancy: cyclin E, matrix metalloproteinase-2, telomerase, topoisomerase IIa, and N-cadherin [21].

STAGING

In 2004, the World Health Organization (WHO) came up with a uniform staging system for ACC: stage I, tumors < 5cm; stage II, tumors > 5cm; stage III, nodal disease; and stage IV, metastasis. Before 2004, the most common staging system was the Sullivan modification of the McFarlane system, although Icard and Lee had also proposed revisions. Those 2 systems have never been compared to determine which provides the most accurate prognosis [1,2]. In 2008, Fassnacht et al suggested modifications included in the European Network for the

Study of Adrenal Tumors Classification. This updated staging system, groups ACC as follows: T1: tumors less than 5cm, T2: tumors greater than 5cm, T3: tumor infiltration of surrounding tissues, T4: tumor invasion of adjacent organs, vena cava, or renal vein, N0: no nodes, N1: positive lymph nodes, M0: no metastasis, M1: distant metastasis. Therefore, stage 1 includes T1, N0, M0 lesions; stage 2 is T2, N0, M0; stage 3 is T1-2, N1, M0 or T3-4, N0-1, M0; and stage 4 is any T, any N, and M1 (Table 5) [22].

Table 5
ENSAT TNM stages

Stage	Tumor description	Designation
I	Localized tumors < 5 cm	T1N0M0
II	Localized tumors > 5 cm	T2N0M0
III	Locally invasive tumors	T1,2N1M0 and T3,T4 N0-1
IV	Tumors invading organs, or venous tumor thrombus in vena cava or renal vein, or distant metastasis	T1-4, N0-1, M1

Legend: TNM = tumor-nodes-metastasis, ENSAT = European Network for the Study of Adrenal Tumors

PATHOLOGY

ACCs can be differentiated from benign lesions by macroscopic features, including tumor weight, hemorrhage, and breached tumor capsules. Microscopically, ACCs are diagnosed using the Weiss score or the Van Slooten index. The Weiss score is more commonly used: a score higher than 3 is suggestive of malignancy. The score is determined by adding up the following features: high mitotic rate, atypical mitosis, high nuclear grade, low percentage of clear cells, necrosis, diffuse tumor architecture, capsular invasion, sinusoidal invasion, and venous invasion [13].

In a follow-up study by Jain et al., 100% of patients with ACC had a score higher than 3 (and of those, 83% had a score of 7 or higher); their 5-year survival rate was 0%. In contrast, patients with a score under 3 all had adenomas; their 5-year survival rate was 100% [23].

Microscopic features suggestive of malignancy include nuclear atypia, atypical and/or frequent mitoses, vascular and capsular invasion, and necrosis [13]. Ki67 staining can be helpful to differentiate benign from malignant lesions. It is also used in prognosis: patients with a high mitotic rate (> 10%) have a poor prognosis [13,19]. Other microscopic features suggestive of ACC are IGF-II overexpression, allelic loss on chromosome 17p13, and high levels of cyclin E [13].

TREATMENT

Most patients with ACC present with locally advanced or metastatic tumors. The only curative therapy is complete surgical resection when tumors are small and localized. Complete surgical resection allows the best prognosis; an en bloc resection of the tumor, and surrounding structures if indicated, is recommended [1,2,13]. If local invasion or metastasis has not occurred, it is difficult to define malignancy on histologic examination. Predictors of poor survival after resection include lesions larger than 12 cm, 6 or more mitotic figures per 10 high-power fields on microscopy, and tumor hemorrhage [1].

Whether or not a laparoscopic adrenalectomy is appropriate for patients with ACC is the subject of debate. An open procedure is still the standard of care for patients whose tumors are larger than 10 cm, whose lymph nodes are enlarged, or who have local tissue invasion. However, for patients with small tumors and no obvious features of malignancy, a laparoscopic adrenalectomy may be considered [2].

For patients with metastatic or unresectable tumors, systemic therapy should be considered rather than surgery. Table 6 shows different chemotherapy regimens for ACC. Surgical debulking should not be routinely performed, but may be considered for patients with severe symptoms of hormone excess [2].

Patients with locally advanced or metastatic ACC should be considered for enrollment in a clinical trial. Unfortunately, ACC is aggressive and nearly always lethal, and no treatment regimen has proved curative. Traditionally, mitotane (ortho, para, dichloro-, diphenyl-, dichloroethane), an adrenal specific agent that causes focal degeneration of the fascicular and reticular zone cells, was used as monotherapy [4]. It is cytotoxic, causing oxidative damage and impairing steroidogenesis [2]. In most patients, it successfully controls hormone excess (both in patients with ACC who have hypercortisolism and in patients with benign causes of hypercortisolism) [24], but has only a partial response rate of 19% to 34% and only an anecdotal complete response for tumor regression [25]. Treatment with mitotane is usually limited by its side effects, such as diarrhea, nausea, anorexia, hepatotoxicity, lethargy, somnolence, ataxia, dizziness, confusion, hypercholesterolemia, impotence, decreased platelet function, and leukopenia. It also induces adrenal insufficiency, so most patients require glucocorticoid and mineralocorticoid replacement [2,13].

The limited success of standard chemotherapy in patients with ACC is thought to be due to the multidrug-resistance gene MDR1, which is expressed by ACC cells [2,25]. MDR1 increases levels of P-glycoprotein (which acts as a drug efflux pump) and reduces the efficacy of chemotherapy [25]. Currently, MDR1 is considered another way of targeting treatment, but is still under investigation [2]. In patients who did not respond to mitotane, doxorubicin was tried as monotherapy; however, the response rate was only 12% to 19%, so its use was abandoned. Of historical interest, several other drugs (suramin and gossypol) were each attempted as monotherapy, but their toxicity and the poor response rate made them obsolete [26].

Unlike monotherapy, multidrug therapy has shown some promise in patients with ACC [2]. The 2 most popular regimens are the Berruti/Italian and Khan regimens [4,13]. The Berruti/Italian regimen combines etoposide (100 mg/m² on days 5, 6, and 7), doxorubicin (20 mg/m² on days 1 and 8), cisplatin (40 mg/m² on days 1 and 9, given every 4 weeks), and mitotane (up to 4 g/day orally). One study found some disease regression in 48% of patients, while almost 7% had a complete response. Moreover, 67% of patients had a hormonal response. In that study, 28% of patients had stable disease; 22%, disease progression. The most common side effect of the Berruti/Italian regimen was neutropenia; others included gastrointestinal symptoms, asthenia, myalgia, and neurologic symptoms [25].

The Khan regimen uses streptozocin (1g daily for 5 days, then 2 g every 3 weeks) and mitotane (up to 4 g daily); its complete or partial response rate is 36% [4,13,27]. Common side effects of streptozocin are gastrointestinal toxicity, increased creatinine levels, and reduced creatinine clearance [28]. In one study, a group of patients in whom the Khan regimen failed were then given another treatment regimen, this time consisting of vincristine (1.5 mg/m² on day 1), cisplatin (100 mg/m² on day 2), teniposide (150 mg/m² on day 4, repeated every 4 weeks), and cyclophosphamide (600 mg/m²). Side effects of the Khan regimen included alopecia, peripheral neuropathy, renal toxicity, ototoxicity, neutropenia, anemia, and gastrointestinal symptoms. Of 11 patients in that study, 1 had a partial response, 2 had a progression-free interval, 6 had stable disease, and 2 had disease progression (with one death before the defined evaluation time) [17].

Subsequently, Fassnacht et al ran a randomized control trial known as the Firm-Act (First International Randomized Trial in Locally Advanced and Metastatic Adrenocortical Carcinoma Treatment) to compare the two treatment

regimens. Patients who had received etoposide, doxorubicin, cisplatin, and mitotane (EDP-mitotane group, comparable to the Berruti regimen) had a 23.2% response, with a 5.0 month median duration of progression-free survival. While patients who received streptozocin and mitotane (comparable to the Khan regimen) had a 9.2% response and a 2.1 month progression free survival. Those who received EDP- mitane had a 26.1% 1 year survival, versus 7.2% for the streptozocin-mitotane group. The Firm-Act results suggest that EDP-mitotane regimen has superior antitumor efficacy, although these patients still have a poor overall survival [29].

Other drug combinations have been attempted in patients with ACC, but with limited success. In one study, a combination of cisplatin and mitotane yielded a response rate of 30% [25]. In another, a combination of cisplatin and etoposide had some efficacy, also with a response rate of 30%; the addition of mitotane improves the response rate only slightly (to 33%) [26].

Van Slooten et al. used a regimen of cyclophosphamide, doxorubicin, and cisplatin in 11 patients with metastatic disease. The partial response rate was 18% [30].

Schlumberger et al. used a regimen of 5-fluorouracil (5-FU), doxorubicin, and cisplatin in 14 patients with metastatic ACC. The partial response rate was 23%, with 1 complete response [31].

Hesketh et al. used a regimen of cisplatin, etoposide, and bleomycin in 4 patients with ACC. Initially, 1 had a complete response and 2 had a partial response, but all patients experienced disease recurrence and died [32].

Currently, the National Cancer Institute has 16 trials that accept patients with ACC, 5 testing chemotherapy regimens solely for ACC. Drugs being tested include the following, either individually or in combination: cisplatin, mitotane, sorafenib, paclitaxel, antineoplastons, and axitinib [33].

Experimental prospects for the treatment of ACC include immunotherapy, which is currently in use for a variety of other cancers and may be helpful in treating adrenal cancers. Some studies suggest that cytotoxic adenovirus could be beneficial, as could other retroviral vectors and interference RNA technology. Many in vitro studies have shown this effect, but none in patients with ACC [19]. Other targets for treatment include IGF-2 inhibitors like figitumumab OSI-906. Figitumumab is an anti-IGF-1R monoclonal antibody, and OSI-906 is a small molecule

tyrosine kinase inhibitor directed against IGF-1R. Both have shown some partial responses in phase I trials, although more research is currently being conducted. Other prospects include m-tor inhibitors, antiogenesis/VEGF inhibitors, tyrosine kinase inhibitors, and PPAR- γ antagonists. Additional targets for research include MDR/P-glycoprotein (to prevent drug resistance), Wnt/ β -catenin pathway (as these proteins also lead to ACC), steroidogenic factor-1 (to decrease adrenal proliferation) and estrogen pathways (to decrease aromatase overexpression) [34].

Medication regimens have been used to control the hormone excess associated with ACC. Ketoconazole, metyrapone, aminoglutethimide, mifepristone, and etomidate can all be used for this purpose [2,26].

Table 6a

Medical treatments

Type	Reference	Class of drug: function	Response rate	Side effects
Mitotane (o,pDDD)	Kasperlik-Zaluski 2000, Beruti 2005, Allolio 2006, Kuruba 2008, Patalano 2009	Cytotoxic: impairs adrenal steroidogenesis	19% to 34% partial response, anecdotal complete response	Nausea, vomiting, diarrhea, anorexia, mucositis, lethargy, somnolence, vertigo, ataxia, confusion, depression, dizziness, decreased memory, polyneuropathy, many others
Doxorubicin	Ahlman 2001, ACS website 2009	Anthracycline antibiotic: slows growth	12% to 19% partial response	Leukopenia, thrombocytopenia, hair loss, anorexia, nausea, vomiting, skin darkening, ulceration, EKG changes, CHF, tumor lysis

Table 6b

Medical treatments

Cisplatin Mitotane	Beruti 2005, ACS website 2009	Platinum compound: alkylating agent See above	30%	Pancytopenia, renal failure, electrolyte imbalances, neuropathy, edema, taste changes, vertigo, hair loss, seizures, chest pain See above
Cisplatin Etoposide	Ahlman 2001, ACS website 2009	See Above Alkaloid: blocks action of topoisomerase II	30%	See above Anemia, thrombocytopenia, nausea, vomiting, anorexia, hypotension, oral ulcers, hair loss, rash, numbness
Cisplatin Etoposide Mitotane	Ahlman 2001, ACS website 2009	See above	33%	See above

Table 6c

Medical treatments

Beruti Italian regimen: Mitotane Cisplatin Etoposide Doxorubicin	Beruti 2005	See above	48% partial response, 7% complete response, 28% stable disease, 22% disease progression	See above
Khan regimen: Mitotane Streptozocin	Khan 2000, Kuruba 2008, Patalano 2009, Pharma professional 2011	See above Anti-neoplastic antibiotic	36%	See above GI bleeding, confusion, pulmonary fibrosis, increased ICP, MI, bone marrow suppression, renal failure, liver failure, intestinal perforation, nausea, vomiting, alopecia, diarrhea, fever, rash, hypotension, tremor, ulcers, paresthesia

Table 6d

Medical treatments

Vincristine	Khan 2004,	Vinca alkaloid	9% partial response	Alopecia, nausea, vomiting, fatigue, diarrhea, dysgeusia, pancytopenia, constipation, numbness and tingling, oral sores, rash, hearing loss
Cisplatin	ACS website			
Temiposide	2009			
Cyclophosphamide		See above		See above
		Podophylotoxin		Pancytopenia, mouth sores, alopecia, nausea, vomiting, diarrhea, hypotension, infection, bleeding, second malignancy
		Alkylating agent		Neutropenia, nausea, vomiting, oral sores, diarrhea, hematuria, infections, acne, cardiac toxicity, rash, allergic reactions, pulmonary fibrosis

patients with ACC [2]. Despite the previous notion that ACC was not radiosensitive, success in controlling locally advanced disease has been reported (a 57% partial response rate) [21]. For patients with bone and brain metastasis, radiation therapy is currently the treatment of choice [2]. In one study of patients who underwent surgery alone vs. patients who underwent both surgery and radiation, those who also underwent radiation had a much lower local recurrence rate (12%) than those who underwent surgery alone (12%). However, disease-free and overall survival rates were not affected [35]. The best use of radiation for ACC is probable as adjuvant therapy to prevent local recurrence, especially in patients with residual microscopic disease after resection (R1 resection). Those with macroscopic disease are better treated by re-operation [34].

Currently, radiofrequency ablation (RFA) has been used for patients with other solid-organ tumors. RFA may be appropriate for patients whose ACC is not amenable to surgical resection [2]. Wood et al. performed RFA in patients whose ACC was either unresectable or had metastasized. Patients underwent imaging before, and then 4 to 12 weeks after RFA: 53% had regression of lesions, 27% had stable disease, and 20% had disease progression. RFA was more beneficial if the lesions were < 5 cm (67% response rate) [36]. Despite such favorable preliminary results, RFA is still under investigation [2,36].

Hahner et al studied [131I] Iodometomidate radionuclide treatment for advanced ACC. This was a preliminary case series of 11 patients. However, they did note one patient with a partial response and 5 with disease stabilization. The regimen was well tolerated by the patients and may be another therapeutic option after further studies [37].

FOLLOW-UP

Patients with ACC should be followed closely. For those with hormonally active disease, hormone markers should be evaluated every 2 to 3 months [2,19] for the first year, every 4 months the next year, and every 6 months in the ensuing years [19]. For patients who have undergone resection, follow-up CT should be performed every 3 months, in order to identify any disease recurrence early, when it may be amenable to resection.

PROGNOSIS

Prognosis depends on the cancer stage, the results of surgical resection, and the histologic tumor grade [38]. Mitosis is the most important prognostic feature per histologic testing.

Table 6e

Medical treatments

Cyclophosphamide	Van Slooten	See above	18% partial response	See above
Doxorubicin	1983			
Cisplatin				
5-Fluorouracil	Schlumberger	Antimetabolite	23% partial response	Neutropenia, thrombocytopenia, nausea, vomiting, oral sores, diarrhea, alopecia, dry skin
Doxorubicin	1991, ACS			
Cisplatin	website 2009	See above		See above
		See above		See above
Cisplatin	Hesketh	See above	25% complete response, 50% partial response	See above
Etoposide	1987, ACS			
Bleomycin	website 2009	See above		See above
		Antibiotic		Fever, nausea, vomiting, anorexia, alopecia, oral sores, skin changes, pulmonary fibrosis, thrombosis

Legend: ACS = American Cancer Society, CHF = congestive heart failure, EKG = electrocardiogram, GI = gastrointestinal, ICP = intracranial pressure, MI = myocardial infarction

Radiation therapy is another potentially useful treatment for

Tumors with more than 20 mitotic figures per 50 high-power fields on microscopy are considered to be high-grade and confer a median survival time of 14 months; in contrast, tumors with fewer than 20 mitotic figures per 50 high-power fields conferred a median survival time of 58 months [39]. Despite current therapies, ACC has a poor prognosis; the 5-year mortality rate is 70% to 85%. In fact, of patients who have initially undergone surgery for resectable disease, many have required repeat operations for disease recurrence [40]. In the future, gene profiling studies may be helpful in determining prognostic indicators [38].

CONCLUSION

ACC, though rare, can be difficult to treat. However, early diagnosis and full surgical resection as soon as possible may lead to better outcomes. Genetic mutations and syndromes put patients at higher risk for ACC, so screening may be beneficial in the future. In patients with advanced disease, mitotane and other chemotherapeutic agents can be helpful, but are seldom, if ever, curative. More research is needed to find agents that will induce complete responses.

ACKNOWLEDGEMENT

The authors would like to thank Mary Knatterud for her assistance editing the manuscript.

References

1. Dackiw APB, Lee JE, Gagel RF, Evans DB. Adrenal cortical carcinoma. *World J Surg*; 2001; 25: 914-926.
2. Allolio B, Fassnacht M. Clinical review: Adrenocortical carcinoma: clinical update. *J Clin Endocrinol Metab* 2006; 91: 2027-2037.
3. Hsing AW, Nam JM, Chien HTC, McLaughlin JK, and Fraumeni JF. Risk factors for adrenal cancer: An exploratory study. *Int. J. Cancer*, 1996; 65,432-436.
4. Patalano A, Brancato V, Mantero F: Adrenocortical cancer treatment. *Horm Res* 2009; 71 Suppl 1: 99-104.
5. Soon PS, McDonald KL, Robinson BG, et al. Molecular markers and the pathogenesis of adrenocortical cancer. *Oncologist* 2008; 13: 548-61.
6. Gonzalez KD, Noltner KA, Buzin CH, et al. Beyond Li Fraumeni syndrome: Clinical characteristics of families with p53 germline mutations. *J Clin Oncol* 2009; 27: 1250-1256.
7. Kleihues P, Schauble B, zur Hausen A, Esteve J, Ohgaki H. Tumors associated with p53 germline mutations. *Am J Pathol* 1997;150:1-13.
8. Herbet M, Feige JJ, Thomas M. Insights into the role of genetic alterations in adrenocortical tumorigenesis. *Mol Cell Endocrinol* 2009; 300: 169-74.
9. Tissier F, Cavard C, Groussin L, Perlemoine K, Fumey G, Hagnere AM, Rene-Corail F, Jullian E, Gicquel C, Bertagna X, Vacher-Lavenu MC, Perret C, Bertherat J. Mutations of b-catenin in adrenocortical tumors: Activation of the Wnt signaling pathway is a frequent event in both benign and malignant adrenocortical tumors. *Cancer Res* 2005; 65: 7622-7.
10. Libe R, Fratticci A, Bertherat J. Adrenocortical cancer: pathophysiology and clinical management. *Endocr Relat Cancer*. 2007; 14: 13–28.
11. Zhao J, Roth J, Bode-Lesniewska B et al.: Combined comparative genomic hybridization and genomic microarray for detection of gene amplifications in pulmonary artery intimal sarcomas and adrenocortical tumors. *Genes Chromosomes Cancer* 2002; 34:48-57.
12. Barlaskar FM, Hammer GD: The molecular genetics of adrenocortical carcinoma. *Rev Endocr Metab Disord* 2007; 8: 343-8.
13. Kuruba R, Gallagher SF. Current management of adrenal tumors. *Curr Opin Oncol* 2008; 20: 34-46.
14. Henry I, Grandjouant P, Barichard F, Huerre-Jeanpierre C, Glaser T, Philip T, Lenoir G, Chaussainii JL, Junien C. Tumor-specific loss of 11p15.5 alleles in del11p13 Wilms tumor and in familial adrenocortical carcinoma. *Proc Natl Acad Sci* 1989; 86: 3247-3251.
15. Guerrero MA, Kebebew E. Adrenocortical Carcinoma and Synchronous Malignancies. *J Cancer* 2010; 1: 108-111.
16. Jagelman DG. Extracolonic manifestations of familial polyposis coli. *Cancer Genet Cytogenet* 1987; 27: 319-325.
17. Khan TS, Sundin A, Juhlin C, Wilander E, Oberg K, Eriksson B. Vincristine, cisplatin, teniposide, and cyclophosphamide combination in the treatment of recurrent or metastatic adrenocortical cancer. *Med Oncol*. 2004; 21: 167-177.
18. Zeiger MA, Thompson GB, Duh QY, Hamrahian AH, Angelos P, Elaraj D, Fishman E, Kharlip J. American Association of Clinical Endocrinologists and American Association of Endocrine Surgeons Medical Guidelines for the Management of Adrenal Incidentalomas. *Endocr Pract* 2009; 15 (Suppl 1): 1-20.
19. Schteingart DE, Doherty GM, Gauger PG, et al. Management of patients with adrenal cancer: recommendations of an international consensus conference. *Endocr Relat Cancer* 2005; 12: 667-680.
20. Nunes ML, Rault A, Teynie J, Valli N, Guyot M, Gaye D, Belleannee, Tabarin A. 18F-FEG PET for the identification of adrenocortical carcinomas among indeterminate adrenal tumors at computed tomography scanning. *World J Surg* 2010; 34: 1506-1510.
21. Zini L, Propiglia F, Fassnacht M. Contemporary management of adrenocortical carcinoma. *Eur Urol* 2011; 60:1055-65.
22. Fassnacht M, Johanssen S, Quinkler M, Bucskey P, Willenberg HS, Beuschlein F, Terzolo M, Mueller H,

- Hahner S, Allolio B. Limited prognostic value of the 2004 International Union Against Cancer staging classification for adrenocortical carcinoma: Proposal for a revised TNM classification. *Cancer* 2009; 115:243-250.
23. Jain M, Kapoor S, Mishra A, Gupta S, Agarwal A. Weiss criteria in large adrenocortical tumors: a validation study. *Indian J Pathol Microbiol* 2010; 53: 222-226.
24. Kasperlik-Zaluski AA. Clinical results of the use of mitotane for adrenocortical carcinoma. *Braz J Med Biol Res*, 2000; 33: 1191-1196.
25. Berruti A, Terzolo M, Sperone P, Pia A, Della Casa S, Gross DJ, Carnaghi C, Casali P, Porpiglia F, Mantero F, Reimondo G, Angeli A, Dogliotti L. Etoposide, doxorubicin and cisplatin plus mitotane in the treatment of advanced adrenocortical carcinoma: a large prospective phase II trial. *Endocr Relat Cancer*. 2005; 12: 657–666.
26. Ahlman H, Khorram-Manesh A, Jansson S, Wangberg B, Nilsson O, Jacobsson CE, Lindstedt S. Cytotoxic treatment of adrenocortical carcinoma. *World J Surg.*, 2001; 25: 927-933.
27. Khan TS, Imam H, Juhlin C, Skogseid B, Grondal S, Tibblin S, Wilander E, Oberg K, Eriksson B. Streptozocin and o,p'DDD in the treatment of adrenocortical cancer patients: Long-term survival in its adjuvant use. *Ann Oncol*. 2000; 11: 1281-1287.
28. Jani P, Nasr AL, Demellawy DE. Synchronous renal cell carcinoma and adrenocortical carcinoma: a rare case report and clinicopathologic approach. *Can J Urol* 2008; 15: 4016-4019.
29. Fassnacht M, Terzolo M, Allolio B, Vaudin E, Haak H, Berruti A, et al. Combination chemotherapy in advanced adrenocortical carcinoma. *N Engl J Med*. 2012; 366: 2189-2197.
30. Van Slooten H, Van Osterom AT. CAP (cyclophosphamide, doxorubicin and cisplatin) regimen in adrenal cortical carcinoma. *Cancer Treat Rep* 1983; 67:377-380.
31. Schlumberger M, Brugieres L, Gicquel C, Travagli JP, Droz JP, Parmentier C. 5-Fluorouracil, doxorubicin and cisplatin as treatment for adrenal cortical carcinoma. *Cancer* 1991; 67: 2997-3000.
32. Hesketh PJ, McCaffrey RP, Finkei HE, Lamon SS, Griffing GT, Melby JC. Cisplatin based treatment of adrenocortical carcinoma. *Cancer Treat Rep* 1987; 71: 2221-2225.
33. National Cancer Institute. Clinical trials search results: adrenocortical carcinoma.