

# A Prospective Study Of Liver Abscesses: Clinical Profile And Management Of 100 Cases Admitted In A Single Surgical Unit Of The SMS Hospital In Jaipur, India

P Malik, H N Lakshmi, M Rathi, D Saini, R Arya

## Citation

P Malik, H N Lakshmi, M Rathi, D Saini, R Arya. *A Prospective Study Of Liver Abscesses: Clinical Profile And Management Of 100 Cases Admitted In A Single Surgical Unit Of The SMS Hospital In Jaipur, India*. The Internet Journal of Infectious Diseases. 2014 Volume 13 Number 1.

DOI: [10.5580/IJID.16121](https://doi.org/10.5580/IJID.16121)

## Abstract

Evolution in diagnostics and treatment methodology has resulted in marked reduction in morbidity and mortality associated with liver abscess. Today with improved antibiotics and operative techniques, we could achieve much better response in patients with liver abscess. The presenting features, modes of treatment and clinical course were reviewed for 100 patients with liver abscess, seen in a single surgical unit at the SMS Hospital over one and a half year period. The aim of the study was to review the demographic data, aetiologies, investigations and to formulate the management plan of liver abscess patients.

## INTRODUCTION

In tropical countries like India, liver abscess is a common problem and remains a diagnostic and therapeutic challenge for the treating physician. If left untreated, the disease may turn lethal. Wide spectrum of clinical features are seen depending on the type and size of the abscess and its associated complications. Initially, open surgical drainage was recommended as the treatment of choice. Better imaging along with ultrasound-guided percutaneous needle aspiration and drainage has brought dramatic changes in the pattern of treatment for liver abscess.

## METHODOLOGY

We studied a total of 100 patients, who presented with liver abscess from July 2012 until December 2013 in our single surgical unit of department of general surgery at the SMS Hospital. The clinical presentation, microbiological and radiological findings were recorded. Data included age, gender, presenting symptoms, comorbidities, underlying etiology, radiological findings focused on the size and number of abscesses and microbiological findings. Biochemical investigations included hemoglobin, total leukocyte count, serum creatinine, C-reactive protein, total bilirubin, albumin and liver enzymes. Blood culture and pus culture reports were noted.

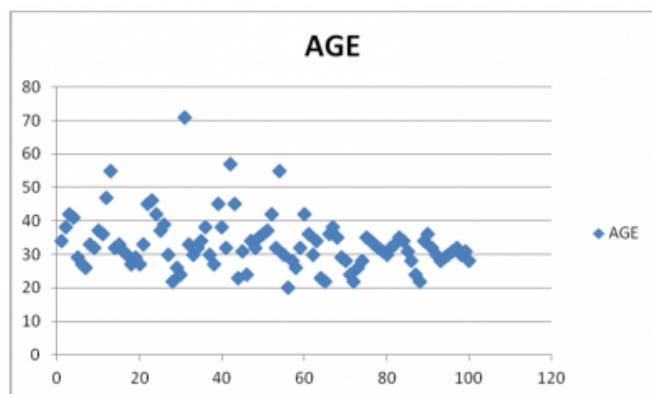
Less than 5cm abscesses were managed conservatively using parenteral antibiotics, while those over 5 cm size were aspirated percutaneously or required drainage. Intravenous Metronidazole 500 mg 8 hourly with Ceftriaxone 1 grams two times a day were administered parenterally to all patients. Metronidazole was given for a period of 14 days. Failure of treatment was defined as persistent infection after 5 days of treatment. Open surgical drainage was done in patients with abscesses larger than 10 cm or those with ruptured liver abscess. Follow-up imaging with USG was performed for all patients. Cure was defined as resolution of the clinical symptoms at 2 months after initiating treatment. Mortality was defined as patients dying within 30 days of diagnosis.

## RESULTS

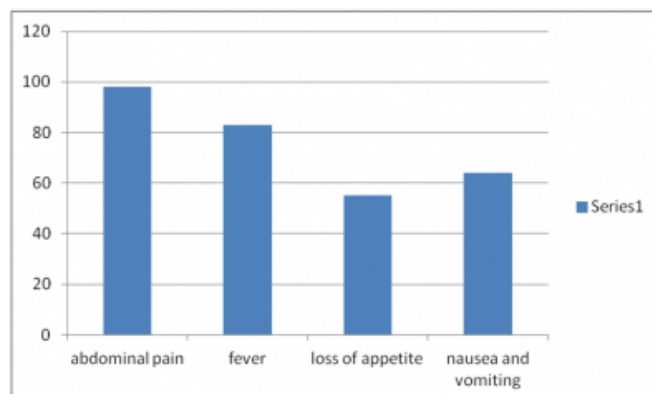
### Age and sex wise distribution:

Mean age of presentation of patients with liver abscess in our study was 33.17 years with minimum age being 20 years and maximum age being 71 years. Liver abscess predominantly affected males with a male : female ratio of 24:1.

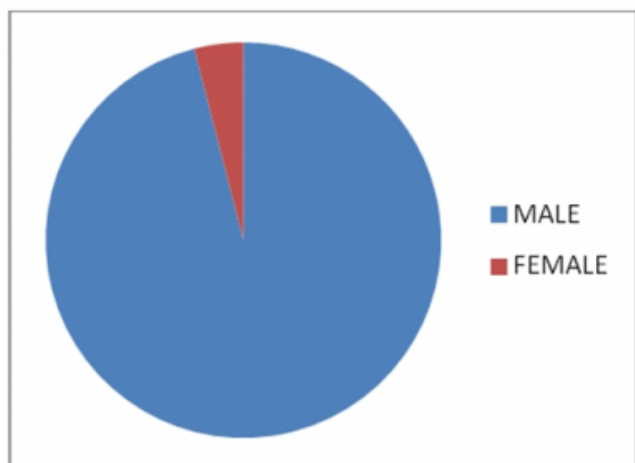
**Figure 1**



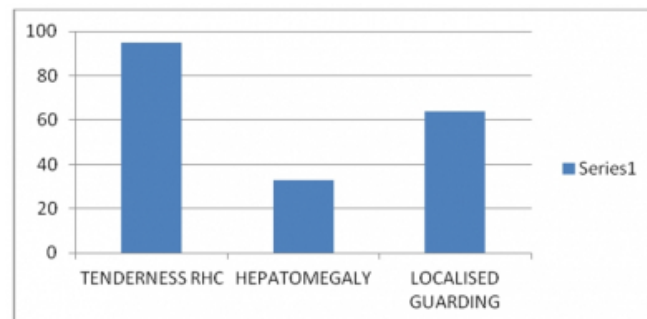
**Figure 3**



**Figure 2**



**Figure 4**



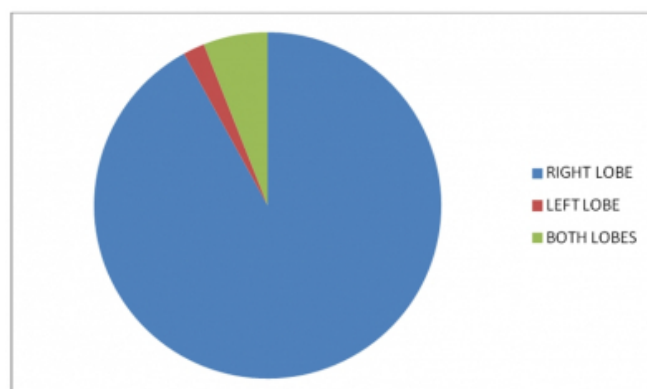
#### Symptomatology :

Abdominal pain (98%), fever (83%), loss of appetite (55%), nausea and vomiting (64%) were predominant symptoms. Signs which were mainly found in patients were tenderness in the right hypochondrium (95%), hepatomegaly (33%), and localised guarding (64%).

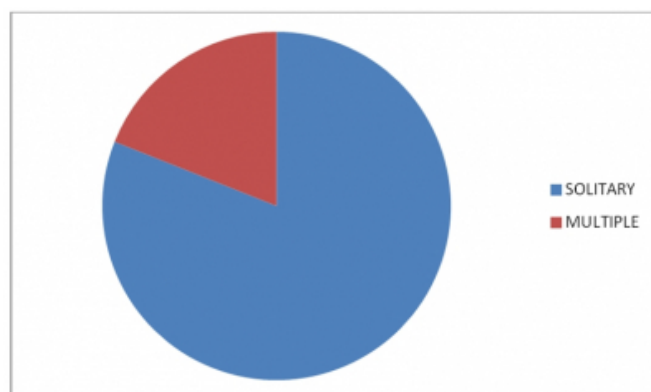
#### Ultrasonography:

Liver abscesses mainly affected the right lobe (92%) of liver whereas the left lobe (2%) and both lobes (6%) were affected in the minority of the cases. The majority of the cases had a solitary abscess cavity (81%) while multiple abscess cavities were present in 19% of the cases. The mean size of a liver abscess was found to be 7.03 cm with the smallest being 3 cm and the largest abscess being 13 cm.

**Figure 5**



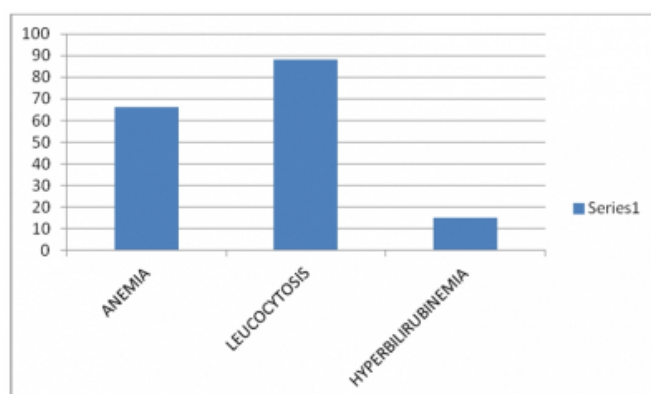
**Figure 6**



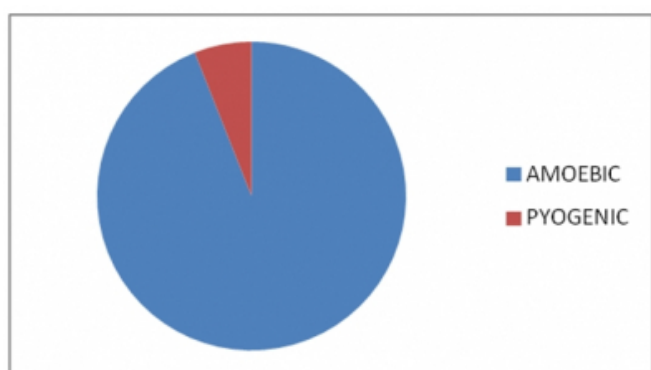
Laboratory investigations:

Blood investigation revealed mean haemoglobin of 9.7gm/dl. Of all cases, 66% of the patients were anaemic, 88% had leucocytosis and 15% showed hyperbilirubinemia. 94% of the cases were diagnosed to have an amoebic liver abscess and only 6% had a pyogenic abscess.

**Figure 7**



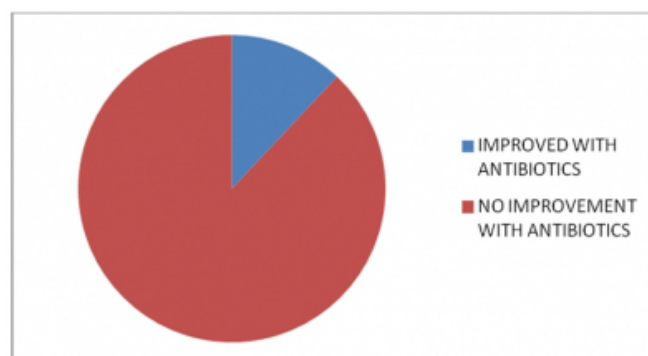
**Figure 8**



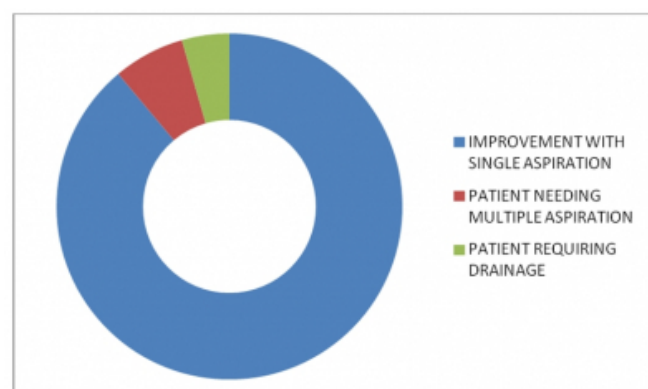
Management:

Only 12 % of the patients improved with antibiotic therapy, 88% showed no improvement with antibiotics alone. Of those who showed no improvement, 80% of the cases improved with single aspiration, 5 patients required aspiration twice and one needed a third aspiration. 3 patients underwent open drainage and for one case, we performed laparoscopic drainage.

**Figure 9**



**Figure 10**



Complications:

5 liver abscesses ruptured into the pleural cavity and 3 ruptured into the peritoneal cavity. One 71 year old male patient with liver abscess expired following rupture into the peritoneal cavity.

**DISCUSSION**

Liver abscesses, in particular amoebic liver abscesses, appears to be a major disease in developing countries. ALA is the most common extraintestinal manifestation of E. Histolytica infection. In this study, it was found that majority of patients were from low socioeconomic class. The majority of patients were middle aged males falling into the age group of 30-40 years, followed by patients in the age group of

20-30 years, a male to female ratio of 24:1 was recorded. Mehta et al (1986) reported a male preponderance of 15:1 (1). In a study by Lee K C et al, patients were mainly in 30-50 years age group with range of 21-79 years.(2)

41% of the patients in our study group had history of alcohol intake, which was supported by the hypothesis of Seeto R.K. et al(1999). He said that alcohol may play a role in impairing Kupfer cell function or by impairing both cellular and humoral immunologic responses, thereby predisposing liver to infections. (3)

While studying the clinical features, abdominal pain (98%), fever (83%), loss of appetite (55%), nausea and vomiting (64%) were predominant symptoms. Signs which were mainly found in patients were tenderness (95%), hepatomegaly (33%) & localised guarding (64%). Reed et al (2001) studied ALA and found that the most common clinical features were epigastric and right hypochondriac pain followed by nausea and vomiting. (4)

Chest X ray revealed the findings suggestive of pleural effusion or elevated right hemidiaphragm in about 49% of the patients. On imaging, liver abscesses mainly affected the right lobe (92%). The majority of the cases had a solitary abscess cavity (81%) while multiple abscess cavities were present in 19% of the cases. The mean size of a liver abscess was found to be 7.03 cm with the smallest being 3 cm and largest abscess being 13 cm. The majority of samples for abscess cultures were sterile (83%). This could be attributed to the early use of empirical antibiotics in the present study.

Intravenous antibiotics were given to all the patients and this was the only treatment for 12 patients (12%). The most commonly used antibiotics were third-generation cephalosporins with metronidazole. If antimicrobial sensitive antibiotics are given for 4–6 weeks; according to of the cultured microorganism, it can be curative for abscesses measuring less than 5 cm in diameter.(5)

Percutaneous needle aspiration in combination with systemic antibiotics is safe and effective treatment, and it should be considered as first-line treatment (6). This mode of management is highly appreciable in our study. Of those who showed no improvement with antibiotics alone, 80% cases improved with single aspiration, 5 patients required aspiration twice and one needed a third aspiration. Yu and colleagues performed a randomized trial involving 64 patients with pyogenic liver abscess. They concluded that percutaneous needle aspiration was probably as effective as

continuous percutaneous catheter drainage.(7) Needle aspiration is less invasive and has the advantage to drain multiple liver abscesses in single session.

Surgical exploration and open drainage of liver abscess was performed in cases presenting with intraperitoneal rupture of liver abscess. 3 patients underwent open drainage and for one case, we did a laparoscopic drainage. In a study by Mohammad Aslam et al., they performed surgical intervention in 7.14% of the patients which was slightly higher as compared to our study. (8)

The low mortality rate (1%) in our study can be explained by the early detection and prompt management by the USG-guided percutaneous techniques. The mortality rate in developed countries ranges from 2 to 12%. Risk factors for mortality includes open surgical drainage, presence of malignancy and presence of anaerobic infection (9,10).

## CONCLUSION

Liver abscess is a common problem in middle age alcoholic men of developing countries. Amoebic liver abscess is much more common than pyogenic abscess. Percutaneous treatment combined with antibiotics is a safe and effective treatment for liver abscess. Surgery should be done in patients with severe sepsis or with more than 10 cm abscesses. The marked reduction in the morbidity and mortality of liver abscess can be attributed to early diagnosis which permitted timely intervention, better choice of antibiotics with improved intensive unit care.

## References

1. Mehta RB, Parija SC, Chetty DV et al : Management of 240 cases of liver abscess. *int. Surg.* 1986;71:91-94
2. Lee KC, Yamazaki O, Hamba H, Sakaue Y, Kinoshita H, Hirohashi K, Kubo S. Analysis of 69 patients with liver abscess. *j.gastroenterol* 1996;feb;31(1);40-5
3. Seeto RK, Rockey DC: amebic liver abscess: epidemiology, clinical features and outcome. *West j med* 1999;170:104-109
4. Reed SL. Amebiasis: An update. *Clin Inf Dis* 1992;14: 385-393. 43.
5. Lok KH, Li KF, Li KK, Szeto ML. Pyogenic liver abscess: clinical profile, microbiological characteristics, and management in a Hong Kong hospital. *J Microbial Immunol Inf.* 2008;41:483–490.
6. Ch Yu S, Hg Lo R, Kan PS, Metreweli C. Pyogenic liver abscess treatment with needle aspiration. *Clinical Radiol.* 1997;52:912–916. doi: 10.1016/S0009-9260(97)80223-1.
7. Yu SC, Ho SS, Lau WY, et al. Treatment of pyogenic

liver abscess: prospective randomized comparison of catheter drainage and needle aspiration. Hepatology. 2004;39:932–938. doi: 10.1002/hep.20133.

8. Bugti QA, Baloch MA, Wadood AU, Mulghani AH, Azeem B, Ahmed J. Pyogenic liver abscess: demographic, clinical, radiological and bacteriological characteristics and management strategies. GJMS. 2005;3:1.

9. Chen SC, Huang CC, Tsai SJ, et al. Severity of disease as main predictor for mortality in patients with pyogenic liver abscess. Am J Surg. 2009;198:164. doi: 10.1016/j.amjsurg.2008.08.022.

10. Lok KH, Li KF, Li KK, Szeto ML. Pyogenic liver abscess: clinical profile, microbiological characteristics, and management in a Hong Kong hospital. J Microbiol Immunol Infect. 2008;41:483.

**Author Information**

**Puneet Malik, JR3**

SMS Medical College And Hospital  
Jaipur, India

**Harish Neelamraju Lakshmi, JR3**

SMS Medical College And Hospital  
Jaipur, India

**Mahendra Rathi, JR3**

SMS Medical College And Hospital  
Jaipur, India

**Devendra Saini, JR3**

SMS Medical College And Hospital  
Jaipur, India

**Rajveer Arya, Professor And Unit Head**

SMS Medical College And Hospital  
Jaipur, India