

# Crossed Versus Lateral Pinning In The Treatment Of Displaced Extension-Type Supracondylar Fractures Of The Humerus: A Prospective Study

S Singh, D R Pai, A Kaur, H H Soe

## Citation

S Singh, D R Pai, A Kaur, H H Soe. *Crossed Versus Lateral Pinning In The Treatment Of Displaced Extension-Type Supracondylar Fractures Of The Humerus: A Prospective Study*. The Internet Journal of Orthopedic Surgery. 2013 Volume 21 Number 2.

## Abstract

Supracondylar fracture is one of the most common elbow injuries in children. The most common type is extension-type (95%)(1). The commonly used classification system based on degree of displacement is Gartland classification (2) i.e. Type I-undisplaced, type II – displaced with intact posterior cortex, and type III – displaced with no cortical contact. Every orthopaedician will be confronted with a supracondylar fracture with or without complication, during his clinical practice. The association of this fracture with neurovascular complications and deformity warrants an aggressive approach for management. Even an apparently uncomplicated fracture may lead to local swelling, deformity and neurovascular complications if not treated properly.(3)(4)(5)(6)(7)(8) These fractures demand an accurate assessment and precise planning in the mode of treatment.(3)An anticipation of likely complications is mandatory to diagnose and manage them properly. Percutaneous pinning after closed reduction under fluoroscopic guidance is now the treatment of choice for most of the displaced supracondylar fractures of the humerus in children.(9)(10)(11) Commonly two pinning techniques have been used i.e. lateral and crossed medial and lateral pinning techniques. However, which pin configuration is better is a topic of debate. The purpose of our study was to evaluate and compare the two pinning techniques in terms of functional outcome and complications if any, in children with supracondylar fractures of humerus in a rural population.

## INTRODUCTION

Supracondylar fracture is one of the most common elbow injuries in children. The most common type is extension-type (95%)(1). The commonly used classification system based on degree of displacement is Gartland classification (2) i.e. Type I-undisplaced, type II – displaced with intact posterior cortex, and type III – displaced with no cortical contact. Every orthopaedician will be confronted with a supracondylar fracture with or without complication, during his clinical practice. The association of this fracture with neurovascular complications and deformity warrants an aggressive approach for management. Even an apparently uncomplicated fracture may lead to local swelling, deformity and neurovascular complications if not treated properly.(3)(4)(5)(6)(7)(8) These fractures demand an accurate assessment and precise planning in the mode of treatment.(3)An anticipation of likely complications is mandatory to diagnose and manage them properly. Percutaneous pinning after closed reduction under fluoroscopic guidance is now the treatment of choice for

most of the displaced supracondylar fractures of the humerus in children.(9)(10)(11) Commonly two pinning techniques have been used i.e. lateral and crossed medial and lateral pinning techniques. However, which pin configuration is better is a topic of debate.

The purpose of our study was to evaluate and compare the two pinning techniques in terms of functional outcome and complications if any, in children with supracondylar fractures of humerus in a rural population.

## PATIENTS AND METHODS

The study was designed as a prospective clinical trial. Approval from the College ethics committee was taken. Written informed consent was taken from the parents of patients. 32 patients of age group 3-14 years with displaced extension-type supracondylar fractures of humerus admitted to Rural Medical College and Hospital (RMCH), Loni, Maharashtra, India from August 2004 to January 2007 were included in the study. Children with undisplaced fracture, flexion type supracondylar fractures, open fracture,

associated ipsilateral limb fractures and previous ipsilateral elbow injury were excluded from the study. All patients were treated with closed reduction and percutaneous pinning, which was either lateral or crossed pinning according to the preference of the operating surgeon. There were 21 boys and 11 girls with mean age of 7.46 years. Based on Gartland classification (2), 27 were type II and 5 were type III fractures. None of the patients had any neurovascular injury at presentation. All the patients were given an above elbow slab on admission and were operated within twenty four hours. The choice of pinning (K-wire) construct was left to the operating surgeon. The operating surgeons were senior registrar level with more than three years post masters experience.

All the patients were operated under general anaesthesia. Slab was opened in the OT. Closed reduction was done using the standard technique described by Rockwood and Wilkins (2006). (12) Reduction was confirmed under the image intensifier in both anteroposterior and lateral planes. The configuration and size of the K-wire (pins) used were decided by the operating surgeon.

For lateral pinning technique, after reduction evaluation, two pins were inserted from the lateral aspect of the elbow. The pins were parallel or divergent and engaged the medial cortex. The elbow was kept hyperflexed and in a position of pronation for inserting the lateral pins. The elbow was then extended fully and fracture reduction and stability assessed clinically as well as radiologically under image intensifier. For cross pinning technique, after reduction evaluation, the lateral pin was inserted first, similar to the manner for lateral pinning technique. The elbow was then extended to less than 90° position and a medial pin was inserted. For medial pin insertion the surgeon palpated the ulnar nerve and pushed it posteriorly with the thumb. Two patients required a separate incision over the medial epicondyle to explore the ulnar nerve. The fracture reduction and stability was assessed clinically as well as radiologically under image intensifier. The excess length of the pins was cut and then bent outside the skin to avoid migration. Betadine roller-gauze dressing was applied to avoid pin track infection. A below elbow plaster slab was applied with the elbow in 90° flexion and full supination of forearm.

All patients were discharged after two days. They were followed up for clinical evaluation (carrying angle, elbow range of motion, neurovascular complications and pin tract infections) and radiological evaluation (fracture displacement, Baumann angle, humero-capitellar angle) at three to four weeks and final follow up at six months. The

pins and slab were removed after three to four weeks. Active elbow 'range of motion' exercises were encouraged. At the end of six months period, Flynn's criteria (13) were used to grade the result. Results were graded as excellent, good, fair and poor. [Table I]

**Table I**

Grading of results according to Flynn's criteria (13)

	Cosmetic factor loss of carrying angle (degrees)	Functional factor Loss of movement (degrees)
Excellent	0° - 5°	0° - 5°
Good	5° - 10°	5° - 10°
Fair	10° - 15°	10° - 15°
Poor	>15°	>15°

Based on Flynn's criteria, the final outcome was compared between the two pinning techniques groups. The data was analysed using SPSS version 13.0. Descriptive statistic such as frequency, percentage, mean and standard deviation was used. Chi square test and Fisher's exact test was done to compare categorical data and independent sample T test was used to compare continuous data between two groups. Level of significance was set as 0.05.

## RESULTS

A total of 32 patients were enrolled in this study. 17 of them were treated with lateral pinning and 15 with cross pinning technique based on surgeon's preference. There were no significant differences of baseline characteristics such as age, gender and types of fracture between two groups. (Table 2) The mean period of fracture union was 4.09 weeks.

**Table 2**

Baseline characteristics of patients received either lateral pinning or cross pinning (n = 32)

Baseline characteristics	Lateral (n=17)	Cross (n=15)	t / $\chi^2$	p-value
Age#	7.06 ± 3.152	7.93 ± 3.283	-0.768	0.448
Gender†				
Male	11 (64.7)	10 (66.7)	0.014	0.907
Female	6 (35.3)	5 (33.3)		
Classification†				
Type II	14 (82.4)	13 (86.7)	-	1.0
Type III	3 (17.6)	2 (13.3)		

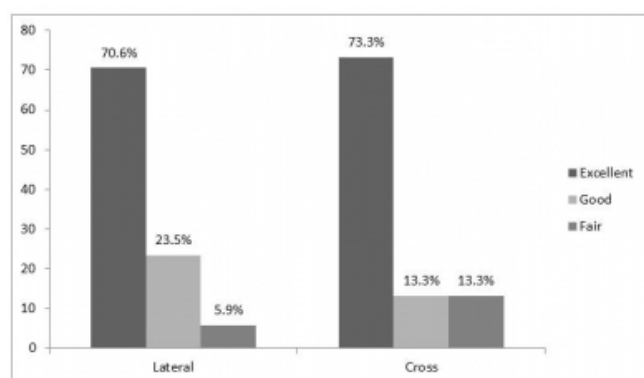
# Independent sample T test, † Chi-square test, ‡ Fisher's Exact test

Patients were evaluated by recording the outcome measures

using Flynn's criteria. Among patients treated with lateral pinning technique, 12 (70.6%) had excellent outcome, 4 (23.5%) had good outcome while 1 (5.9%) had fair outcome. No patient had a poor outcome. Similarly in patients treated with cross pinning technique, 11 (73.3%), 2 (13.3%) and 2 (23.3%) had excellent, good and fair outcomes respectively (Figure 1). Three patients developed superficial pin tract infections which were treated successfully with regular dressings and oral antibiotics. No patient developed any iatrogenic ulnar nerve injury in the cross pinning group. Overall, no patient developed any neurovascular complications during the treatment and follow up period. Figure 1 shows the outcome based on Flynn's grading in patients receiving lateral pinning and crossed pinning. There was no significant difference of proportion of excellent, good and fair between patients receiving lateral pinning and crossed pinning.

**Figure 1**

Outcome in patients receiving either lateral pinning or crossed pinning based on Flynn's grading



Fisher's Exact test, p-value = 0.662, 0.539

## DISCUSSION

Supracondylar fractures of humerus are the most common fractures around the elbow in children.(14)(15) These fractures are notoriously associated with neurovascular complications.(4)(5)(16)(17)(8) Aggressive and appropriate treatment is advised to avoid serious complications. Gartland Type I fractures can be adequately treated by immobilization in above elbow cast.(17)(18) There exists controversy regarding the optimal treatment for displaced supracondylar fracture (Gartland type II & type III). Various treatment methods have been described for displaced supracondylar fractures of humerus in children i.e. traction; closed reduction and casting; closed reduction and percutaneous pinning; and open reduction and pinning.

Parikh et al. recommended closed reduction and casting for treatment of extension type II supracondylar fractures.(19) Lateral cross pinning technique (Dorgan's Technique) is also favoured by some authors.(20)(21)(22) However, we don't have any experience with this technique. In a study, Weinberg et al. developed a biomechanical model to compare four osteosynthesis techniques for management of supracondylar fracture and found that external fixators are a good alternative to cross pinning if the fracture reduction is difficult due to swelling.(23) Fahmy et al. described a posterior intrafocal pinning technique for extension supracondylar fractures of humerus.(24) Li et al. described a mini invasive technique using mosquito forceps for reduction of severely displaced supracondylar fractures.(25) Our hospital, where this study was conducted caters to a rural population from surrounding villages. Here keeping the patients in hospital for long or calling for follow up is difficult and economically unviable for the patient. Hence we chose primary fixation with 'k' wires for displaced (Type II & Type III) supracondylar fractures of humerus. If done properly, this treatment offers adequate stabilization, minimizes soft tissue injury and rapid recovery is usually anticipated. Thus having reduced the fracture, fixation with 'k' wires will maintain reduction and will allow early mobilization.

With regard to the timing of surgery, a few studies suggest that the treatment of an uncomplicated displaced supracondylar fracture can be delayed up to the next day.(3)(26) However, Ramachandran et al. (27) in their study of uncomplicated supracondylar fractures in children cautioned against delaying the surgery for the risk of development of compartment syndrome. In our study none of the patients had any neurovascular complications at presentation as well as during hospital stay and all were operated upon within twenty four hours of admission. Controversy surrounds the choice of pinning technique for displaced extension type supracondylar fractures. Presence of an intact posterior periosteum prevents rotational misalignment in type II fractures. However, type III fractures are completely displaced and are inherently unstable. Presence of medial cortex comminution which is usually seen adds to this instability further. This is the main reason put forth by the supporters of crossed pinning technique (besides the higher torsional rigidity(28)(29) of the crossed pinning construct).(9)(30)(31) However there are few studies which state that lateral pin fixation is as good as crossed pinning (32)(33)(34) besides decreasing the risk of iatrogenic ulnar nerve injury. The incidence of iatrogenic

ulnar nerve injury varies widely and depends on the type of pin insertion technique. Brauer et al. did a systematic review and found that the probability of iatrogenic nerve injury is 1.84 times higher with cross pinning technique as compared to lateral pinning.(35) However in our study, none of the patients in cross pinning group developed any iatrogenic ulnar nerve injury. Furthermore, a separate medial incision to explore the ulnar nerve for medial pin insertion is advocated. In our study only two patients with gross swelling of elbow required an incision on medial side because the swelling precluded the palpation of ulnar nerve. In rest of the patients the ulnar nerve was palpable and was pushed posteriorly with thumb before inserting the medial pin.

There is no significant difference between the two pinning techniques based on clinical outcome in our study. Our study results support the use of lateral pinning for displaced supracondylar fractures (Gartland type II & type III). The strength of this study is its prospective design, standardized protocol for reduction of fracture, pin placement, and follow up evaluation of the patients. The limitations of this study are lack of randomization regarding the pinning technique, as it was left to the operating surgeon to decide. The number of patients and relatively short follow up period further weakens this study. Nevertheless this study reinforces the conclusions of other authors(32)(33)(34) regarding the use of lateral pinning technique in displaced supracondylar fractures of humerus in children.

## References

- Rowland D. Common upper limb injuries in childhood. *Surgery (Oxford)* 2011;29(4):153–61.
- Gartland J. Management of supracondylar fractures of the humerus in children. *Surg gynocol obstet* 1959;109:145.
- Sibinski M, Sharma H, Bennet GC. Early versus delayed treatment of extension type-3 supracondylar fractures of the humerus in children. *J Bone Joint Surg {Br}* 2006;88(3):380–381.
- Culp RW, Osterman AL, Davidson RS, Skirven T BfJ. Neural Injuries Associated with Supracondylar Fractures of the Humerus in Children. *J Bone Joint Surg {Am}* 1990;72-A(8):1211–1215.
- Ramachandran M, Birch R, Eastwood DM. Clinical outcome of nerve injuries associated with supracondylar fractures of the humerus in children: the experience of a specialist referral centre. *J Bone Joint Surg {Br}* 2006;88(1):90–94.
- Blakey CM, Biant LC, Birch R. Ischaemia and the pink, pulseless hand complicating supracondylar fractures of the humerus in childhood: long-term follow-up. *J Bone Joint Surg {Br}* 2009;91(11):1487–1492.
- Griffin KJ, Walsh SR, Markar S, Tang TY, Boyle JR, Hayes PD. The pink pulseless hand: a review of the literature regarding management of vascular complications of supracondylar humeral fractures in children. *Eur J Vasc Endovasc Surg* 2008;36(6):697–702.
- Robb JE. The pink, pulseless hand after supracondylar fracture of the humerus in children. *J Bone Joint Surg {Br}* 2009 ;91(11):1410–1412.
- Zamzam MM, Bakarman KA. Treatment of displaced supracondylar humeral fractures among children: crossed versus lateral pinning. *Injury* 2009;40(6):625–30.
- Cekanauskas E, Degli?te R, Kalesinskas RJ. Treatment of supracondylar humerus fractures in children, according to Gartland classification. *Medicina (Kaunas, Lithuania)* [Internet] 2003 Jan;39(4):379–83. Available from: <http://www.ncbi.nlm.nih.gov/pubmed/12738907>
- Kocher MS, Kasser JR, Waters PM, Bae D, Snyder BD, Hresko MT, et al. Lateral entry compared with medial and lateral entry pin fixation for completely displaced supracondylar humeral fractures in children. A randomized clinical trial. *J Bone Joint Surg {Am}* 2007 ;89(4):706–712.
- Beatty, James H.; Kasser JR. *Rockwood & Wilkins' Fractures in Children*, 6th ed. Philadelphia:Lippincott Williams & Wilkins, 2006.
- Flynn C. Blind Pinning of Displaced of the Humerus Supracondylar in Children. *J Bone Joint Surg {Am}* 1974;56-A(2):263–272.
- Benjamin HJ, Hang BT. Common Acute Upper Extremity Injuries In Sports. *Clin Pediatr Emerg Med* 2007;8(1):15–30.
- Chasm RM, Swencki S a. Pediatric orthopedic emergencies. *Emerg Med Clin North Am* 2010;28(4):907–926.
- Laine JC, Kaiser SP, Diab M. High-risk pediatric orthopedic pitfalls. *Emerg Med Clin North Am* 2010 ;28(1):85–102.
- Omid R, Choi PD, Skaggs DL. Supracondylar humeral fractures in children. *J Bone Joint Surg {Am}* 2008;90(5):1121–1132.
- Sherman SC. Pediatric supracondylar fracture. *J Emerg Med* 2011 Feb;40(2):35–37.
- Parikh S, Wall E, Foad S. Displaced type II extension supracondylar humerus fractures: do they all need pinning? *J Pediatr Orthop* 2004;24(4):380–384.
- Queally JM, Paramanathan N, Walsh JC, Moran CJ, Shannon FJ, D'Souza LG. Dorgan's lateral cross-wiring of supracondylar fractures of the humerus in children: A retrospective review. *Injury* 2010;41(6):568–571.
- Memisoglu K, Kesemenli CC, Atmaca H. Does the technique of lateral cross-wiring ( Dorgan ' s technique ) reduce iatrogenic ulnar nerve injury??. *International Orthopaedics (SICOT)* 2011;35:375–378.
- El-Adl WA, El-Said MA, Boghdady GW, Al-Sayed MA. Results of treatment of displaced supracondylar humeral fractures in children by percutaneous lateral cross-wiring technique. *Strat Traum Limb Recon* 3(1):1–7. doi: 10.1007/s11751-008-0030-3
- Weinberg a M, Castellani C, Arzdorf M, Schneider E, Gasser B, Linke B. Osteosynthesis of supracondylar humerus fractures in children: a biomechanical comparison of four techniques. *Clin biomech (Bristol Avon)* 2007 Jun;22(5):502–9.
- Fahmy MAL, Hatata MZ, Al-Seesi H. Posterior intrafocal pinning for extension-type supracondylar fractures of the humerus in children. *J Bone Joint Surg {Br}* 2009;91-B(9):1232–1236.
- Li Y, Lee P, Chia WT, Lin H, Chiu F, Chen T, et al. Prospective analysis of a new minimally invasive technique for paediatric Gartland type III supracondylar fracture of the humerus. *Injury* 2009;40(12):1302–1307.
- Yeoman T, Murphy E, Malhas A, Smith J, Campbell D.

Should paediatric supracondylar fractures go to theatre out of hours if there is no neurovascular deficit? *International Journal of Surgery* 2011 Jan;9(7):547.

27. Ramachandran M, Skaggs DL, Crawford H a, Eastwood DM, Lalonde FD, Vitale MG, et al. Delaying treatment of supracondylar fractures in children: has the pendulum swung too far? *J Bone Joint Surg {Br}* 2008;90-B(9):1228–1233.

28. Lee S, Mahar A. Displaced pediatric supracondylar humerus fractures: biomechanical analysis of percutaneous pinning techniques. *J Pediatr Orthop* 2002;22(4):440–443.

29. Zions L, McKellop H. Torsional strength of pin configurations used to fix supracondylar fractures of the humerus in children. *J Bone Joint Surg {Am}* 1994;76-A(2):253–256.

30. Sial N, Yasin A, Rashid A. Supracondylar humerus fractures outcome of open reduction and percutaneous crossed pin fixation. *Professional Med J* 2011;18(1):147–153.

31. Swenson A. The treatment of supracondylar fractures of

the humerus by Kirschner-wire transfixion. *J Bone Joint Surg {Am}* 1948;30A(4):993–997.

32. Mazda K, Boggione C, Fitoussi F, Penneçot GF. Systematic pinning of displaced extension-type supracondylar fractures of the humerus in children. *J Bone Joint Surg* 2001;83(6):888–893.

33. Topping R, Blanco J, Davis T. Clinical evaluation of crossed-pin versus lateral-pin fixation in displaced supracondylar humerus fractures. *J Pediatr Orthop* 1995;15:435–439.

34. Skaggs D, Hale J, Bassett J, Kaminsky C. Operative Treatment of Supracondylar Fractures of the Humerus in Children The Consequences of Pin Placement. *J Bone Joint Surg {Am}* 2001;83-A(5):735–740.

35. Brauer C, Lee B, Bae D, Waters P, Kocher M. A systematic review of medial and lateral entry pinning versus lateral entry pinning for supracondylar fractures of the humerus. *J Pediatr Orthop* 2007;27(2):181–186.

**Author Information**

**Simerjit Singh, Dr, M.S. Orthopaedics**

Department Of Orthopaedics, Melaka Manipal Medical College, Jalan Batu Hampar

Bukit Baru, Melaka, Malaysia

simer1980@yahoo.com

**Dinker R Pai, Dr, MS (Gen Surgery), FRCS (Edin)**

Department Of Surgery, Melaka Manipal Medical College, Jalan Batu Hampar

Bukit Baru, Melaka, Malaysia

**Avneet Kaur, Dr, M.B.B.S.**

Department Of Foundation In Science, Melaka Manipal Medical College, Jalan Batu Hampar

Bukit Baru, Melaka, Malaysia

**Htoo Htoo Kyaw Soe, Dr, MPH, PhD (Public Health)**

Department Of Community Medicine, Melaka Manipal Medical College, Jalan Batu Hampar

Bukit Baru, Melaka, Malaysia