

Clonidine Withdrawal in a Neonate Due to Accidental Transdermal Patch Dislocation

A Brzenski, M Greenberg

Citation

A Brzenski, M Greenberg. *Clonidine Withdrawal in a Neonate Due to Accidental Transdermal Patch Dislocation*. The Internet Journal of Pediatrics and Neonatology. 2014 Volume 16 Number 2.

Abstract

We describe a case of acute withdrawal from the alpha-2 agonist, clonidine, following inadvertent dislodgement of a clonidine patch, in a newborn infant who was being treated for neonatal opioid abstinence syndrome (NAS). The 6-week-old baby, born to a mother on oral methadone therapy, had been given clonidine via a transdermal patch to treat NAS. Three weeks after starting clonidine, the infant was noted to be tachycardic, agitated and jittery despite no change in his medications. Examination of the infant revealed that the patch had become dislodged underneath its protective cover and re-introduction of clonidine resulted in immediate reversal of the symptoms. Care should be exercised in infants receiving clonidine by transdermal patch, with nurses documenting the integrity of the patch to prevent accidental acute withdrawal.

INTRODUCTION

Alpha-2 agonists, such as clonidine and dexmedetomidine, have been used for sedation and analgesia in the operating room and intensive care unit.⁸⁹ Clonidine, a centrally acting alpha-2 adrenergic receptor agonist,¹ is approved and marketed in the U.S. for hypertension treatment²³, epidural analgesia⁴ and attention-deficit hyperactivity disorder⁵. In addition, clonidine has also been used as an adjunct to opioid therapy for the treatment of neonatal abstinence syndrome (NAS). Clonidine attenuates the symptoms of opioid withdrawal by inhibiting central nervous system noradrenergic hyperactivity.¹³¹⁴ Acute withdrawal symptoms, such as hypertension, tachycardia and agitation, can result from the abrupt cessation of this medication.

Clonidine can be administered by enteral, intravenous, transdermal or via the epidural route. Transdermal clonidine has the advantage of a constant rate of drug delivery throughout the day leading to stable blood levels of the drug, eliminating drug troughs and resulting in fewer symptoms. The patch also lasts 7 days, and only needs to be changed once per week of therapy. The integrity of the patch can be affected by conditions of the skin and should be monitored closely while the patient is on the drug. We report the case of a newborn baby experiencing withdrawal from clonidine secondary to accidental dislodgement of the transdermal patch.

CASE REPORT

A 3.5kg male infant was born to a 28-year-old female who was prescribed methadone for the treatment of opioid dependence. She was on a methadone dose of 100 milligrams per day. Of note she was on this therapy prior to conception. Within 24 hours of delivery the baby developed symptoms of NAS and was started on methadone 0.1 milligrams per kilogram every 8hrs. After a brief period of stabilization, a methadone taper was started. The baby's course was difficult and his methadone dose was very difficult to taper. Given the baby's inability to tolerate reductions in methadone dose, he was started on oral clonidine. The infant was transitioned to transdermal Clonidine, at 100 mcg/day once his oral dose had escalated sufficiently. The patch was placed on his back and covered as instructed by the manufacturer. Tapering continued slowly but by 6 weeks of age, his methadone dose was significantly reduced. During evening rounds on the same day the patch was changed, the baby was noted to be tachycardic, diaphoretic, hypertensive and extremely agitated with a temperature of 38.5 degrees Celsius. The infant was well perfused, agitated with an undisturbed tremor. There were no rashes or visible signs of infection. An evaluation for sepsis was undertaken and the baby was started on antibiotics. Inspection of the nursing medication administration record showed the patch had been changed at 0600 that morning. Examination of the baby revealed the patch cover was intact. However, removal of the patch cover

revealed that underneath, the patch was dislodged from baby's skin, with the patch folded over itself, preventing the drug's delivery to the patient. The diagnosis of alpha-2 agonist withdrawal was entertained and the baby was given a 2-mcg/kg dose of intravenous clonidine. Within a few minutes, the baby's heart rate and blood pressure returned to baseline and he was calm and relaxed. The baby was re-started on oral clonidine of 20 mcg/kg/day, divided into every 8 hours doses. Within 24 hours the baby's methadone taper was re-started. All cultures remained negative and the antibiotics were discontinued after 48 hours. He was successfully weaned off methadone and was discharged on oral clonidine, which was weaned off over several weeks.

DISCUSSION

Clonidine is a useful adjunct for opioid withdrawal in newborn infants and adults.¹⁰¹² It can be administered via the oral, transdermal, epidural or intravenous route. We routinely use oral clonidine in conjunction with methadone for the treatment of neonatal abstinence syndrome (NAS), whether due to in-utero exposure, or exposure in the intensive care unit. Initiation of clonidine treatment is started once the baby is stabilized on methadone and is having difficulty adjusting to lower opioid levels. For convenience, we sometimes opt for the administration of the drug via a once-weekly transdermal clonidine patch. The patch allows for more consistent delivery of drug and only needs to be changed once a week. The lowest dose clonidine transdermal patch commercially available delivers 100 microgram/day via a membrane-controlled transdermal delivery system. If a lower dose is desired, it is possible to occlude a portion of the patch with a bio-occlusive membrane like 'Tegaderm' to decrease the overall dose, where the dose is proportional to the exposed area. One should, however, never cut the patch. Cutting the clonidine patch will damage the integrity of the semipermeable patch membrane, resulting in leakage of the patch's drug reservoir contents and failure of drug delivery.¹⁸ When initiating clonidine patch therapy, we usually overlap with continue oral clonidine dosing for 12-36 hours until therapeutic effects from the patch are adequate.

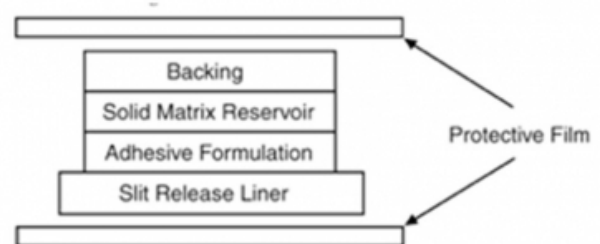
The clonidine patch delivery system is shown in figure 1. It is important to make sure the patch is placed on clean intact skin to assure patch adhesion and accurate delivery. The location of the patch should be changed weekly as the drug delivery is decreased when there is a reservoir of drug on the skin site. It has an adhesive portion that places the drug delivery membrane in contact with the skin. If the adhesive

portion loses its stickiness, a cover, which is included in the package from the manufacturer can be placed over the patch. However, this cover can make inspection of the patch, and confirmation of its integrity, difficult. Typically, the patch should be checked each shift, by the baby's nurse and recorded in the chart, to confirm continuity to the patient's skin. If the cover is used, making direct inspection of the patch impossible, one should watch clinically for signs of withdrawal. At that point removal of the cover and the patch should be immediately inspected.

Abrupt cessation of clonidine can result in a withdrawal symptoms including sympathetic hyperactivity with tachycardia, diaphoresis and hypertension. Although we looked for different sources of the symptoms, all tests, including a septic screen and an electrocardiogram, were negative. We added back the clonidine, resulting in resolution of the symptoms within minutes, confirming the diagnoses of clonidine withdrawal. While not commonly used in neonatal medicine, injectable clonidine is a potent and rapid acting alpha-2 agonist. We administered the drug slowly and in 1-mcg/kg increments to reduce the possibility of side effects. In general when using clonidine in infants, to prevent withdrawal symptoms, one should routinely taper the oral dose down slowly, with a decrease of about 20-25% per week. If a baby is receiving clonidine via a transdermal patch, we routinely switch back to the oral form divided into 3 x day doses. This will allow tapering of the dose without causing withdrawal symptoms.

In summary, we conclude, Clonidine, although an excellent adjunct medication used in treating NAS, should not be abruptly discontinued or acute withdrawal symptoms can result. When administering clonidine via transdermal patch, one should remain vigilant to prevent accidental dislodgement. If symptoms do arise, one should rule out medical disease in addition to considering administering clonidine via the oral or intravenous route, to rapidly reverse the symptoms.

Figure 1



References

1. Sica DA. Centrally acting antihypertensive agents: an update. *Journal of clinical hypertension* 2007;9(5):399-405.
2. Catapres (clonidine hydrochloride) tablet [Internet]. Bethesda (MD): National Library of Medicine (US) Daily Med; Nov 2006 [cited 2008 December 1]. Available from: <http://dailymed.nlm.nih.gov/dailymed/drugInfo.cfm?id=2532>
3. Catapres (clonidine) patch [Internet]. Bethesda (MD): National Library of Medicine (US) Daily Med; Apr 2006 [cited 2008 December 1]. Available from: <http://dailymed.nlm.nih.gov/dailymed/drugInfo.cfm?id=1890>
4. Duraclon (clonidine hydrochloride) injection solution [Internet]. Bethesda (MD): National Library of Medicine (US) Daily Med; Jan 2008 [cited 2008 December 1]. Available from: <http://dailymed.nlm.nih.gov/dailymed/drugInfo.cfm?id=6180>
5. Arnsten AF, Scahill L, Findling RL. alpha2-Adrenergic receptor agonists for the treatment of attention-deficit/hyperactivity disorder: emerging concepts from new data. *Journal of child and adolescent psychopharmacology* 2007;17(4):393-406.
6. Shavitt RG, Hounie AG, Rosário Campos MC, Miguel EC. Tourette's Syndrome. *The Psychiatric clinics of North America* 2006;29(2):471-86.
7. Schmidt AP, Valinetti EA, Bandeira D, Bertacchi MF, Simões CM, Auler JO. Effects of preanesthetic administration of midazolam, clonidine, or dexmedetomidine on postoperative pain and anxiety in children. *Paediatric anaesthesia* 2007;17(7):667-74.
8. Buck ML, Willson DF. Use of dexmedetomidine in the pediatric intensive care unit. *Pharmacotherapy* 2008;28(1):51-7.
9. Pohl-Schickinger A, Lemmer J, Hübler M, Alexi-Meskishvili V, Redlin M, Berger F, Stiller B. Intravenous clonidine infusion in infants after cardiovascular surgery. *Paediatric anaesthesia* 2008;18(3):217-22.
10. Hoder EL, Leckman JF, Poulsen J, Caruso KA, Ehrenkranz RA, Kleber HD, Cohen DJ. Clonidine treatment of neonatal narcotic abstinence syndrome. *Psychiatry Research* 1984;13(3):243-51.
11. Noerr B. Transdermal clonidine. *Neonatal Network* 2000;19(2):67-9.
12. Gowing L, Farrell M, Ali R, White JM. Alpha2 adrenergic agonists for the management of opioid withdrawal. *Cochrane Database of Systematic Reviews* 2004, Issue 4. Art. No.: CD002024.
13. Maldonado R. Participation of noradrenergic pathways in the expression of opiate withdrawal: biochemical and pharmacological evidence. *Neuroscience and biobehavioral reviews* 1997;21(1):91-104.
14. Geyskes GG, Boer P, Dorhout Mees EJ. Clonidine withdrawal. Mechanism and frequency of rebound hypertension. *British journal of clinical pharmacology* 1979;7(1):55-62.
15. Schmidt GR, Schuna AA. Rebound hypertension after discontinuation of transdermal clonidine. *Clinical pharmacy* 1988;7(10):772-4.
16. Finnegan LP, Connaughton JF, Kron RE, Emich JP. Neonatal abstinence syndrome: assessment and management. *Addictive diseases* 1975;2(1-2):141-58.
17. Levinson ML, Johnson CE. Stability of an extemporaneously compounded clonidine hydrochloride oral liquid. *American journal of hospital pharmacy* 1992;49(1):122-5.
18. Lee HA, Anderson PO. Giving partial doses of transdermal patches. *American journal of health-system pharmacy* 1997;54(15):1759-60.
19. Brodsky JB, Bravo JJ. Acute postoperative clonidine withdrawal syndrome. *Anesthesiology* 1976;44(6):519-20.
20. Weber MA. Discontinuation syndrome following cessation of treatment with clonidine and other antihypertensive agents. *Journal of cardiovascular pharmacology* 1980;2 Suppl 1:S73-89.
21. McDonald CA, Guttinger R, Joyce D. Case report: clonidine withdrawal after atypically high-dose maintenance treatment. *Journal of paediatrics and child health* 2005;41(11):609-10.

Author Information

Alyssa Brzenski, MD

Assistant Clinical Professor of Anesthesiology University of California San Diego
San Diego, CA, USA
abrzenski@ucsd.edu

Mark Greenberg, MD

Professor of Anesthesiology and Pediatrics University of California San Diego
San Diego, CA, USA
mgreenberg@ucsd.edu